

OFFICIAL ORGAN  
OF THE



EUROPEAN GROUP  
OF LYMPHOLOGY  
GROUPEMENT EUROPÉEN  
DE LYMPHOLOGIE

# THE EUROPEAN JOURNAL OF lymphology and related problems

VOLUME 1



NUMBER 1



MAY 1990

## S U M M A R Y

### GEL NEWSLINES

President Editorial - A. PISSAS, President of the GEL.

Foundation Editorial - P. BOURGEOIS, Editor-in-Chief.

### CLINICAL SCIENCES

#### **Original articles**

- 45 years of research on the lymphatic vessels. - M. SERVELLE.
- The physical treatment of edemas. - A. LEDUC and O. LEDUC.
- Scintigraphic study of contralateral vessels in the lymph drainage of the glabella. O. LEDUC, Ph. ALLARD, St. RESIMONT, P. BISSCHOP and M. VERHAS.

#### **Case report**

- Lymphoscintigraphic demonstration of a protein losing enteropathy. P. BOURGEOIS and F. WOLTER.

### BASIC SCIENCE

#### **Original article**

- Morphological study of the vascular regeneration processes in the case of free skin grafts : experimental approach. Y. GEYSELS, P. LIEVENS, P. BOURGEOIS and A. LEDUC.

Informations for authors.

Calendar : GEL MEETING 1990 IN MONT-GODINNE.

GEL MEETING 1990 IN COIMBRA : programma.

### THEMES FOR FORTHCOMING ISSUES

- LYMPHOLOGY AND ORTHOPAEDICS.
- UPPER AND LOWER LIMB EDEMAS : CLINICAL DATA AND TECHNICAL EVALUATIONS.
- THE SURGERY OF THE LYMPHATIC VESSELS.

WELCOME TO THE 10th ANNIVERSARY  
OF THE GROUPEMENT EUROPÉEN DE LYMPHOLOGIE,  
the GEL,  
born in 1980 at the Free University of Brussels.

I feel particularly happy today to congratulate all the members of the executive committee for the hard work they performed in our society.

I would especially be grateful to our two past presidents A. LEDUC and G. HIDDEN for the excellent organization achieving our groupement to be a regional society of International Society of Lymphology (I.S.L.) and numbering now more than 250 members.

My sincere thanks also to the vice-president I. CAPLAN and the general secretary Y. GEYSELS who enormously helped me in the administrative tasks.

But this journal would never see the daylight if our " bien aimé " treasurer P. BOURGEOIS was considering the time he spent and the hard work he displayed.

The paternity of this splendid realization entirely belongs to him.

I insist again expressing to him my sincere congratulations and my very deep thanks.

A. PISSAS  
President of GEL

membres fondateurs :

bourgeois, caplan,  
hidden, leduc,  
lievens, pflug,  
pissas, theys.

## FOUNDATION EDITORIAL

The European lymphology Group — Groupement Européen de Lymphologie — this year celebrates its second five-year period.

The large number of meetings organized in Belgium, Italy, France, Germany, England and Portugal testify to the considerable interest shown in lymphology by specialists from a wide range of backgrounds. Lymphology indeed embraces many fields of medicine : anatomy, physiology, pharmacology, internal medicine, surgery, angiology, oncology, radiology, nuclear medicine, physiotherapy and kinesitherapy. One of the topics to be discussed at the meeting of the GEL in Coimbra is " Lymphology and Orthopaedics ", while another reflects the growing interest shown by specialists from various fields in the lymphatic system.

The European Journal of Lymphology and Related Problems thus plans to provide support for the works carried out by all specialists interested in Lymphology. The magazine is also intended to serve as a meeting point for the various specialist subjects, whereby one group of researchers can learn about the contributions made by their counterparts in a different field. The magazine, it is hoped, will thus prove to be a source of mutual inspiration in basic and clinical lymphological research.

In addition to original works, review articles, etc., the journal's editorial policy will be to focus each issue or a number of issues on certain specific themes, with an in-depth look at the various aspects involved, thus providing readers with a summary of the latest developments or new areas of application and/or research. Articles on basic research and on clinical research as well as results of treatments will be published in an effort to bridge the gap between theory and everyday practice.

With Europe on the threshold of a new era, and the emergence of new borders, there could be no better time to announce the creation of the " European Journal of Lymphology and Related Problems ". The Journal aims to reach people of all languages from all nations.

The success of this journal will depend on those people — present or future — who have taken or will take an interest in lymphology, a discipline which dates back centuries and but much of which remains to be discovered in the years that lie ahead. This challenge confronting us is our challenge and one which, we hope, will be taken up by everyone who will read the journal.

---

## 45 years of research on the lymphatic vessel

Marceau SERVELLE

*Centre Chirurgial Val d'Or, 16, rue Pasteur, 92210 Saint-Cloud, France.*

### SUMMARY

Lymphography in 655 cases of lymphedema led to better understanding of the pathophysiology involved, and to the development of effective treatment. The lymphatics of the diaphragm were studied during thoracotomies. We supplemented the existing information on the anatomy and physiology of the lymphatics of the small intestine. The ligation of these intestinal lymphatics proved very useful in arteriosclerosis. We demonstrated that their congenital malformation produced a large number of varied diseases, the treatment of which was simplified. Lymphography and lymphochromy of all the intra-abdominal organs provided much information. Pulmonary and cardiac lymphatics are dilated in heart failure.

**KEY WORDS :** Lymphedema, chyloperitoneum, chylous cyst of the mesentery, protein losing enteropathy, chylothorax, chyluria, chyloirragia, chylarthrosis.

### LYMPHOGRAPHY IN LYMPHEDEMA

In december 1943, we performed the first lymphography ever done in lymphedema by puncturing a large lymphatic vessel, aspirating 1500 ml. of lymph and injecting opaque material. In the 45 years that followed, we used lymphography to study 597 lymphedema of the lower limb and genital organs and 60 lymphedema with reflux of chyle in the lymphatic of the leg (1, 2, 3, 5, 7).

In most of our lymphedema, we also performed venography after freeing the small saphenous vein behind the fibular malleolus. On november 22, 1945, in a patient with significant edema of the right lower limb without chyloirragia, we noted a large milky lymphatic vessel parallel to this vein ; we punctured the vessel, extracted 150 ml. of chyle and injected opaque material. Radiography showed an enormous deep lymphatic the size of the great saphenous vein and backflow in the lymphatic of the foot, thus demonstrating our first lymphedema with chyle reflux in the lymphatic of the leg but without chyloirragia. In June of 1948, using the same technique, we made the diagnosis of lymphedema with chyle reflux and chyloirragia associated with

a Klippel and Trenaunay syndrome in a 12 year old boy with lymphedema, with chyloirragia and lengthening of the affected limb. In 1949, we reported our first five cases of lymphedema with chyle reflux and, in the ten years that followed, we studied 10 more cases.

### Pathophysiology of lymphedema and therapeutic conclusions.

Lymphography of lymphedemas demonstrates significant distention of both the deep and superficial lymphatics, leading to loss of valvular function in the affected vessels. When the patient is erect, lymph flows back into the lymphatics of the foot and can filter into the subcutaneous tissue surrounding the distended vessels. We developed our total superficial lymphangiectomy, a resection of all the subcutaneous tissue of the limb in 2 stages, in response to this pathophysiology. Kondoleon's technique, lymphoplasties, partial resection of the subcutaneous tissue and lymphovenous anastomosis has not been successful in these cases (5, 6).

In cases of lymphedema with chyle reflux in the lymphatics of the leg, we resect the large lateroaortic lymphatic from L1 to L5 via a left subperitoneal approach, 4 hours after a fatty meal. In the second stage, we resect the laterocaval and periiliac lymphatics via a right subperitoneal approach. Following that, we perform the 2 total superficial lymphangiectomies.

### LYMPHATICS OF THE DIAPHRAGM.

On several occasions from 1962 on, pedal lymphographies in lymphedemas with chyle reflux clearly outlined the lymphatics of the diaphragm. Lymphographies of the small intestine carried out after 1967 often showed the same diaphragmatic lymphatic. During that period, in the course of left or right thoracotomies for cardiac surgery, we injected Evans blue at different points of the diaphragm. These lymphochromies demonstrated that the lymphatics of the right diaphragmatic dome are much more numerous than those of the left dome, which explains the **more frequent occurrence of right pleural effusions in heart failure**. Furthermore, Evans blue injected in the left dome, close to the pericardium, stained a large interphrenopericardial lymphatic coursing to the right to reach the lymphatics surrounding the intrapericardial section of the inferior vena cava.

The lymphatics of the diaphragm drain towards the base of the neck by means of the internal mammary lymphatics, the lymphatics along the phrenic nerve, and, more distally, through the inferior mediastinal lymphatics (4, 7, 13, 19).

*Reprint request :*

*Marceau Servelle*

*16, rue Spontini, Paris 75116, France.*

## LYMPHATICS OF THE SMALL INTESTINE

The anatomy of the lymphatics and of the lymph nodes of the small intestine and the mesentery is very well known. But this is not so in the case of the large lymphatic vessels coursing from the central group of the mesenteric lymph nodes to the cisterna chyli. ROUVIERE described an intestinal trunk skirting around the left border of the aorta, passing over the left renal vein and ending in the left lumbar lymphatic trunk ; occasionally, this intestinal lymphatic trunk passes below the left renal vein (8, 11).

Following our ligation of the intestinal lymphatic vessels in cases of arteriosclerosis, we noted that the intestinal lymphatics leave the central group of the mesenteric lymph nodes and form 3 or 4 large lymphatic trunks at the level of the upper border of the left renal vein. These **big trunks run down anterior to the left renal vein, skirt around its lower border and then course up along its posterior surface** where they join together in one lymphatic trunk leading to the cisterna chyli or to the left lumbar trunk (35).

In the dog, the anatomy of these lymphatics differs considerably. In laparotomies performed following a fatty meal, we retracted the entire small intestine to the left and exposed many large white lymphatics coursing down to the left border of the inferior vena cava where they come together into a **large intestinal lymphatic trunk** of 6 to 8 mm. in diameter. This intestinal lymphatic trunk rises **anterior to the vena cava for 6 to 7 centimeters**, then disappears between it and the lumbar aorta to join the cisterna chyli at the level of the first lumbar vertebra. This anatomic arrangement permits the insertion of one Abbocath T20 I 1/4 into the lymphatic trunk and another one into a mesenteric vein. Using a gastroduodenal catheter, we injected a solution of either glucose, total lipids, triglycerides or proteins into the duodenum. Samples of chyle and mesenteric blood were obtained hourly.

### A. Physiology of the intestinal lymphatics

The Abbocath in the intestinal trunk enabled us to register **lymphatic pressure** with a micromanometer. This is normally 6 to 7.5 mm. Hg. ; however, following an intravenous injection of Prostigmine, it is 4 times the normal value. Following the ligation of the chyliferous vessel, this pressure reaches 15 to 20 mm. Hg.

### Absorption of glucose.

Normal values are 0.95 g/l in the chyle and 0.80 g/l in the mesenteric blood. Following the injection of 200 ml. of a 5% solution of glucose into the duodenum, samples of chyle and mesenteric blood taken hourly revealed a **greater glucose absorption by the intestinal lymphatics** than by the superior mesenteric vein.

### Absorption of total lipids and triglycerides.

These are absorbed **solely by the intestinal lymphatics**.

### Absorption of the short-chain fatty acids.

These are absorbed **twice as much by the intestinal lymphatics** as by the superior mesenteric vein (6).

### B. Ligation of the intestinal lymphatics in arteriosclerosis.

From 1964 to 1966, we observed that a significant loss of chyle (chylo-duodenal fistula, protein-losing enteropathy) led to the lowering of blood proteins, calcium, lipids and cholesterol. Conversely, in arteriosclerosis, an increase of cholesterol and lipids is common. Therefore, in 1965, in the dog, we ligated the lymphatics of the small intestine and obtained a lowering of the cholesterol and lipids. Starting in 1966, we added ligation of the lymphatics of the small bowel anterior to the left renal vein to the arterial surgery of arteriosclerotic patients. In the past 22 years, we have performed this metabolic surgery in 820 patients with very interesting results. In 1970, a 40 year old patient with a thrombosis of the iliac artery presented with the following values : cholesterol 3.2 g/l, total lipids 11 g/l, and triglycerides 2.5 g/l. We performed an iliofemoral graft with ligation of the intestinal lymphatics. Values recorded over the following 16 years revealed the lowering of cholesterol, lipids and triglycerides (Figure 1) (22).

Prior to the ligation of the intestinal lymphatics in these patients, we performed lymphographies of the small intestine. These routine lymphographies were very useful in the study of potential malformations of the lymphatics of the small intestine.

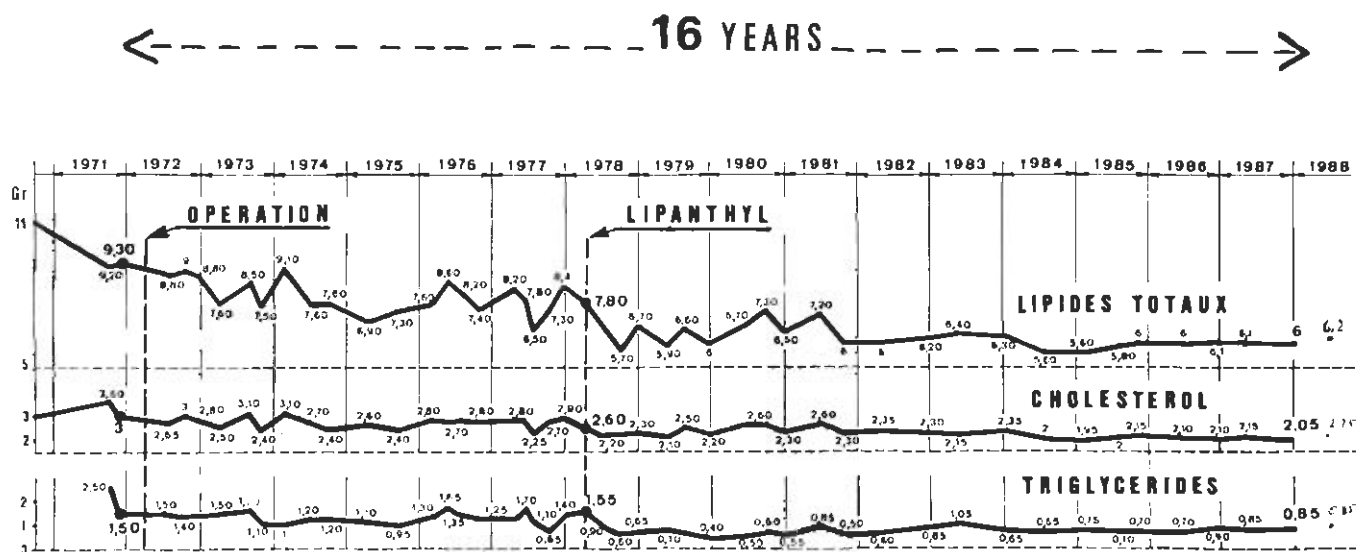


Figure 1  
Evolution of total lipids (upper curve), cholesterol (second curve)  
and triglycerides (lower curve)  
during 16 years after ligation of the lymphatics of the small bowel  
associated with an iliac arterial graft. The continuous lowering of these 3 elements  
improve the prognosis in young arteriosclerotic patients.

### C. Congenital malformation of the lymphatics of the small intestine.

During the past 20 years, we studied 300 patients with this malformation and operated on 90 of them following fatty meal and lymphography. Two abnormalities are responsible for this syndrome : 1) **an atresic cisterna chyli**, and 2) **abnormal mesenteric lymph nodes**. The result of this double blockage of the circulation of the chyle must be studied 1) in the abdominal cavity, 2) in the retroperitoneal region and lower limb, and 3) in the thorax.

#### 1) In the abdominal cavity.

Laparotomy following a fatty meal reveals very dilated and sinuous intestinal lymphatics with loss of valvular function. Localized dilatation produces a chylous cyst of the mesentery. A dilated lymphatic can rupture into the abdominal cavity (chyloperitoneum) or into the intestinal lumen (protein-losing enteropathy). Intestinal lymphography demonstrates the backflow of opaque material and the development of alternate lymphatic channels (peripancreatic, periaortic, hepatic) draining the chyle into the lymphatics of the diaphragm. The chyle can also flow back into the lymphatics of the sigmoid and of the rectum and these can rupture into the abdominal cavity (chyloperitoneum) or into the rectosigmoid (chyle loss and mesenteric lymphangitis).

#### 2. In the retroperitoneal region and lower limb.

The atresia of the cisterna chyli produces a dilatation of the 2 lymphatic lumbar trunks and their valves become non-functional. The mixture of lymph and chyle contained in the small cisterna chyli can flow retrograde towards the inguinal lymph nodes. The lymphatics of the kidney can also be overwhelmed by the chyle backflow, with rupture of a lymphatic into the renal pelvis producing **chyluria**. Finally, the chyle backflow can extend to the lymphatics of the lower limb (lymphedema with chyle backflow in the lymphatics of the leg, chylorrhea, chylarthrosis) (6).

#### 3. In the thorax.

Chyle drains through the thorax towards the base of the neck. The lymphatics of the diaphragm, when filled with chyle, become greatly distended and may rupture into the pleural cavity (chylothorax). These diaphragmatic lymphatics drain towards the cervical region via the internal mammary lymphatics, and, specifically via the inferior mediastinal lymphatics, towards the lymph nodes of the tracheal bifurcation. But these nodes already drain the lymphatics of both lungs. Due to the circulatory overload produced by the shunting of chyle, the pulmonary lymphatics cannot drain normally and they dilate, causing their valves to become non-functional. Consequently, chyle can flow back from the lymph nodes of the tracheal bifurcation into the pulmonary lymphatics. The rupture of a chyle-filled peribronchial lymphatic into the bronchial lumen produces acute pulmonary edema. The rupture of a subpleural lymphatic into the pleural cavity produces chylothorax. The chyle reflux can also invade the lymphatics of the heart (chylopericardium).

Thus, malformation of the intestinal lymphatics can produce many diseases, as indicated in the following table :

#### Diseases secondary to the malformation of the intestinal lymphatics

Protein losing enteropathy	16
Chyloperitoneum and chylous cyst of the mesentery	15
Chyluria	17
Lymphedema with chyle reflux in lymphatics of the lower limb	60
Chylothorax and chylous cyst of the mediastinum	17
Chylopericardium	9
Reflux of chyle in the pulmonary lymphatics	13
Isolated hypoproteinemia	4
Isolated food allergies	19

Other diseases are simply associated with the malformation of the lymphatics of the small intestine :

#### Diseases associated with the malformation of the intestinal lymphatics

Common lymphedema	35
Lymphedema of the genital organs	6
Milroy's disease	10
Common edema	4
Vascular complications after use of oral contraceptives	14

#### Therapeutic conclusions.

The lymphatics of the small bowel play a very important role in intestinal absorption.

Consequently, in a transplant of the small intestine, continuity of the intestinal lymphatic trunk must be reestablished as well as that of the small bowel, superior mesenteric artery and vein. In cases of chyloperitoneum, we identify and suture the responsible ruptured intestinal lymphatics. In spontaneous chylothorax we find and suture the ruptured chyle-filled lymphatics : of 17 patients, the rupture was on the diaphragm in 53%, on the mediastinum in 14% and on the lung in 13%. In cases of chyluria we severed all the lymphatics of both kidneys in 17 patients and have had no recurrences.

#### LYMPHATICS OF THE GENITAL ORGANS.

##### In the male,

lymphographies of the testicles and spermatic cord of healthy individuals show lymphatics coursing to the abdomino-aortic lymph nodes on each side of the lumbar aorta from the left renal vein to the aortic bifurcation. In cases of lymphedema of the genital organs with chyle backflow, these lymphatic vessels are greatly distended and filled with chyle. They must be resected prior to a total superficial lymphangiectomy. The lymphatics of the penis drain partly into the lymphatics of the inguinal fold and partly into the lymphatics of the spermatic cord and of the abdominal wall. If chyle backflow is present, it usually disappears following resection of the latero-aortic, latero-caval and iliac lymphatics (7).

##### In the female,

backflow of chyle in the lower third of the vagina comes from the inguinal lymph nodes but, in the upper two thirds of the vagina, the reflux originates from the lymphatics of the uterus. The lymphatics of the ovary drain into the lumbar lymph nodes. The lymphatics of the uterus flow into the iliac lymph nodes and also into the lumbar lymph nodes.

## LYMPHATICS OF THE HEART (30-34).

In 1962, during thoracotomies performed for cardiac surgery, we observed **distended lymphatics on the main pulmonary artery**. We injected Evans blue at different areas of the heart in 44 patients. **Staining of the external aspect of the left atrium** showed lymphatics coursing down to its base, then up to its superior edge and traversing its internal surface to drain into the lymphatics along the left coronary artery. In 44 cases, **injection of Evans blue on the surface of both the left and right ventricles** showed lymphatics running along the interventricular artery up to the base of the heart, then along the left coronary artery and finally to the posterior aspect of the main pulmonary artery. Injection of Evans blue on the right aspect of the right ventricle showed lymphatics coursing along the artery at the edge of the right ventricle, and finally joining the main lymphatic trunk between the aorta and the main pulmonary artery (30).

The lymphatics of the superior segment of the **right atrium** drain along the anterior aspect of the superior vena cava. The lymphatics of the inferior segment run down to the inferior vena cava and disappear behind its posterior aspect.

**In cases of very severe mitral stenosis**, the lymphatics of the right ventricle are numerous and extremely distended. The lymph can filter into the wall of this ventricle, producing edema of the myocardium. The lymph can also filter into the pericardial cavity, producing a pericardial effusion. After surgery or treatment to improve myocardial function, the lymphatic vessels are no longer distended and are able to reabsorb the pericardial effusion.

In cases of chylopericardium, a rupture occurs in a chyle-filled cardiac lymphatic, or one around the inferior vena cava and this tear must be sutured.

In 10 cases of constrictive pericarditis, pedal lymphography showed one normal thoracic duct and 2 enlarged thoracic ducts with increased lymph motion. 7 thoracic ducts did not pick up the dye (tuberculous mediastinitis).

## LYMPHATICS OF THE LUNG.

In 1962, during mitral commissurotomies, we observed a distention of the left subclavicular lymphatics in 10% of our patients. Two years later, we observed a distention of the subpleural lymphatics on the left upper lobe of the left lung. In March of 1967, we noted a very marked distention of the subpleural lymphatics at the inferior edge of the lower lobe. We were easily able to inject ultrafluid lipiodol into these large lymphatics and thus performed the **first pulmonary lymphography ever done**. We carried out 250 lymphographies of the lung during the following 20 years (23).

Prior to surgery, some cases of mitral stenosis had a history of frequent **pulmonary infections**. Palpation of the lung revealed a

hard cord and pulmonary lymphography showed an irregular and inadequately filled sclerosed lymphatic. **Pulmonary infection** must be viewed as a **pulmonary lymphangitis**.

Other patients with mitral stenosis had **pleural effusions** and during thoracotomy we observed greatly distended subpleural lymphatics. Sometimes we noted lymph oozing to the surface of the lung. **Pleural effusion is produced by oozing of the lymph of the subpleural lymphatics into the pleural cavity**.

Pulmonary lymphography also showed a distention of the peribronchial lymphatics. **The lymph can filter into the bronchial lumen** and is mixed with the air of respiration, **producing an acute pulmonary edema**.

## DISCUSSION.

Our research on the lymphatic system started with lymphography in cases of lymphedema, but spread to a wider field as we studied lymphedema with chyle reflux in the lymphatics of the lower limbs. These vessels, when chyle filled and greatly distended, are suitable for lymphography by direct puncture. The procedure is easily reproduced and injects the lumbar lymphatics and those of the kidney, the small intestine, the pancreas and the diaphragm. In 1964, the study and treatment of a chylo-duodenal fistula led to better understanding of congenital malformation of the lymphatics of the small intestine. This malformation produces a number of diseases that appear quite different but, following analysis of the lymphography, their treatment is usually simple. Pulmonary lymphography during cardiac surgery shows pulmonary lymphatics that are dilated and full of a clear lymph (subpleural and peribronchial lymphatics). The pleural effusion seen in some cardiac patients is produced by filtration of this clear lymph out of the dilated subpleural lymphatics and into the pleural cavity. Filtration of the lymph from the peribronchial lymphatics into the bronchial cavity produces an acute pulmonary edema.

When there is chyle reflux in the lymphatics of the lung, the pulmonary lymphatics become more distended and chyle filled (rupture into the pleural cavity causes chylothorax, and rupture into the bronchial lumen causes acute pulmonary edema with milky spittle).

Our study of the malformation of the intestinal lymphatics led to a simple treatment: in cases of chyloperitonium and chylothorax, we suture the rupture in the chyle filled lymphatics. In cases of chyluria, we ligate and sever all the kidney lymphatics.

In cases of transplantation of the small intestine, it is as essential to reestablish the continuity of the lymphatic trunk as that of the small bowel and the superior mesenteric artery and vein.

There remains much research to be done, including studies of the lymphatics of the thyroid gland, the adrenal gland and the pancreas.

## REFERENCES

1. SERVELLE M. — La lymphographie, moyen d'étude de la physiopathologie des grosses jambes. *Rev. Chir.*, 1944, 82 : 251-8.
2. SERVELLE M. — A propos de la lymphographie expérimentale et clinique. *J. Radiol. Electrol.*, 1944-45, 26 : 165-89.
3. SERVELLE M. — Lymphographie et éléphantiasis. *Arch. Mal. Cœur*, 1946, 39 : 409-26.
4. SERVELLE M. — La lymphangiectomie superficielle totale, traitement chirurgical de l'éléphantiasis. *Rev. Chir.*, 1947, 85 : 294-320.
5. SERVELLE M., DEYSSON J. — Reflux du chyle dans les lymphatiques jambiers. *Arch. Mal. Cœur*, 1949, 12 : 1181-7.
6. SERVELLE M., DEYSSON J. — Reflux of the intestinal chyle in the lymphatics of the leg. *Ann. Surg.*, 1951, 133 : 234-9.
7. SERVELLE M. — Pathologie vasculaire. Tome III. Pathologie lymphatique. *Masson Cie, éd. Paris*, 1975.
8. SERVELLE M. The chyloferous vessels. *Expansion scientifique française, éd. Paris*, 1981 : 131-75.
11. SERVELLE M., COUPIER J., GINESTE J. — The induced hyperlipidemia test. *J. Cardiovascu. Surg. (Torino)*, 1978, 19 : 381-8.
13. SERVELLE M., DEYSSON J. — Dix cas d'éléphantiasis avec reflux du chyle. *Arch. Fr. Pédiatr.*, 1955, 8 : 1-8.

19. SERVELLE M. — Surgical treatment of lymphedema : a report on 652 cases. *Surgery*, 1987, 101, 4 : 485-495.
22. SERVELLE M. Ligation of the chyliferous vessels in the treatment of arteriosclerosis. *International Conference on arteriosclerosis*. Ravenpress edit., 1978, 491-496.
23. SERVELLE M., SOULIÉ J., ANDRIEUX J. — Les lymphatiques du poumon cardiaque. *Gaz. Méd. de France*, 1968, 75, 31, 6365-6378.
30. SERVELLE M., ANDRIEUX J., CORNU C. — Les lymphatiques du cœur (injections peropératoires). *Arch. Mal. Cœur*, 1967, 1, 89-106.
31. SERVELLE M., BOUVRAIN Y., TRICIT R. — Lymphatic circulation in constrictive pericarditis. *Journal of cardiovascular. Surg.*, 1966, 7, 3, 182-200.
32. SERVELLE M., SOULIÉ J., TURPYN H. — Lymphographie dans les péricardites constrictives. *Cœur et Médec. Interne*, 1965, 2, 163-177.
33. SERVELLE M., SOULIÉ J., TRICOT J.F. — Les épanchements des cardiaques. *Arch. Mal. Cœur*, 1969, 8, 1119-1143.
34. SERVELLE M. — Les lymphatiques du cœur et du péricarde. *Gaz. Méd., France*, 1968, 31, 6337-6346.
35. SERVELLE M., ROUFFILANGE F., ANDRIEUX J. — Lymphographie des lymphatiques intestinaux. *Sem. Hop., Paris*, 1968, 13, 3, 881-892.

MONT-GODINNE - BELGIUM

6 OCTOBER 1990

## XIIIth Meeting of the G.E.L.

### Thema

UPPER AND LOWER LIMB EDEMAS :  
CLINICAL DATA AND TECHNICAL EVALUATIONS.

### Organizers

J.C. SCHOEVAERDTS - M. CLERIN - S. THEYS

Clinique Universitaire de Mont-Godinne

B - 5180 YVOIR

081 / 42.21.11



## Physical treatment of edema

A LEDUC\*, O. LEDUC\*\*

(\*) Service of Physical Rehabilitation, Vrije Universiteit van Brussel and Université Libre de Bruxelles.

(\*\*) Edema Treatment Center and Université Libre de Bruxelles.

### SUMMARY

Physical treatment of edema is developed according to three successive stages :

- the first one consists of the application of manual lymphatic drainage and of light pressotherapy.
- the second is started if results of the first stage are unsatisfactory. It consists to add to treatment multilayered bandages as well as specific exercises. These bandages are applied during a relatively short time and replaced thereafter by permanent restraints.
- the third stage consists of manual lymphatic drainage, light pressotherapy and permanent restraint.

For each stage of treatment, the fundamental and clinical justifications are given.

### INTRODUCTION

The physical measures applied in the physical treatment of edema are numerous. We subjected the various measures to basic experimentation in order to understand the mechanics of their action. We then tested these physical measures in a veterinary clinic before finally transferring them to human clinics.

We shall seek to describe the physical treatment of edema as we understand it today.

### PHYSICAL TREATMENT

Physical treatment is developed according to three successive stages :

#### A. The first stage of physical treatment consists of :

1. Manual lymph drainage ;
2. Light pressotherapy.

##### 1. Manual lymph drainage

Manual lymphatic drainage consists of two principal maneuvers : the pull maneuver and the resorption maneuver. We experimented with the influence of these two maneuvers during lymphoscintigraphic examinations of the lower limb in humans.

Reprints request to :

Prof. A. Leduc

Service of physical rehabilitation - Vrije Universiteit of Brussels  
Laarbeeklaan, 1090, Bruxelles, Belgique.

We are able to demonstrate the following facts (1) :

1. The pull maneuver stimulates the lymphatic collectors which evacuate the edema.
2. The resorption maneuver increases the reabsorption of proteins and enhances their evacuation.
3. The resorption maneuver is more effective since it is preceded by the pull maneuver.

From these experiments, which were performed on a large number of volunteers, we can conclude that :

- Manual lymph drainage, applied in accordance with the technique we recommend, increases both the reabsorption and the flow of proteins.

##### 2. Light pressotherapy

Light pressotherapy recommended in this first stage involves a pressure intensity of between 40 and 60 mmHg. Our investigations demonstrated that pressotherapy acts essentially on the reabsorption of liquid and that it has little if any effect on the reabsorption of proteins (2).

Nevertheless, a decrease in the volume of the limb can be detected after pneumatic pressotherapy. We therefore measured the effect of pressotherapy on venous drainage.

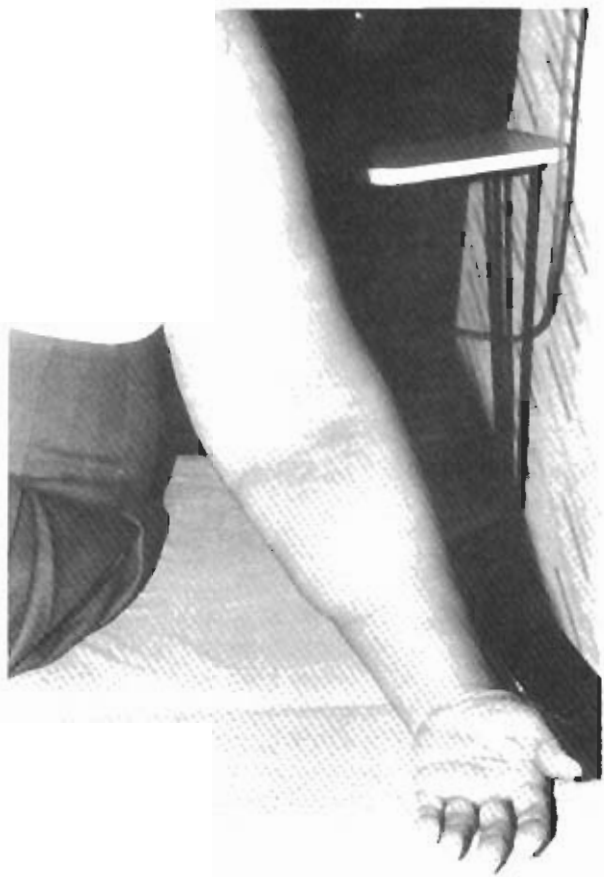Experiments were carried out on 12 patients hospitalized in a coronary care unit. A Swan-Ganz probe was inserted in the right auricle and in the pulmonary artery at the level of the pulmonary capillary (4).

In a second approach, we demonstrated that the simple application of pressotherapy pads to the two lower limbs had no effect on the following hemodynamic parameters : right auricular pressure (RAP), pulmonary artery pressure (PAP), capillary pressure (capP). Nevertheless, these parameters did increase as soon as pressure was applied to the pads. The rise in the hemodynamic parameters was maintained throughout the experiment and returned to its base value as soon as the pressure was removed (duration of the pressotherapy : 20 minutes). We can conclude from this experiment that staged pressotherapy increases venous drainage.

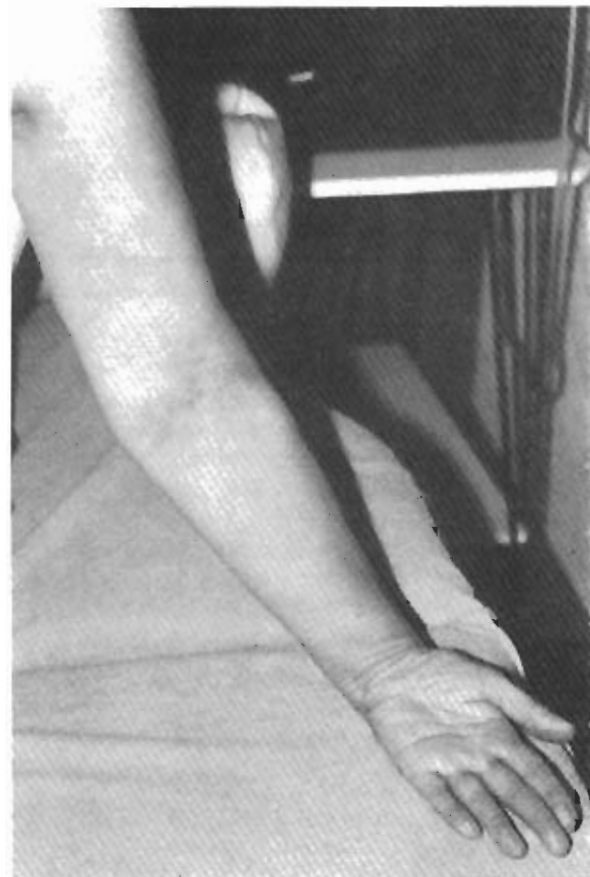From the two preceding experiments, we thus deduce that :

- The pressotherapy used in the treatment of lymphatic edema is a contraindication (because it essentially drains water).

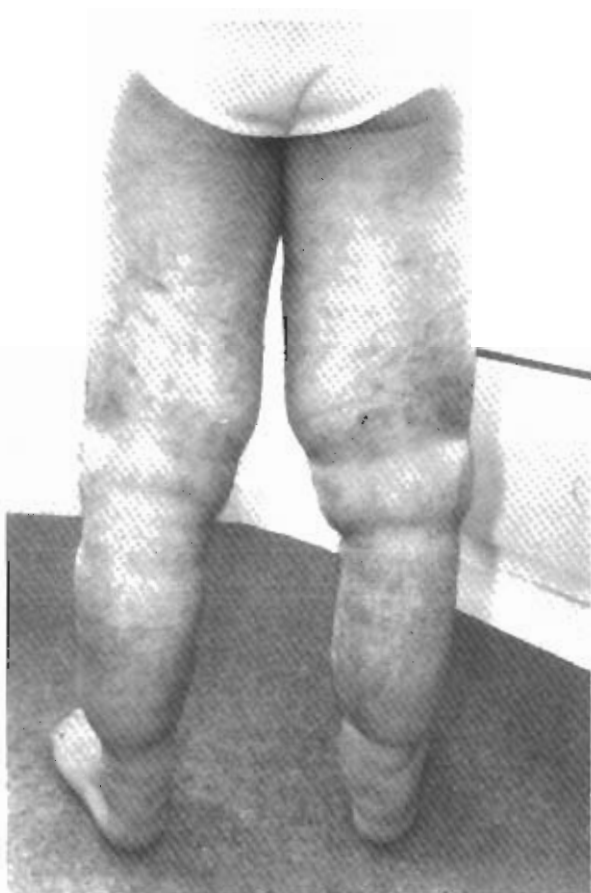We would therefore advise that manual lymph drainage be combined with pressotherapy in the first stage of physical treatment.



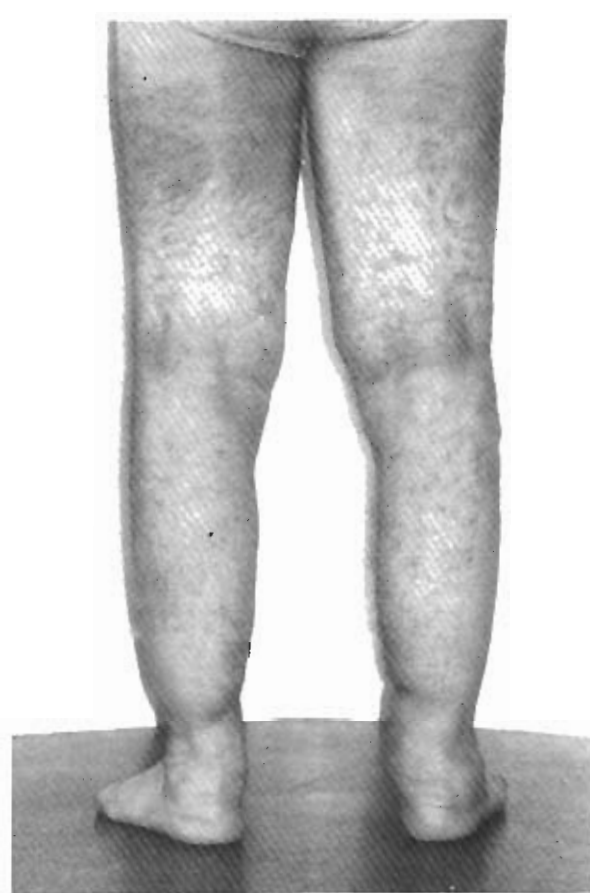*Figure 1*  
Œdème post-mastectomie le 1<sup>er</sup> jour du traitement (1988).  
Post mastectomy edema : first day of treatment (1988).



*Figure 2*  
Le 10<sup>ème</sup> jour du traitement, maintien du résultat obtenu (1990).  
The tenth day of treatment : result maintained up to now.



*Figure 3*  
Œdème après évidement inguinal, le 1<sup>er</sup> jour du traitement (1988).  
Postinguinal edema, first day of treatment (1988).



*Figure 4*  
Le 8<sup>ème</sup> jour du traitement, maintien du résultat obtenu (1990).  
The eighth day of treatment, result maintained up to now.

## B. The second stage of physical treatment consists of :

1. Manual lymph drainage.
2. Light pressotherapy.
3. Multilayered bandages.
4. Specific exercises.

The second stage in the physical treatment of edema is undertaken if the results obtained during the preceding stage have proved insufficient. We have described the role played by manual drainage and by light pressotherapy.

We are therefore especially interested in the effect of bandages and specific exercises as well as of permanent restraints.

### 1. Multilayered bandages (3)

The bandage applied around the limb must be stiff. We have studied the reactions of bandages rolled around artificial limbs as well as those applied to live patients. The multilayered bandage we recommend consists of :

1. One layer in jersey.
2. One foam bandage Thuasne N/NR or Comprex Binde Lohmann<sup>®</sup>.
3. Several low-stretch bandages superimposed.

We noted that the pressure in the artificial limb is, in this case, reflected in a quasi linear fashion.

This bandage functions like a " stiff " collar, while nevertheless permitting the patient to perform quasi normal movements. The bandage is generally well-tolerated at night. Given the good physical functioning of this multilayer bandage and its good acceptance with patients, we decided to use it systematically in the second phase of edema treatment.

### 2. Specific exercises

The specific exercises consist of contracting the muscles situated in the area of the edema in order to " stimulate " the neighboring lymphatics. We injected nanocolloids hypodermically via the inside surface of the forearm. We then had contractions of the finger and wrist flexors performed for 10 minutes against a set resistance (2/3 of IORM) at a metronome-controlled rate. We did not record any acceleration in the lymphatic flow during either the exercise or the relaxation phase which followed the physical activity. We can assert that (at the forearm level) muscular contraction does not activate lymphatic flow.

The same experiment was performed after having applied a multilayered bandage around the forearm.

Once the bandage had been applied, we recorded increased lymphatic activity during both muscular contraction and the relaxation period subsequent to the series of contractions.

We may conclude from these experiments that :

- Muscular contraction accelerates lymph drainage if a bandage is applied around the limb in advance.

### 3. Permanent restraints

Permanent restraints are often indispensable at the end of this second stage.

In fact, the limb " drained " of its edema tends to reassume its initial volume if a permanent restraint, which increases tissular pressure, is not applied.

The restraint is applied at the end of the second stage of treatment.

## C. The third stage of physical treatment consists of :

- Manual lymph drainage.
- Light pressotherapy.
- Permanent restraint.

The application of a permanent made-to-measure restraint is undertaken as soon as the treated limb has regained its normal volume. Thus the third stage begins after  $\pm 2$  or 3 weeks of " second stage " treatment.

The permanent made-to-measure restraint and the manual treatment associated with light pressotherapy constitute the essential elements here of physical treatment. This treatment diminishes progressively in frequency. Daily treatment is reduced to twice weekly and is finally given once a week.

## CONCLUSIONS

We have provided a survey of the physical measures that we use in the treatment of edema today.

We have described the different stages we recommend.

Our therapeutic approach is the culmination of numerous years of basic laboratory research and clinical experimentation. Our conclusions emphasize the advantages of non-aggressive therapeutic approaches. We are convinced that physical treatment remains the best therapeutic approach that can possibly be applied in the fight against edema.

## REFERENCES

1. LEDUC O., BOURGEOIS P., LEDUC A. — Manual lymph drainage : Scientigraphic demonstration of its efficacy on colloidal protein reabsorption. *Amsterdam Progress in Lymphology XI, Excerpta Medica*, Partsch, 1988.
2. BOURGEOIS P., BASTIN R., LEDUC A. — Lymphatic resorption of proteins and pressotherapies. *Porto, VIth Congrès du Groupement Européen de Lymphologie*, 1985.
3. DE MEYER, KLEIN P., VANDEPUT D., LEDUC A., DESMARET P. — Etude comparative du comportement de bandes élastiques et non-élastiques utilisées dans le traitement de l'œdème. *Ann. de Kinésithérapie*, 15, 1988.
4. DEREPE H., HOYLAERT M., LEDUC O., RENARD M., BERNARD A., LEDUC A. — Pressotherapy in coronary care unit : A safe treatment for patients with cardiac disease ? *Congrès Brit. Lymph. Interest Group XIV*, Oct. 1988.

## Scintigraphic study of contralateral vessels in the lymph drainage of the glabella

O. LEDUC\*, Ph. ALLARD\*\*, St. RESIMONT\*\*\*, P. BISSCHOP\*\*\*\*, M. VERHAS\*\*\*\*\*

(\*) Edema treatment Center, Assistant lecturer, Université Libre de Bruxelles.

(\*\*) Kinesitherapist, Liège.

(\*\*\*) Service of Oto-Rhino-Laryngology, University Hospital Erasmus.

(\*\*\*\*) Service of Oto-Rhino-Laryngology, University Hospital Brugmann.

(\*\*\*\*\*) Service of Nuclear Medicine, University Hospital Brugmann.

### SUMMARY

Lymphatic pathways of drainage of the glabella have been studied by lymphoscintigraphic techniques in ten human volunteers. Contralateral drainage has been found in four cases.

Efficacy of manual lymphatic drainage in a patient with edema of one cheek after a Caldwell-Luc operation is demonstrated.

The importance of the contralateral lymphatic pathways of drainage is thus stressed with regard to the problem of the manual lymphatic drainage treatment of patients with edema affecting the face.

### INTRODUCTION

ROUVIERE (1), CAPLAN (2) and LEDUC (3) have described facial lymphatics in cadaveric studies. Nevertheless, the authors are not in agreement as to the existence of contralateral lymph drainage in the area of the glabella. For this reason, we began by studying the drainage of the glabella using lymphoscintigraphy after a left lateral injection.

In a second stage, we studied the drainage of the glabella in a patient with a minor case of facial edema. In this same patient, we verified the effects of manual lymph drainage. In a third study, we investigated the nasal fossae (middle and lower turbinates) and verified the effect of manual lymph drainage maneuvers on the different sites.

In this summary, we shall confine ourselves to a description of the results obtained after injections in the glabella.

### MATERIAL AND METHODS

Three hundreds microcuries (in 0.2 ml) of <sup>99m</sup>Tc labelled nano-sized (95 % of the particles are less than 80 nanometers in size) Human Serum Albumine colloids (Nanocoll<sup>®</sup>, Solco Basle, Switzerland) were injected subcutaneously at the level of the left glabella of ten normal healthy volunteers, 9 men and 1 woman, between the ages of 21 and 31. None of the subjects exhibited an affection in the ENT region. The technique was also applied concurrent with a Caldwell-Luc operation on one patient exhibiting facial edema.

Reprints request to :

O. Leduc

Edema Treatment Center

26, Avenue des 10 Arpents, 1200-Brussels, Belgique.

After injection, the subjects lay in a relaxed position on their backs for 60 minutes, their heads beneath the gamma camera. Continuous recording was made of the evolution in radioactivity for facial views. Profile views were recorded at the beginning and at the end of the investigation.

The markers (+) were setted on the scintigraphic images in order to pinpoint with precision the ganglionic zones. Three negatives were made simultaneously at different shutter apertures (Fig. 1B, 2B, 3B, 4B, 5B, 6B : apertures : medium, minimal, maximal).

### RESULTS

Table I compiles the observations obtained from the left glabella injections among the 10 subjects.

We noted that in all cases the left ganglionic parotid zone was infiltrated by the imaging agent (via a lymphatic vessel bordering the eyebrow fold, vbsp, see also fig. 8).

The left submandibular ganglionic zone was visualised in 8 of the investigated cases (three of which via a lymphatic vessel bordering on the cheek, vnsm, see also fig. 7).

The right parotid nodes could be observed in two cases and the right submandibular ones in three subjects (the labelling of these last nodes was carried out via the vnsm lymphatic pathway).

### Illustration of the scintigraphic results obtained from healthy subjects

Figure 1A represents a graphic illustration of what is observed using lymphoscintigraphy on figure 1B (facial view).

Figure 1B shows, at 3 different sensitivities of the gamma camera, both the lymphatic vessel passing via the eyebrow fold (vbsp) contralateral to the injection and the vessel running the length of the nose (vnsm) on the injected side.

Figure 2B depicts the vbsp, homolateral and contralateral to the injection, as well as the vnsm on the injected side.

Figure 3A is a graphic illustration of what is observed using lymphoscintigraphic on figure 5B (profile view).

Figure 3B shows a lymphatic vessel running via the eyebrow fold contralateral to the injection. This vessel supplies the ganglionic parotid site (vsbp).

Also shown are the ganglionic submandibular sector (1 single ganglion) and the above-mentioned vessel (1 ganglion).

Also to be noted is the depiction of one genial ganglion on the evacuation channel emptying into the submandibular duct (vnsm).

Figure 4B illustrates the vnsm on the side of the injection. This vessel leaves the injected region via the confines of the cheek and nose in order to infiltrate the submaxillary and submandibular ganglionic ducts. One parotid (preauricular) ganglion is also shown along with two ganglia of the lower parotid sector.

#### Illustration of the scintigraphic results obtained from one patient exhibiting edema of the left cheek

The profile in negative 5B indicates that, 60 minutes after injection, the nanocolloid had not yet migrated.

During a different investigation, we carried out 10 minutes of manual lymph drainage on this same patient after an injection to the left of the glabella (fig.6).

In figure 6B, we can perceive activity in the parotid and submaxillary ganglionic zones 60 minutes after injection. Several ganglia are saturated in the preauricular and maxillary sectors.

## DISCUSSION

M. A. EBERBACH uses lymphoscintigraphy in order to guide surgical operations in cases of melanoma of the head, neck and upper part of the thorax (4).

In the present study, we were able to highlight by lymphoscintigraphic techniques the contralateral lymphatic transfer of the labelled colloids in four of our ten subjects after injection in the left of the glabella. These results confirm the cadaveric observations of A. LEDUC (3, see also figures 7 and 8) who demonstrated two lymphatic pathways of drainage for the glabella, one bordering on the cheek and emptying into the submandibular duct (vnsm, see fig. 7) and another one extending along the eyebrow fold and supplying a ganglionic parotid duct (vsbp, see fig 8).

For kinesitherapists, our demonstration of the existence of contralateral vessels in live patients confirms the technique of manual lymph drainage proposed by LEDUC (3), who advocates manual bilateral drainage during unilateral treatment of facial edema.

We have also demonstrated the efficacy of lymph drainage in one patient exhibiting discrete edema of the left cheek after a Caldwell-Luc operation.

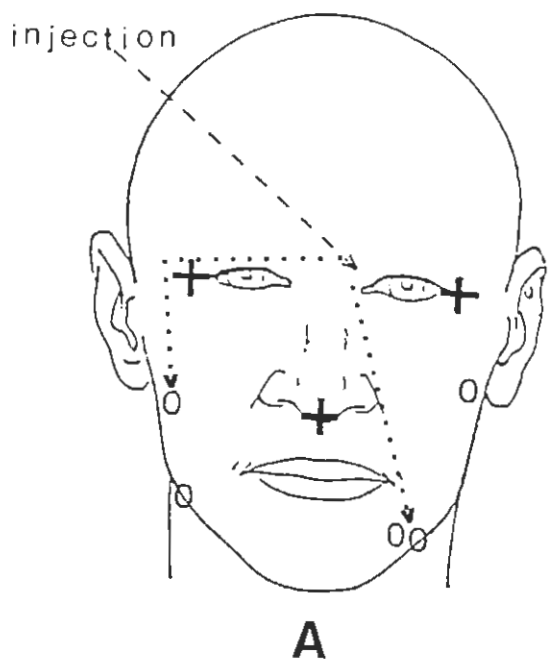
## BIBLIOGRAPHIE

1. H. ROUVIERE — Anatomie des lymphatiques de l'homme. Masson Ed., 1981.
2. I. CAPLAN — Estudio e investigacion de los linfaticos controlaterales de labio inferior. *Publicaciones, Revista de la Sociedad Rioplatense de Anatomia*, 1971/2, N° 4, pag. 44.
3. A. LEDUC — Drainage lymphatique. Théorie et pratique. *Monographies de l'Ecole de Cadres de Kinésithérapie de Bois Larris*, Masson Ed., 1978.
4. M.A. EBERBACH, R.L. WAHL, L.C. ARGENTA, J. FROELICH, J. NIEDERHUBER — Utility of lymphoscintigraphy in directing surgical therapy for melanomas of the head, neck and upper thorax. Original communications in *Surgery*, vol. 102, n° 3, sept. 1987.

Table 1

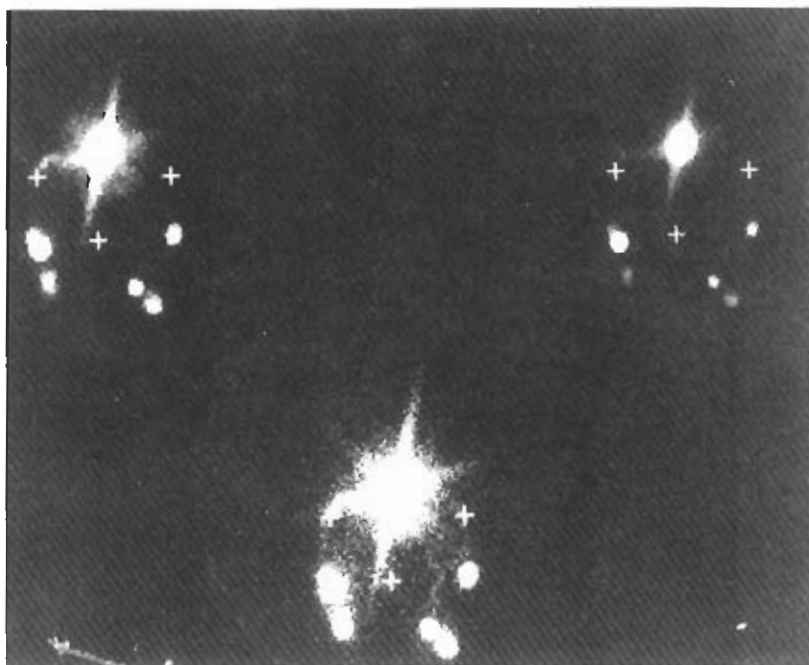
Visualised nodes after injection of the left glabella  
vnsm = lymphatic vessel running the length of the nose.  
vsbp = lymphatic vessel bordering the eyebrow in the direction of the parotid lymph node.

Case	Visualized nodes			
	Ipsilateral		Controlateral	
	Pre-auricular	Sub-maxillar	Pre-auricular	Sub-maxillar
1	×	×		vnsm
2	×	×	vsbp	vnsm
3	×	×		
4	×	×		vnsm
5	×	×	vsbp	
6	×	×		vnsm
7	×			
8	×	×		
9	×	×		
10	×			
	10	8 (3 / vnsm)	2 vsbp	3 / vnsm



A

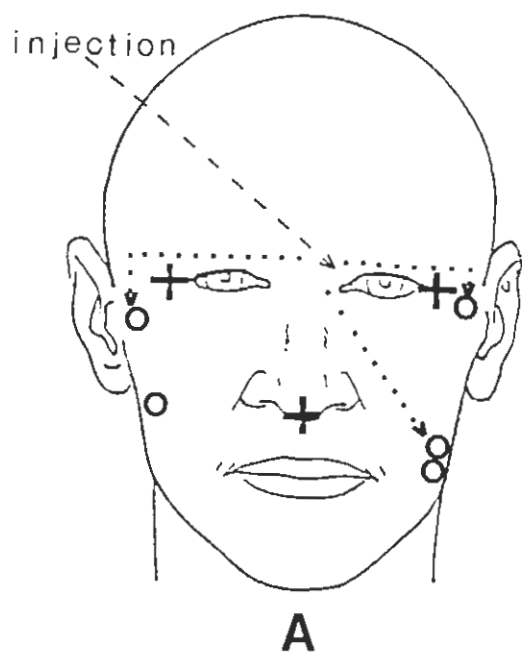
.....> voies de drainage  
 + repères  
 O ganglions



B

Fig. 1B

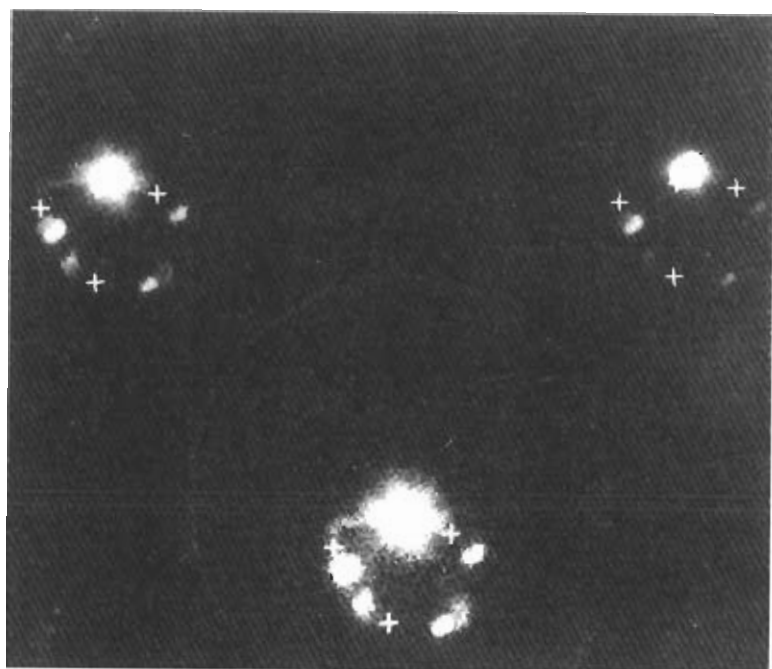
Scintigraphic image with three different sensitivities of :  
 — vnsn = drainage vessel homolateral to the injection.  
 — vbsp = drainage vessel contralateral to the injection.



A

.....> voies de drainage  
 + repères  
 O ganglions

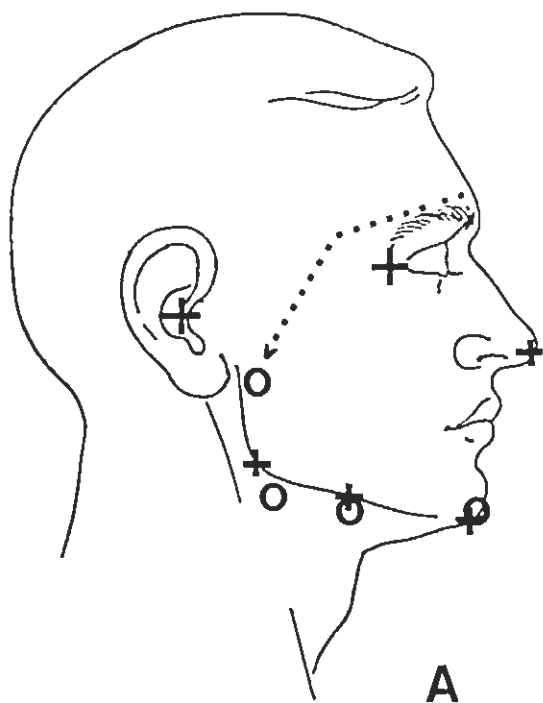
VUE DE FACE: INJECTION GLABELLE GAUCHE



B

Fig. 2B

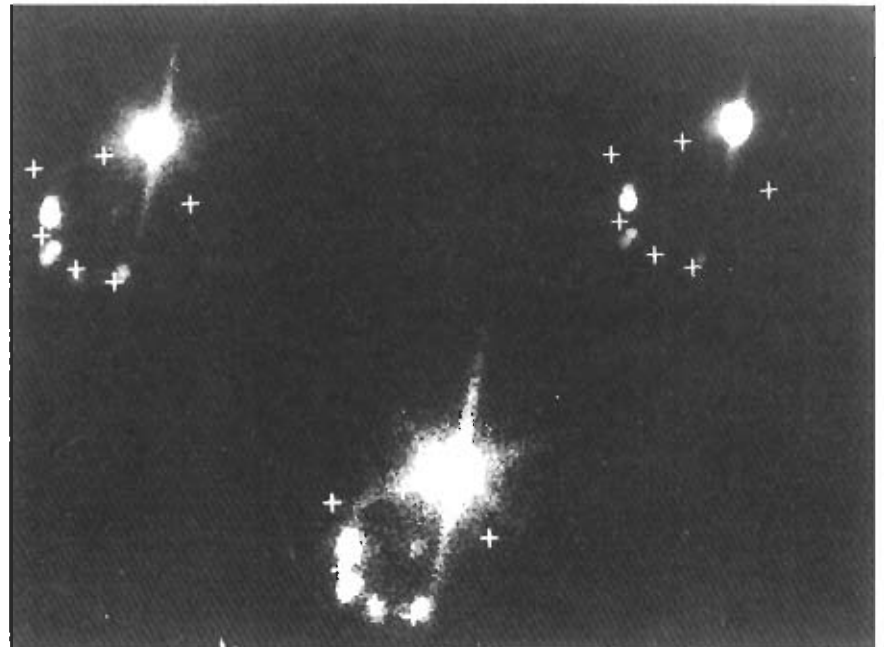Scintigraphic image with 3 different sensitivities of :  
 — vnsn = homolateral to the injection.  
 — vbsp = homolateral and contralateral to the injection.



.....> voies de drainage

+ repères

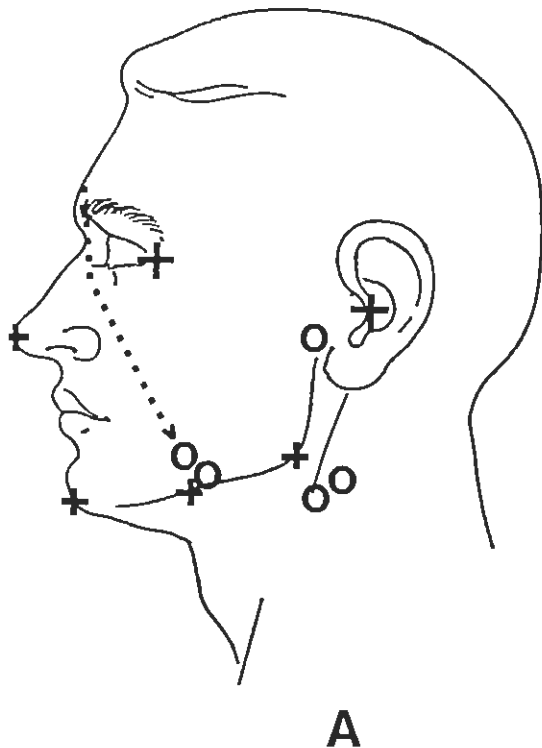
O ganglions



**B**

Fig. 3B

Scintigraphic image with 3 different sensitivities of :  
vbsp = contralateral to the injection.

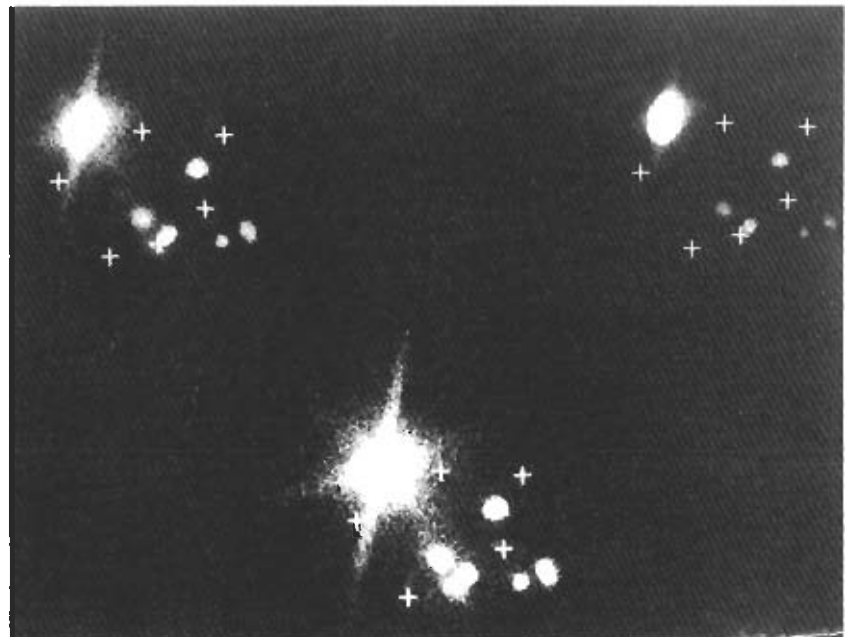


.....> voies de drainage

+ repères

O ganglions

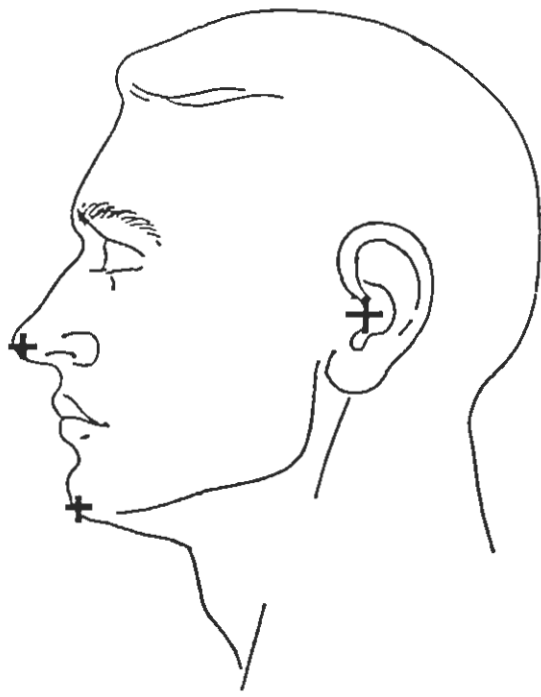
VUE DE PROFIL GAUCHE: INJECTION GLABELLE GAUCHE



**B**

Fig. 4B

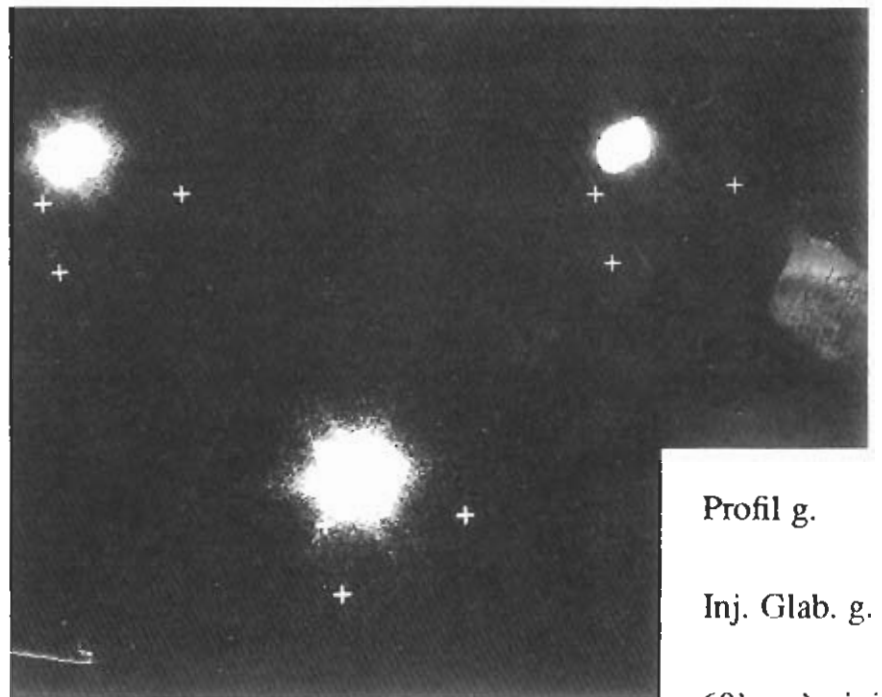
Scintigraphic image with 3 different sensitivities of :  
vnsm = homolateral to the injection.



**A**



repères



Profil g.

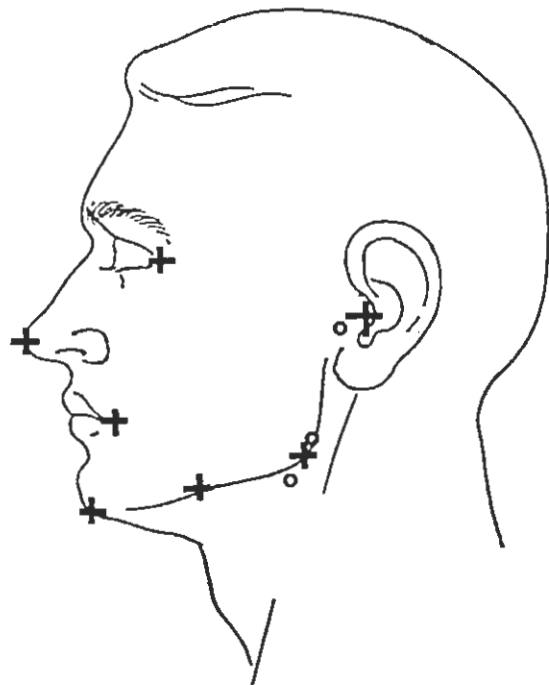
Inj. Glab. g.

60' après inj.

**B**

*Fig. 5B*

*Scintigraphic image of the stagnation of the injected medium in one patient exhibiting discrete edema of the left facial hemisphere.*



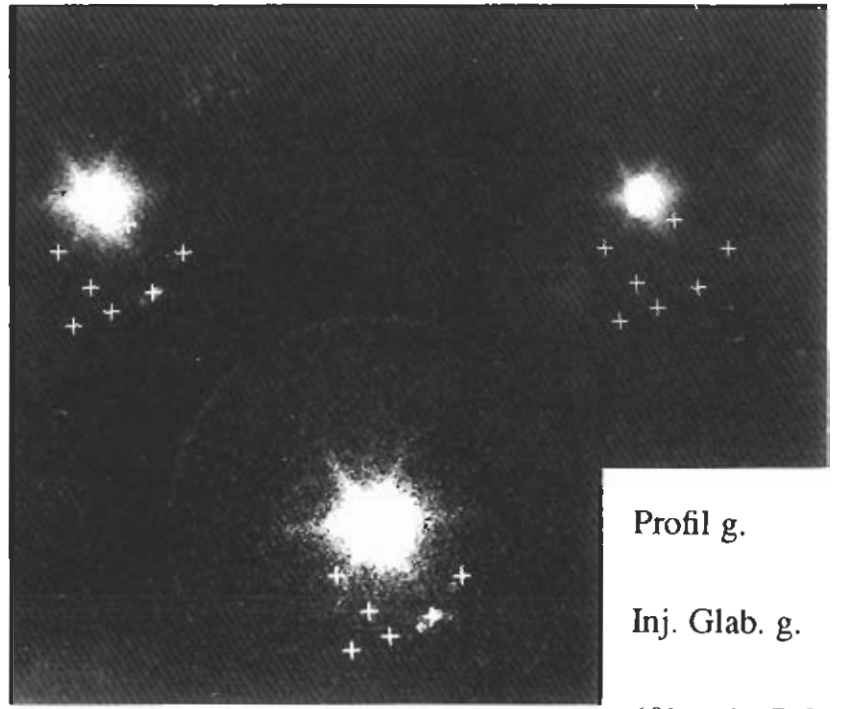
**A**



repères



ganglions



Profil g.

Inj. Glab. g.

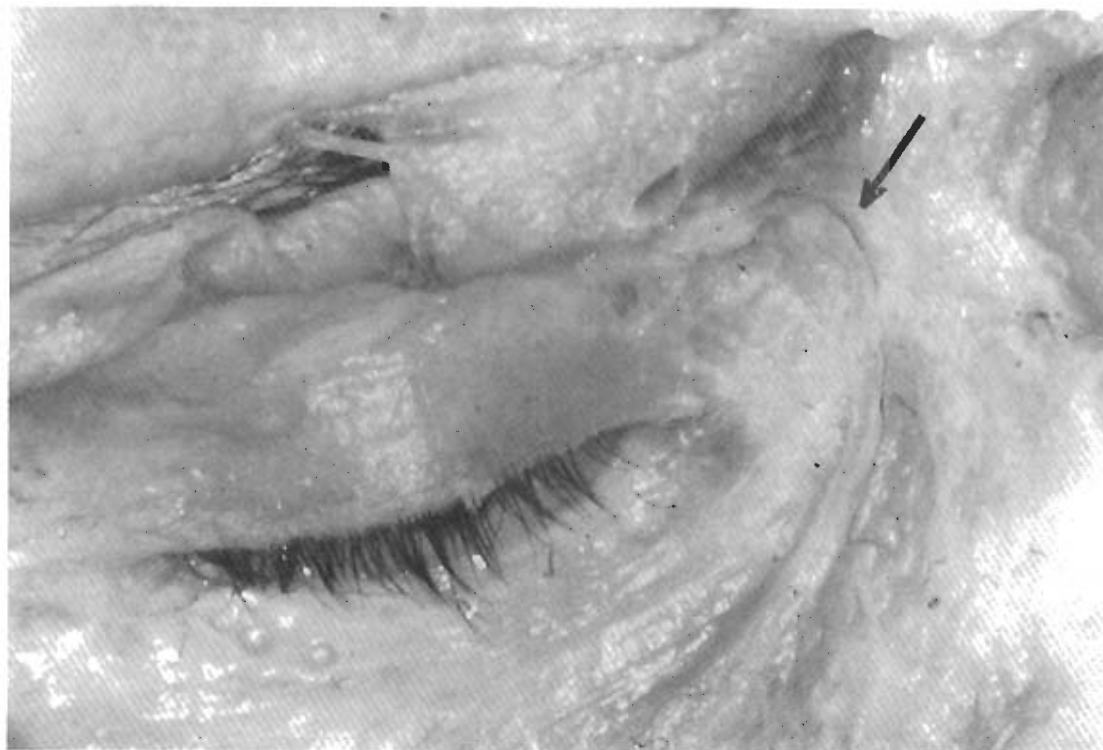60' après D.L.M.

**B**

*Fig. 6B*

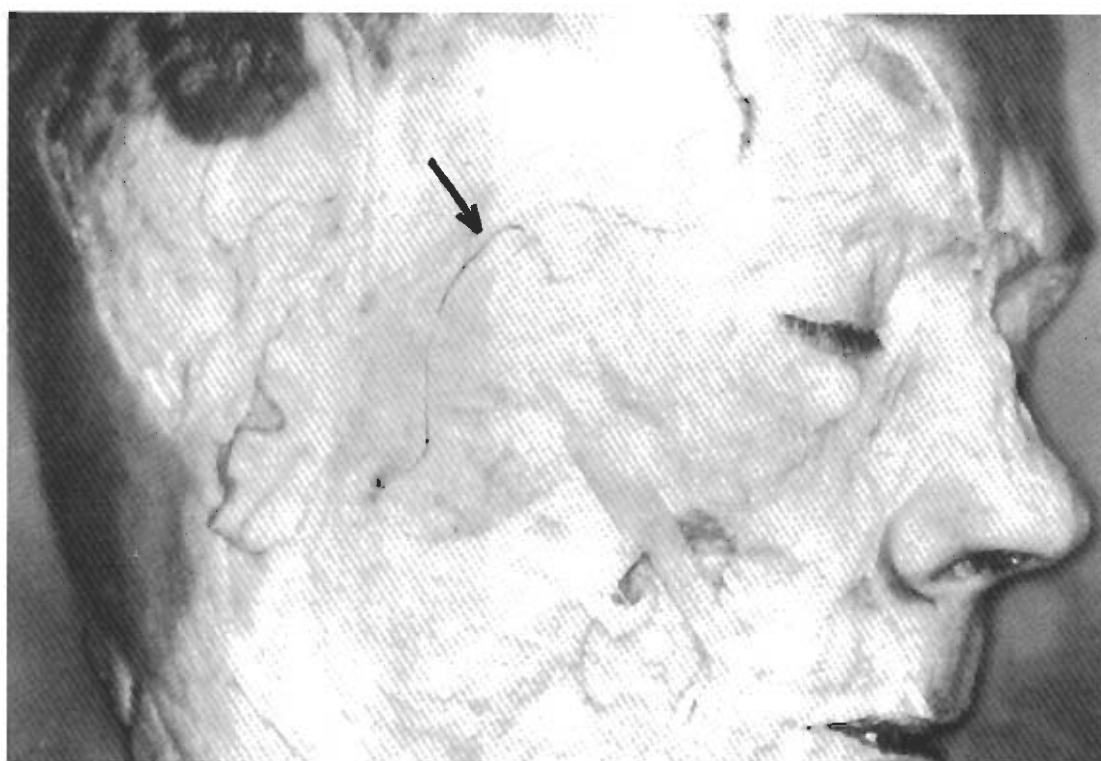*Scintigraphic image illustrating the migration of the colloids following manual lymph drainage in one patient exhibiting discrete edema of the left facial hemisphere.*





*Fig. 7*

*Lymphatic vessel running the length of the nose, vnsn appearing after injection of the glabella.*




*Fig. 8*

*Lymphatic vessel bordering the eyebrow fold in the direction of the parotid ganglionic duct (vbsp).*

# LA PRESSOTHÉRAPIE AU MERCURE

*Méthode Cartier*



- LYMPHOEDÈMES
- ULCÈRES REBELLES
- HYPODERMITES
- SÉQUELLES  
DE PHLÉBITES
- PATHOLOGIE  
POST-TRAUMATIQUE

## GRADIENT 1000

*Méthode Cartier*

- Gradient de Pression évacuateur important.
- Moulage atraumatique régulier des membres supérieurs et inférieurs (hypodermite et ulcères).
- Technique fiable et rapide, donnant de 75 à 85 % de bons et très bons résultats selon la pathologie.

**H.G. MEDICAL**

65, AVENUE DE LA CHATRE - 36000 CHATEAUROUX

**Tél. 54.34.24.00**

## Lympho-scintigraphic demonstration of a protein losing enteropathy

P. BOURGEOIS\*, M.D., and F. WOLTER\*\*, MD.

(\*) *Laboratoire des radioisotopes, Service de Radiothérapie (prof. J. Henry),  
Institut J. Bordet,  
and*

(\*\*) *Service de Pédiatrie, Hôpital Saint-Pierre, Free University of Brussels, Brussels, Belgium.*

### SUMMARY

A case of chylangioma with lympho-duodenal fistula responsible of a severe protein losing enteropathy and first demonstrated by radionuclide bipedal lymphangiography is reported.

The observation and the interest of the technic in the diagnosis of protein losing enteropathy are discussed.

**KEY WORDS :** Protein Losing Enteropathy,  
Bipedal Radionuclide Lymphangiography.

### INTRODUCTION

Intestinal lymphangioma also called chylangioma is a rare cause of Protein Losing Enteropathy (1). However since a long time described (2), only few cases have been reported in the literature (1, 3 - 10).

Diagnosis is usually based upon demonstration of intestinal loss of protein by the RISA or chromium test and visualization of intestinal megalymphatics by laparotomy (1, 11, 12). More rarely, direct loss of lymph into the digestive tract has been demonstrated by X-Ray lymphangiography (3, 5 - 7, 9).

We report here a case of intestinal lymphangioma for the first time demonstrated by radionuclide lymphangiography as a fistula from the lymphatic system to the digestive tract.

### CASE REPORT

M.N. was admitted to the hospital at the age of 12 years for edema of recent appearance.

General physical examination was normal except for fluctuating edema of the face and of the lower limbs. The serum total protein was 4,1 g/dl with a normal electrophoretic pattern. Other laboratory findings were normal. There was no albuminuria. The

diagnosis of Protein-Losing-Enteropathy was suggested on the basis of decreased biological half-life and increased excretion of radiolabelled serumalbumin. Barium study of the bowel and jejunal biopsy were normal. Pedal X-Ray lymphography showed a dilated network of lymph vessels in the upper abdomen. The thoracic duct was visualized. On laparotomy, the pancreas and duodenum were covered with distended lymph vessels which were resected and ligated. Transitory improvement of serum proteins was observed after operation.

With two successive operations (anastomosis of lymph nodes sections to three different abdominal veins) and adequate diet, the patient was maintained in relatively satisfactory conditions until the age of 20 years and despite two episodes of intestinal obstruction treated by aspirations at 18 and 19 years of age.

At 20 years of age, she started to have hypocalcemic tetany. Hypoproteinemia with edema persisted. Supplements of calcium and vitamin D were given.

Two years later, the clinical and biological status worsened progressively. The patient was hospitalized for general edema and tetany. The serum total protein was 2,9 g/dl with 1,3 g/dl of albumin. Serum calcium was 4,4 mg/dl and serum magnesium 0,94 mg/dl. Continuous gastric feeding with high protein and low fat diet supplemented with calcium, magnesium and vitamins brought some improvement. Laboratory findings were normal except for constant hypoproteinemia, hypocalcemia, hypomagnesia and lymphopenia. Barium study showed a dilated duodenum and edema of the intestinal mucosa. Computed tomography of the pancreas was normal.

Radionuclide bipedal lymphangiography with study of the elimination of the marker at the sites of injection was then performed in order to exclude a lymph node or lymph vessel pathology. Marker's elimination at the sites of injection was normal and abdominal lymph nodes were normally visualized. But the investigation showed (fig. 1) six hours after injection an unexpected accumulation of the marker in the colon. A direct loss of lymph into the digestive tract was then suspected and a second radionuclide lymphangiography performed in order to precise the level of the fistula. The investigation evidenced a chylous reflux in the epigastric region and a loss of lymph into the digestive tract in the same region (fig. 2). Later, accumulation of the

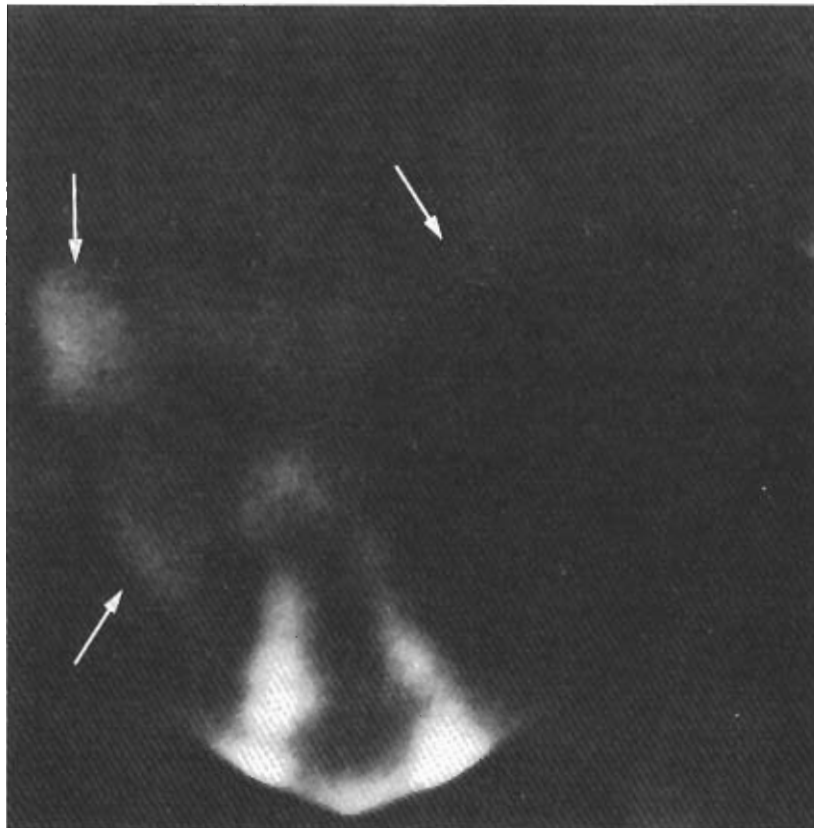
Reprints request to :

D<sup>R</sup> P. Bourgeois

Present address : Service de Médecine Nucléaire

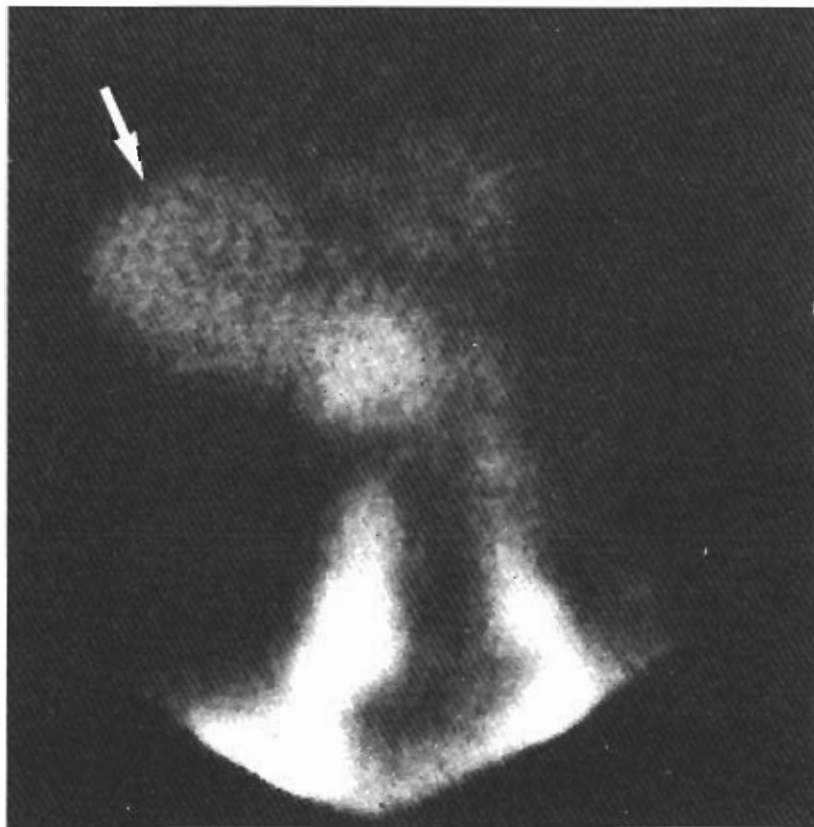
Hôpital Universitaire Saint-Pierre

322, Rue Haute, 1000, Bruxelles, Belgique.



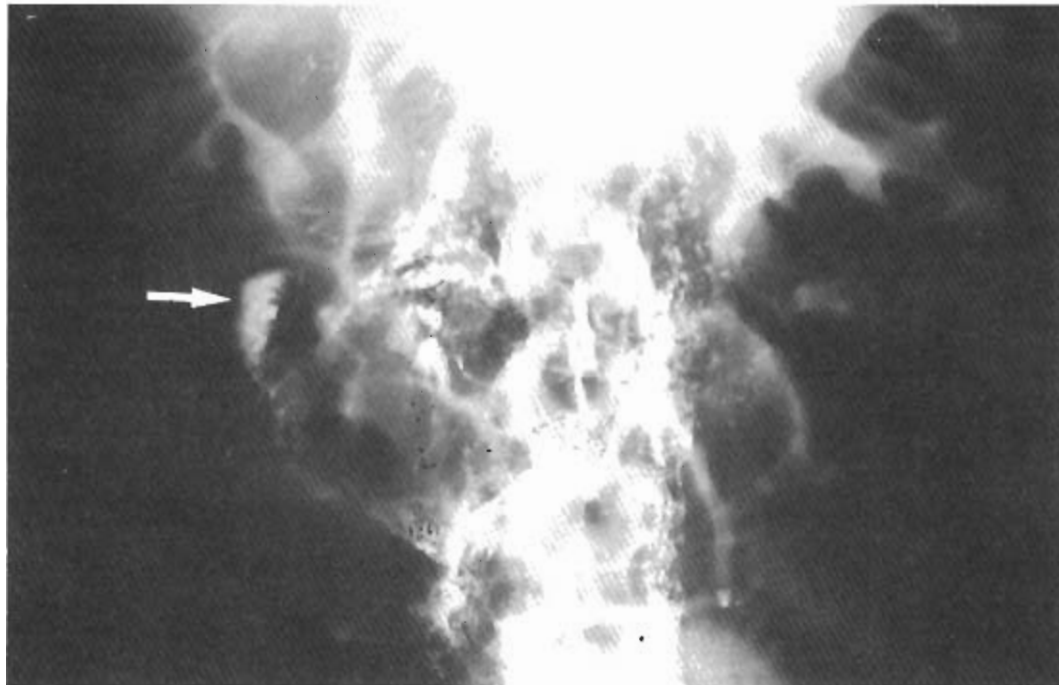*Figure 1*

*Picture centered on the abdomen (anterior view), realized 6 hours after injection at the time of the first radionuclide bipedal lymphangiography. Visualization of the iliac and lumboaortic nodes but also of activity in the right and transverse colon (arrows).*



*Figure 2*

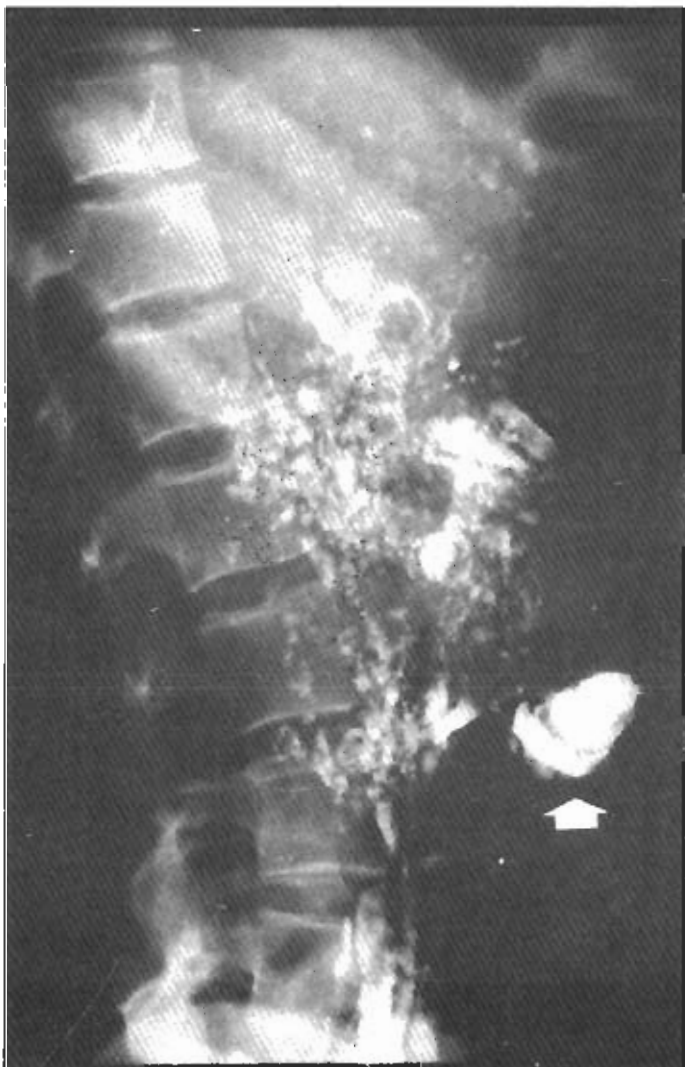*Same view as in fig. 1 but realized at the time of a second (control) lymphoscintigram and twenty minutes after the radiolabelled molecules had reached the lumboaortic nodes. Visualization of non nodal activity (before the lymph nodes in lateral view) in the epigastric region (arrow).*



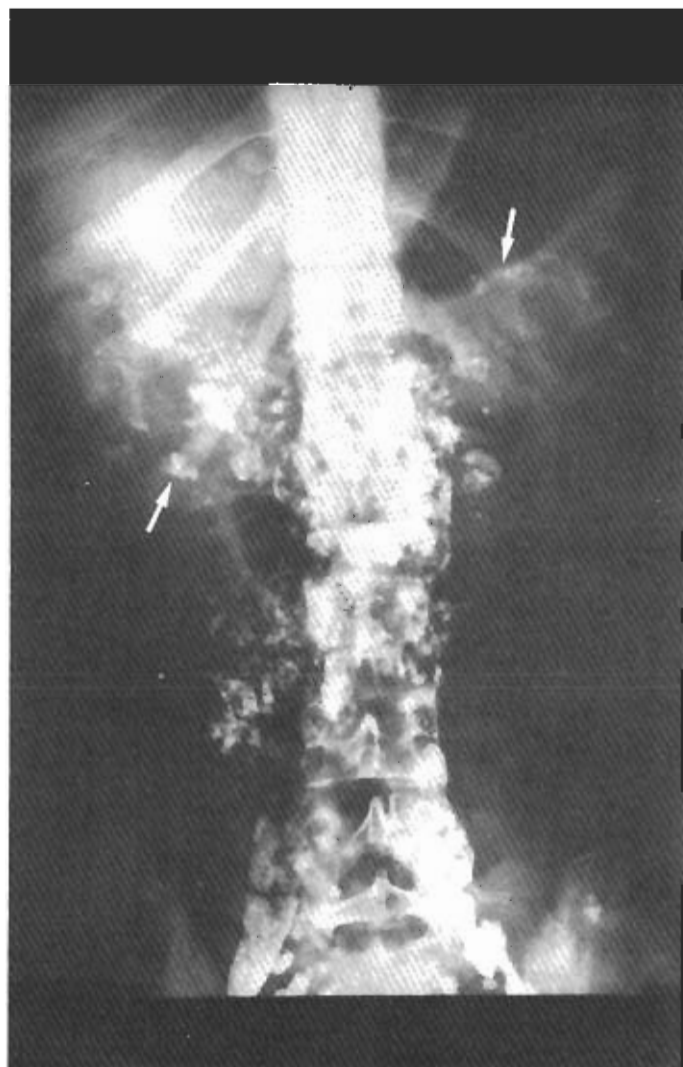
**a**

**Figure 3**  
*Control X-Ray lymphangiogram*  
*a and b pictures centered on the epigastric region.*  
*a) Anterior view.*  
*Visualization of radioopaque material in the epigastric region (pancreas) signing the chylous reflux and (arrow) in the 2nd part of the duodenum.*  
*b) Lateral view.*  
*Radioopaque material is clearly prenodal and has already progressed in the digestive tract (arrow).*  
*c) Pictures centered on the abdomen 6 hours later.*  
*The radioopaque material can be visualized in the transverse colon (arrows).*

**b**



**c**



marker could be observed in the colon after having transited in all the digestive tract.

Endoscopic retrograde cholangio-wirsungography (CWR) was normal. Duodenoscopy, although demonstrating presence of lymph in the duodenum, failed to visualize any lesion of the duodenal wall. X-Ray lymphography confirmed the chylous reflux (fig. 3) and the localized lymph loss in the duodenum (fig. 3).

On laparotomy, a chyliangioma was found in the right upper abdomen, extending from behind the duodenum to the right lumbar region and below the liver. Megalymphatics were clipped and divided and the lymphoduodenal fistula was closed through duodenotomy. Post-operative course was favorable with increase of serum proteins and calcium.

## DISCUSSION

Lymphoscintigraphy in comparison with other techniques is a simple and non traumatic method in order to investigate the morphology and functional aspects of the lymphatic system (13 - 15).

In case of bipedal radionuclide lymphangiography, after subcutaneous injections in the feet, the radiolabelled microcolloid migrates upwards through the lymph vessels of the limbs, is trapped by the successive lymph nodes it encounters and which are by this way visualized (13).

Liver and spleen visualization is a frequent and normal finding because the radiocolloid that has bypassed the lymph nodes and reached the systemic circulation is cleared by the elements of the Reticulo-Endothelial System. Kidney or bladder visualization are due to accumulation of free  $^{99m}\text{TcO}_4^-$  or of isotope secondary released by the reticulo-endothelial cells.

Three facts seemed to suggest that the intestinal activity observed did not correspond in this case to free pertechnetate (controlled by chromatography in the preparation and inferior to 5 % of the total activity injected) but well to true colloidal i.e. lymphatic originary activity :

- the very weak return of lymph and colloid to the systemic circulation as suggested by the absence of net visualization of the liver.
- the absence of thyroid imaging at the time of each investigation (considering the avidity of this organ to  $\text{TcO}_4^-$ ).
- the absence of measurable  $\text{TcO}_4^-$  activity in aliquots of gastric juice taken at the same time of one investigation and the absence of gastric imaging.

The only possible explanation to our observations was the direct loss of lymph into the digestive tract, more precisely as suggested by the pictures in the pancreaticoduodenal region. A fistula between the Wirsung and a lymph vessel, as reported in a case of protein losing enteropathy had been excluded by a C.W.R. Loss of lymph at the level of the duodenum was then confirmed by X-Ray lymphography and peroperatively.

The main contribution of the radionuclide technic was here the clear demonstration and localisation of the fistula.

For the following reasons, especially in pediatric patients, this method can be recommended owing to its advantages over its radiological counterpart :

1. The radiocolloid is injected subcutaneously without discomfort to the patient and the technic does not require blue patent injection, skin excision and lymphatic cannulation.
2. Patients can be studied without anaesthesia : general anaesthesia appears to be a need in one case upon five in Gasquet' series (16).
3. The presence of edema adds no difficulty to the procedure.
4. There is no complication from the study. In the case here reported (owing to the possible risk of lipiodol pulmonary embolisation secondary to the previously performed lympho-venous anastomosis, 17 - 20), we had not dared to perform X-Ray lymphography up to the moment where on the basis of the lymphoscintigraphic data, we were sure that the return of lymph to the systemic circulation was weak.
5. The radiation dosis is lower than those of a radiographic lymphangiogram.

Independently of the value of the technique in the management of neoplastic diseases, all this advantages have already led several authors to purpose radionuclide lymphangiography as a screening technic in the management and / or differential diagnosis of lower and / or upper limbs edemas of adult and / or pediatric patients (21 - 26).

As suggested by this case report, another indication of this technic could be, in cases of protein losing enteropathies, the demonstration of a chylous reflux and / or of a loss of lymph into the digestive tract. However, with regard to the surgical sanction that remains the main treatment of such situations, X-Ray lymphography has to be performed in all cases.

## REFERENCES

1. WALDMANN T.A. — Protein losing enteropathy. *Gastroenterology*, 50, 422-443, 1966.
2. RUSZNYAK I., FÖLDI M. and SZÁBO G. — Physiologie und Pathologie des Lymphkreislaufes. *Akademiai Kiado, Budapest*.
3. CRAVEN C.E., GOLDMAN A.S., LARSON D.L., PATTERSON M. and HENDRICKX Ch.K. — Congenital chylous ascites : Lymphangiographic demonstration of obstruction of the cisterna chyli and chylous reflux into the peritoneal space and small intestine. *J. Pediatr.*, 70, 340-345, 1967.
4. BOURBON R., BISMUTH V. and DESPREZ-CURELY J.P. — Les ascites chyleuses de l'adulte : apport de la lymphographie. *J. Radiol.*, 45, 413-420, 1964.
5. BOOKSTEIN J.J., FRENCH A.B. and POLLARD H.M. — Protein-losing gastroenteropathy : concepts derived from lymphangiography. *Am. J. Dig. Dis.*, 10, 573-581, 1965.
6. MISTILITIS S.P., SKYRING A.P. and STEPHEN D.D. — Intestinal lymphangiectasia : Mechanism of enteric loss of plasma-protein and fat. *Lancet*, 1965, 77-79, 1965.
7. STOELINGA G.B.A., VAN MUNSTER J.J. and SLOOF J.P. — Chylous effusions into the intestine in a patient with protein-losing gastroenteropathy. *Pediatrics*, 31, 1011-1018, 1963.
8. DONZELLI L., NORBERTO A., BARBATO G., TAPARELLO G., BASSO G. and ZACHELLO — Primary intestinal lymphangiectasia. Comparison between endoscopic and radiological findings. *Helv. Paediatr. Acta*, 35, 169-175, 1980.
9. POMERANTZ M., WALDMANN T.A. — Systemic lymphatic abnormalities associated with gastrointestinal protein loss secondary to intestinal lymphangiectasia. *Gastroenterol.*, 45, 703-711, 1963.
10. KINMONTH J.B., TAYLOR G.W. — Chylous Reflux. *Br. Med. J.*, 529-532, 1964.

11. JEEJEEBHOY K.N. and COGHILL N.F. — The measurement of gastrointestinal protein loss by a new method. *Gut*, 2, 123-130, 1961.
12. MABRY C.C., GREENLAW R.H. and DE VORE W.D. — Measurement of gastrointestinal loss of plasma albumin : a clinical and laboratory evaluation of  $^{51}\text{Cr}$  labelled albumin. *J. Nucl. Med.*, 6, 93-108, 1965.
13. ZUM WINKEL K. and HERMAN H.J. — Scintigraphy of lymph nodes. *Lymphology*, 10, 107-114, 1977.
14. BOURGEOIS P. and FRÜHLING J. — Internal Mammary Lymphoscintigraphy : current status in the treatment of Breast Cancer. *C.R.C. Critical Reviews in Oncology/Hematology*, Vol. I, 21-27, 1984.
15. BOURGEOIS P., FRÜHLING J. and HENRY J. — Postoperative axillary lymphoscintigraphy in the management of breast cancer. *Int. J. Radiat. Oncol. Biol. Phys.*, 9, 29, 1983.
16. GASQUET C., SCHNEISGUTCH O., DEBURN G. et al. — Lymphangiography in malignant disease of childhood. *Am. J. Roentgenol.*, 101, 1-12, 1968.
17. CLARK R.A. and COLLEY D.P. — Pulmonary lymphatics visualized during pedal lymphangiography. *Radiology*, 136, 29-32, 1980.
18. MARGLIN S.I. and LASTELLINO R.A. — Severe pulmonary hemorrhage following lymphography. *Cancer*, 43, 482-483, 1979.
19. PEDICELLI G., PEDICELLI C., OSTINSI M. and MAZZUSLI G. — Pulmonary embolisation resulting from iodate oil during lymphography (xero - radiographic demonstration of micro-embolisation and evaluation of the functional damage associated with it). In the *Abstracts Book of the VIIth International Congress of Lymphology*, 319, Florence, 1979.
20. SILVESTRI R.C., HUSEBY J.S., RUGHANI I., THORNING and CULVER B.H. — Respiratory Distress Syndrome from Lymphangiography Contrast Medium. *Am. Rev. Respir. Dis.*, 122, 543-549, 1980.
21. VIERAS F. and BOYD C.M. — Radionuclide lymphangiography in the evaluation of pediatric patients with lower extremity edema : concise communication. *J. Nucl. Med.*, 18, 441-444, 1977.
22. GATES G.F. and DORE E.K. — Primary Congenital lymphedema in infancy evaluated by isotope lymphangiography. *J. Nucl. Med.*, 12, 315-317, 1971.
23. JACKSON F.I., BOWEN P. and LENTLE B.C. — Scintilymphangiography with  $^{99\text{m}}\text{Tc}$ -Antimony Sulfide Colloid in hereditary lymph edema (Nonne-Milroy Disease). *Clin. Nucl. Med.*, 7, 296-298, 1978.
24. BOURGEOIS P., LANGHOR M. et VAN HOUTTE P. — Contribution of dynamic and morphological lymphoscintigraphic studies to differential diagnosis of limb edemas. In *Abstracts Book of the 10th International Congress of Angiology*. In Athènes, 1980.
25. BOURGEOIS P. et DUBOIS F. — Scintigraphic investigations in the management of upper limb edemas. *In preparation*.
26. DUBOIS F. et BOURGEOIS P. — Lymphatic clearance of the upper limbs : study by a radionuclide technique. In *Abstracts Book of the VIIIth International Congress of Lymphology*. Montreal, 1981.



## Morphological study of the vascular regeneration processes in the case of free skin grafts. Experimental approach.

Y. GEYSELS\*, P. LIEVENS\*, P. BOURGEOIS<sup>†</sup>, A. LEDUC<sup>‡</sup>

(\*) *Free University of Brussels, Faculty of Medicine and Pharmacy, Laboratory of Physical Rehabilitation, Laarbeeklaan 103, 1090 Jette, Belgium*

(\*\*) *Centre Hospitalier J. Bracops, Département de Médecine Nucléaire, Rue du Dr. Huot 79, 1070 Bruxelles, Belgique.*

### SUMMARY

The process of revascularization in supra-pannicular skin grafts in the mice were studied at various intervals up to 50 weeks after transplantation by a combination of microscopic and lymphoscintigraphic techniques. Grossly, the grafts appeared to be healed on the 20th day after grafting. Microcirculatory parameters are observed during the healing process: the vein regenerated on the 45th day after grafting in 100 % of the cases; the lymphatic collector through the transplant only in 50 %. Lymphoscintigraphic studies revealed a contralateral drainage on the first postoperative day.

Skin grafts represent a form of tissue transplantation of skin as free grafts from a donor area to a recipient site where they acquire a new blood supply derived from the recipient bed. Free skin grafts differ from skin flaps in that the revascularization of skin grafts is derived solely from the recipient bed. The process of revascularization and reattachment of a skin graft to a recipient bed is generally referred to as a "take".

The survival of any free skin graft is dependent on the re-establishment of adequate circulation (17). Although many papers (5, 8, 16, 18, 28, 32) have been published on the revascularization of full-thickness skin grafts in the initial postoperative period, vascular changes after a longer period have remained largely unexplored. For this reason this paper reports the vascular changes up to 1 year after grafting in full-thickness skin grafts to mice.

The theories about revascularization that have been reported to date can be summarized as follows: the first stage involves anastomosis, with circulation restored in the original graft vessels (primary revascularization). The second stage of revascularization involves the growth of new vessels into the transplant from the vasculature of the bed (secondary revascularization).

The purpose of this study was to approach the processes of regeneration of the blood- and lymphatic vessels during the healing of free skin grafts in mice. The process of revascularization and reattachment of a suprapannicular skin graft to its recipient bed is studied by means of vital transillumination microscopy. The microscope was connected with a SONY

CCD-color camera (fig. 1). The lymphatic regeneration is visualised by intradermal and intraganglionic injection of Patent Blue V dye. The second part of the study consists of a lymphoscintigraphic study to measure the quantity of radioactivity in the different lymph nodes in function of the regenerated lymph-vessels.

### MATERIALS AND METHODS

#### A. Microcirculation protocol

After anesthesia by ether the hair was cut over the left lateral sides of the mice. Under aseptic conditions, free skin grafts (fig. 2) were raised by cutting round four sides (1 cm × 1 cm). The place of the graft is so chosen that the abdominal main vessels (artery, vein and lymphatic vessels) are interrupted twice. The graft is totally removed and controlled (fig. 3). Suturing the graft on its bed with 5/0 silk suture follows. Finally, a dressing with extensible bandage (Leukoflex, Beiersdorf, W.-Germany) was applied. The dressings were removed 10 days after grafting.

At different intervals (from 1 day to 1 year) anesthesia was performed by urethane injection. The macroscopic parameters (adhesion, external aspect, colour, thickness and edema) even as the microscopic parameters (caliber, permeability, backflow, restoration and congestion of blood- and lymphatic vessels) were examined. Therefore the left abdominal side of the mice was turned inside out after medial incision of the abdominal skin. The total population consisted of 561 mice.

#### B. Lymphoscintigraphic protocol

The second part of this study consists of a lymphoscintigraphic study: we measured the quantity of radioactivity in the inguinal and axillary lymph nodes at different intervals (one day, two weeks and one month) after grafting. Therefore we injected subcutaneously into the hind-limb of the mice 170 microcuries in 0.2 ml of 99 mTc labelled Human Serum Albumin nanosized colloid (Nanocoll®, Solco Basle, Switzerland). The imaging of the whole body was performed with a gamma-camera (Sopha Medical) connected to a data processing system. The recording started 30 minutes after injection and consisted during 10 minutes.



After this lymphoscintigraphic study, we excised the four lymph nodes (inguinal and axillary homolateral and contralateral to the injected limb) and counted the amount of radioactivity of each lymph-node in a gamma-scintillationcounter. The total population of this part of the study consisted of 92 mice.

## RESULTS

### A. Gross observations

In this study we controlled the following parameters : the healing process of the skingraft, the color of the skingraft, the appearance of edema and the measurement of the skinthickness. The healing of the graft occurred in all cases by the 20th day after grafting. One week after operation the skin grafts were firmly adherent to the recipient bed and appeared slightly red. Two weeks after the operation the redness of the grafts had faded and the hair had regrown slightly. At almost three weeks the grafts appeared almost like normal skin. The hair regrowth was almost complete. The difference between the area of the graft and the surrounding skin was for the controlled parameters no longer detectable. The edema reached his highest level between the 4th and the 10th day after grafting. This was correlated with the measured skinthickness of the grafts (fig. 4).

### B. Microscopic examination

The results of this study are the following :

#### 1. *The vein regenerates on the 45th day after grafting.*

It occurred by anastomosis between the recipient vessels and the vessels of the skin graft in 87.3 % of the cases. In a period of 45 days after grafting the increased permeability, the dilatation and sludge of the vein was normalised. The rapid reestablishment of an inadequate circulation is the major concern that arises. At two days, the grafts appeared grossly to be paler than the adjacent skin. Graft edema which developed rapidly after grafting, was still increasing. Although hypervascularity was observed around the recipient bed, the grafts at this stage showed a hypovascularity. We observed on the 3rd day after grafting a pinkish hue of the grafts. Edema was still noted.

#### 2. *The artery do not regenerates in his original position.*

The blood supply in the graft arrives from collateral arteries which enters through the different sides of the graft. The artery never regenerates through the graft as before the grafting.

#### 3. *The lymphatic vessel regenerated only in 50 % of the cases on the 45th day after grafting.*

This means that the vein and the lymphvessel did not regenerate at the same time after grafting. The almost total restoration of the lymphvessel (94,1 %) occurred on the 6th month after grafting (fig. 5).

#### 4. *There exists no correlation between the regenerated lymphvessel and the decreasing of the postoperative edema.*

The edema is totally reabsorbed on the 28th day after grafting. Untill that day there is no regeneration of the lymphatic vessel. Perhaps the opening of lymphovenous shunts gives us the explanation of the decreased edema.

#### 5. *The lymphvessel regenerated first through a network of lymphvessels before it takes his original morphological structures back.*

A network of lymphvessels is seen in all experiments untill the 60th day after transplantation. Even if the lymphatic vessel regenerates there still exists a network at the entrance and exit of the graft (fig. 6). At 105 days after grafting this network is only seen in 30 % of the cases.

This experimental study shows that after an interruption of the lymphatic system by means of free skin grafts the lymphatic system recovers by four possible mechanisms :

1. The development of a collateral circulation ;
2. The opening of lymphaticovenous shunts ;
3. The appearance of lympholymphatic anastomosis ;
4. The regeneration of the lymphatic collectors.

### C. Lymphoscintigraphic study

The results of the lymphoscintigraphic study can be resumed as follows :

1. The injection of colloids in the hindlimb of the mice belonging of the control group are only drained along the homolateral side ; from the inguinal lymphnode to the axillary lymphnode (fig. 7).
2. On the first day after grafting we found that the original way of drainage is interrupted. No activity is found in the axillary lymphnode. We found an important activity in the inguinal lymphnode on the contralateral side. So, there exists a shift of the injected colloids to the opposite side. We even remarks a backflow from the homolateral inguinal lymphnode to the popliteal lymphnode of the injected limb (fig. 8).
3. One month after the skingrafting which interrupts the main lymphatic vessel we found a normalisation of the radioactivity in the 4 excised lymphnodes. No difference was found with the control group. Nevertheless the lymphatic vessel did not regenerated on that moment, we found that the lymphatic system normally functionated as before.

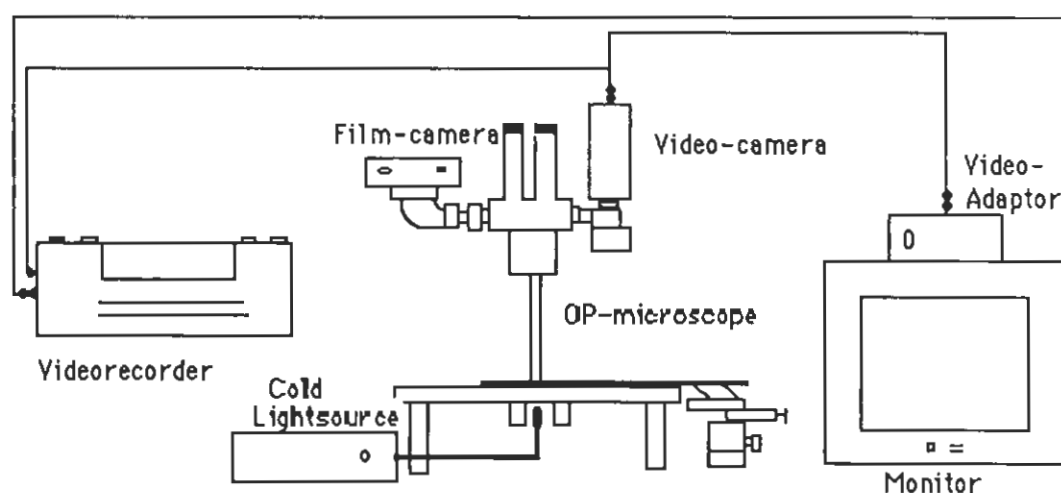
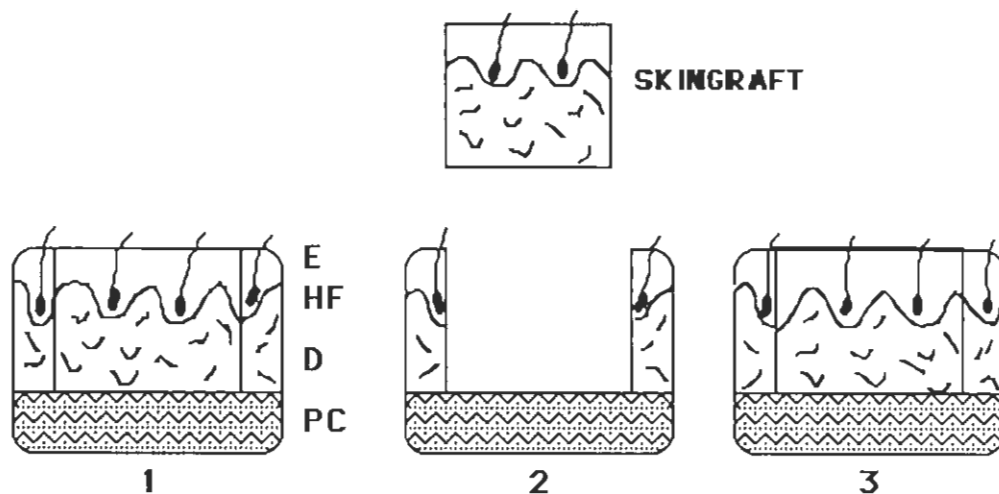
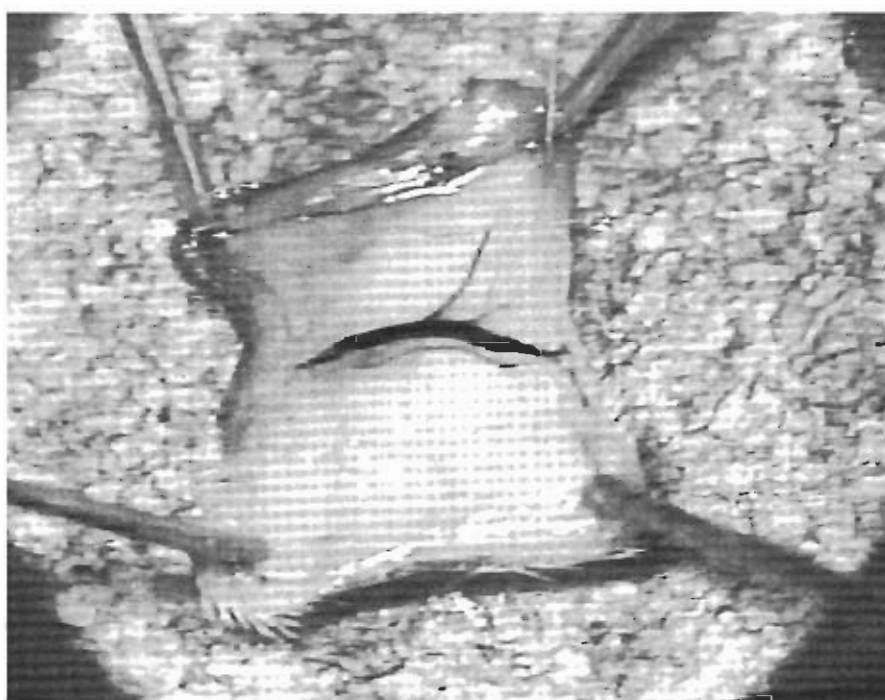


Fig 1 — Schematic drawing of the experimental equipment.



*Fig. 2 — Schematic diagram of the grafting method.  
The epidermis (E) and dermis (D) are removed leaving the Penniculum carnosus (PC) in place.  
The graft is replaced in the original position and sutured.  
(HF = Hairfollikal).*



*Fig. 3 — The suprapannicular skin graft.  
(The interrupted vein and artery are well seen).*

## DISCUSSION

This experimental study shows that after an interruption of the lymphatic system by means of free skin grafts the lymphatic system recovers by four possible mechanisms :

1. The development of a collateral circulation ;
2. The opening of lymphaticovenous shunts ;
3. The appearance of lympholymphatic anastomosis ;
4. The regeneration of the lymphatic collectors.

The network of lymphvessels still exists until the 6th month after the grafting. This was also confirmed in an other study concerning the healing of the skin after incisions (28, 29). The network of veins did never occur in any case, possibly due to the high hydrostatic pressure in the veins which allow the regeneration in one preferential way.

In a further study, we will examine the quality of the vein and lymphvessel in the graft. Can we really speak of a restoration or a regeneration of the vein or is it simply a "re"-functioning of the cutted vein ? A histologic study can inform us about the structure of the vein and lymphvessel. Do they consist of the 3 tunica or did they have only one layer of endothelial cells ?

A practical result of this study is the possibility to open pathways to the controlateral side which allows to drain the edema due to p.e. an excision of the inguinal lymphnodes by means of manual lymphdrainage.

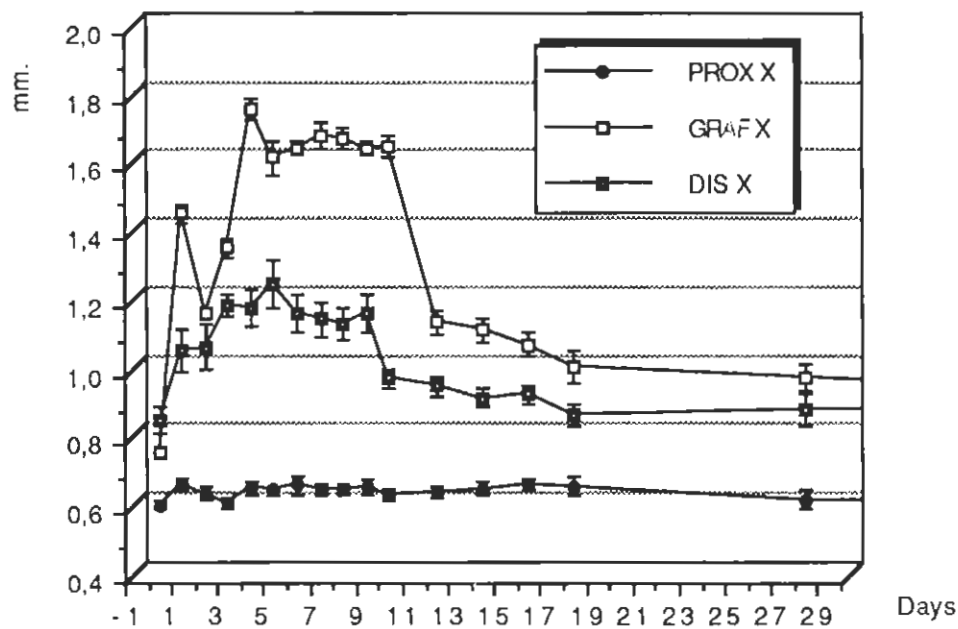


Fig. 4 — Skinthickness measured proximal, on the graft, and distal from the graftarea.  
(W : mean, SEM).

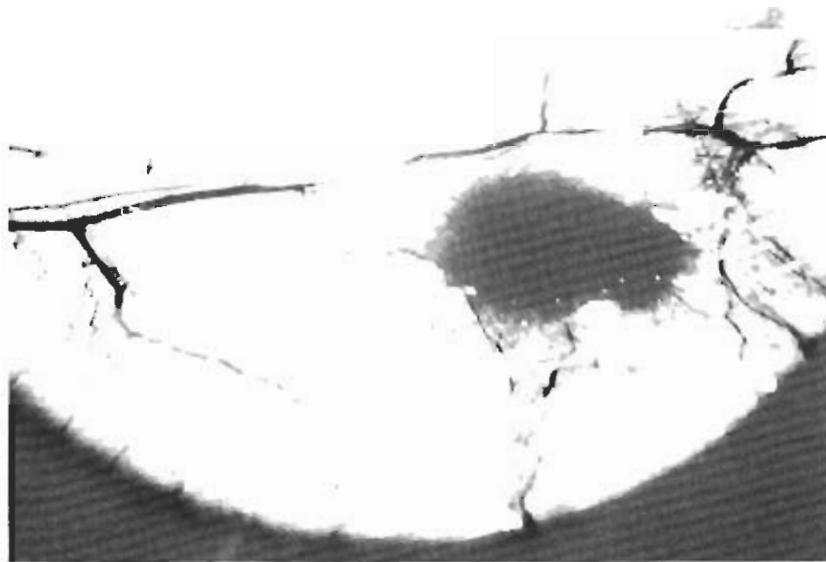


Fig. 5 — Totally restoration of vein and lymphvessel.  
Intradermal injection in the graft.  
Note the existence of a retrograde bloodflow (arrow right)  
and the regenerated lymphvessel (arrow left).

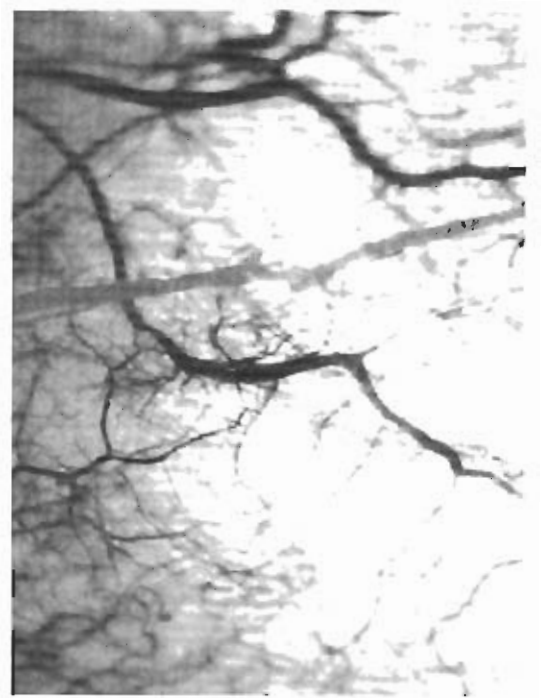


Fig. 6 — Regenerated lymphatic vessel.  
Note the appearance of a network by entering the graft.

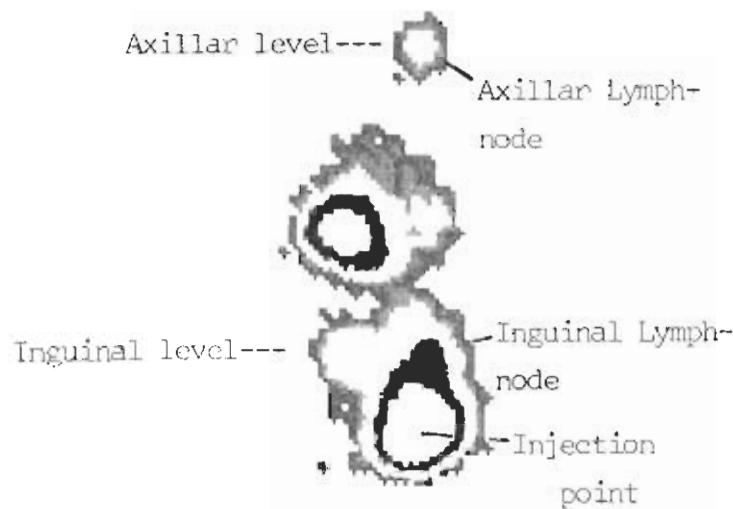
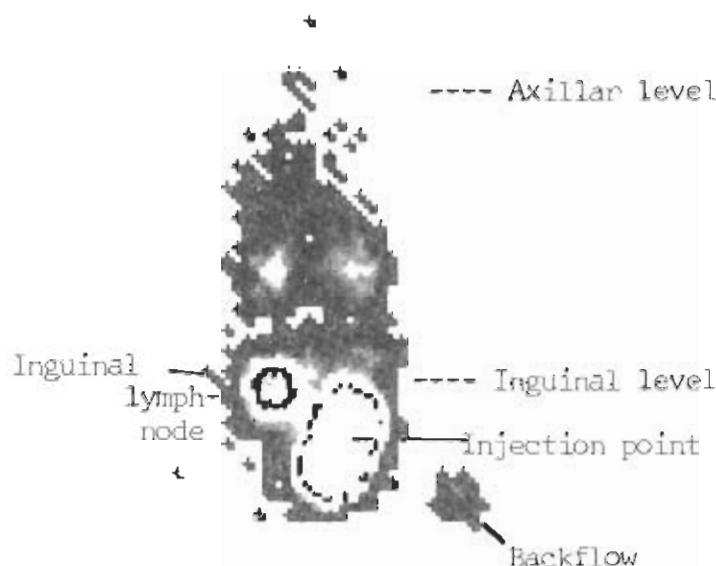


Figure 7

Scintigraphic picture obtained 30 minutes after injection of the labelled colloids in one mice of the control group. Axillary node homolateral to the injected limb is well visualised

Figure 8  
Scintigraphic picture obtained 30 minutes after injection of the labelled colloids in one mice one day after grafting. Axillary node homolateral to the injected limb is not visualised but well the heterolateral inguinal node. Popliteal node homolateral to injected limb is also demonstrated (backflow).



## REFERENCES

1. BAHARAV, E., O. LIDER, M. MARGALIT and I.R. COHEN — A modified technique for experimental skin grafting. *Journal of Immunological Methods*, **90**, 143-144 (1986).
2. BARATT, G.E. and C.F. KOOPMANN — Skin grafts : Physiology and clinical considerations. *Otolaryngologic Clinics of North America*, **17**, 335-351 (1984).
3. BECKER, C., G. HIDDEN and A. PECKING — Transplantation of lymph nodes. An alternative method for treatment of lymphoedema. In *Progress in Lymphology*, XI, Partsch, H. (Ed.), Elsevier Science Publishers B.V., Amsterdam, 1988, 487-492.
4. BECKER, C., and G. HIDDEN — Transfert de lambeaux lymphatiques libres ; microchirurgie et étude anatomique. *Journal des Maladies Vasculaires*, **13**, 119-122 (1988).
5. BILLINGHAM, R.E. and P.B. MEDAWAR — The technique of free skin grafting in mammals. *Journal of Experimental Biology*, **28**, 385-402 (1951).
6. BICH, J., P.I. BRANEMARK and J. LUNDSKOG — The influence of a vasodilator on the revascularization of a skin graft. *Scand. J. Plast. Reconstr. Surg.*, **2**, 77-82 (1968).
7. BIRCH, J. and P.I. BRANEMARK — The vascularization of a free full thickness skin graft. I. A vital microscopic study. *Scand. J. Plast. Surg.*, **3** (1969).
8. BIRCH, J., P.I. BRANEMARK and K. NILSSON — The vascularization of a free full thickness skin graft. III. An infrared thermographic study. *Scand. J. Plast. Reconstr. Surg.*, **3**, 18-22 (1969).
9. BRUENGER, A., R. HEILBRONNER, M. ANDE-REGG, M. HUBLER and H.P. ROHR — Human skin grafts on nude athymic mice : a light microscopic stereological study. *Arch. Dermatol. Res.*, **276**, 78-81 (1984).
10. BRUNA, J. — Computer tomography for the differential diagnosis of oedema of the extremities. In *Progress in lymphology*, XI, Partsch, H. (Ed.), Elsevier Science Publisher B.V., Amsterdam, 1988, 363-364.
11. CASLEY-SMITH, J.R. — Are the initial lymphatics normally pulled upon by the anchoring filaments ? *Lymphology*, 1980, 120.
12. CASLEY-SMITH, J.R. — The functioning of the lymphatic system under normal and pathological conditions : its dependence on the fine structures and permeabilities of the vessels. In *Progress in lymphology*, G. Thieme Verlag, 1966, 348-359.
13. *Lymphology*, 1980, 177.
14. CETTA, F., G. TANZINI, G. GIUBBOLINI and S. ARMENIO — Communicating lymphatics and veno-lymphatic communications in the human limbs. In *Lymphology, advances in Europe, Proceedings of the XIth Meeting GEL*, Campisi, M. Casaccia, C. (Ed.), ccig, 1989, 55-62.
15. CHACQUES, J.C., V. MITZ, P. de VERNEJOL, G. DAILLET, F. FONTALIRAN and R. VILAIN — Etude expérimentale de la circulation lymphatique après réimplantation de membres. *Ann. Chir. Plast. Esthet.*, **28**, 195-198 (1983).
16. CONVERSE, J.M. and F.T. RAPAPORT — The vascularization of skin autografts and homografts ; an experimental study in man. *Ann. Surg.*, **143**, 306-315 (1956).
17. CONVERSE, J.M., J. SMAHEL, D.L. BALLANTYNE and A.D. HARPER — Inoculation of vessels of skin graft and host bed : a fortuitous encounter. *Br. J. Plast. Surg.*, **28**, 274-282 (1975).
18. PRUNIERAS, M. — Wound healing of human skin transplanted onto the nude mouse. *British Journal of Dermatology*, **113**, 177-182 (1985).

19. GEYSELS, Y., A. LEDUC and M. TYTGAT — Etude microscopique de la régénération des vaisseaux sanguins et lymphatiques dans la reprise des greffes de peaux. *Proceedings 2me Journée Internationale Traitement Physique du Lymphœdème, Paris*, 1987, 116-119.
20. GEYSELS, Y., A. LEDUC and P. LIEVENS — Microscopic study of blood and lymphatic vessels regeneration in free skin grafts. In *Progress in Lymphology*, 11, Partsch, H. (Ed.), Elsevier Science Publishers B.V., 1988, 145-148.
21. GEYSELS, Y., A. LEDUC and P. LIEVENS — Microscopic study of blood and lymphatic vessels regeneration in free skin grafts (study on 240 mice), *Proceedings of the IXth Meeting of the Groupement Européen de Lymphologie, Grenoble*, 1988, 20.
22. GEYSELS, Y., M. LAMBERT, K. VLAMINCK, E. FINNE and A. LEDUC — Approche expérimentale de l'influence de l'acétate de dexaméthasone sur la résolution de l'œdème. *Angiologie*, 1988, 379-381.
23. GODART, S. — La microcirculation lymphatique chez la souris et le rat. *Bull. Acad. Royale de Médecine*, 7, 859-879 (1967).
24. GODART, S. — Studies of the physiology of the lymphatic vessel by microcirculation methods. *Lymphology*, 1968, 80-87.
25. GODART, S. and A. LEDUC — Blood and lymph microcirculation after burns. *Bibl. Anat.*, 1975, 181-183.
26. HIDDEN, G. — Anatomie des veines et des lymphatiques des membres. In *Circulation d'échange et de retour*, Laboratoires Boots-Dacour, 1984, 6-20.
27. HIDDEN, G., Ph. MENARD and J.Y. ZORN — Lymphaticovenous communications. *Anat. Clin.*, 7, 83-91 (1985).
28. LIEVENS, P. and S. GODART — La circulation lymphatique dans les cicatrices. *Ann. de Kinésithérapie*, 4, 3-7 (1977).
29. LIEVENS, P. — Lymphatic regeneration in wound healing. *Lymphology*, 1, 31-33 (1977).
30. OKADA, T. — Revascularization of free full thickness skin grafts in rabbits : a scanning electron microscopic study of microvascular casts. *Br. J. Plast. Surg.*, 39, 183-189 (1986).
31. PECKING, A. — Lymphœdème du membre supérieur : intérêt de la lymphographie isotopique indirecte. In *Symposium de lymphologie*, Association de lymphologie de langue française, 1981, 44-52.
32. SATJUKOWA, G.S. and I.D. KIRPATOWSKI — Lymphsystem des eingelebten und des sich abstossenden Hauttransplantats. *III Int. Congress of Lymphology, Brussels*, 1970, 92.
33. OKA, T. — A new device for free skin grafting in rats. *Plast. Reconst. Surg.*, 5, 671-672 (1981).
34. UEDA, M., Y. SUMI, T. KANEDA and K. ETO — Revascularization of reversed dermis skin grafts. *J. Oral Maxillofac. Surg.*, 44, 534-540 (1986).
35. WALKER, L.A. — Localization of radioactive colloids in lymph nodes. *J. Lab. Clin. Med.*, 36, 440 (1950).
36. WALZER, L.R. — Zur Regeneration des Lymphgefäßsystems nach Replantation und Insellappenplastik. *Acta Chirurgica Austriaca*, 66, 1-29 (1986).
37. ZUM-WINKEL, K. and K.E. SCHEER — Scintigraphic and lymphatic studies of the lymphatic system with radiocolloids. *Minerva nucl.*, 9, 390 (1965).
38. ZUM-WINKEL, K. and H.J. HERMANN — Scintigraphy of lymph nodes. *Lymphology*, 1977, 107-114.