OFFICIAL ORGAN
OF THE

EUROPEAN GROUP
OF LYMPHOLOGY
LATIN-MEDITERRANEAN
CHAPTER OF ISL
SOCIETÀ ITALIANA
DI LINFANGIOLOGIA

THE EUROPEAN JOURNAL OF lymphology

and related problems

VOLUME 12 • No. 40 • 2004

INDEXED IN EXCERPTA MEDICA

SUMMARY

THE EUROPEAN JOURNAL
OF
lymphology
and related problems
VOLUME 12 • No. 40 • 2004

PRESENTATION FROM THE NEW EDITORIAL BOARD

PROF. SANDRO MICHELINI
(Editor in Chief)

PROF. FRANCESCO BOCCARDO
(Vice Editor in Chief)

It is with great emotion and honour that, as newly appointed editors and coordinators of this prestigious scientific journal, we would like to underline the important work done by the Past Editors-in-Chief who, thanks to their scientific knowledge and experience, have contributed to make the journal a reference point in the international scientific lymphological field. It is just thanks to the high quality of the editorial board and to the collaboration of renown scientists of this branch of the medical science that the EJLRP reached greater and greater interest towards its contents.

Our foremost aim will be to keep on following the same way to enrich the value of the journal, trying to have it included in the ISI to augment its value also as concerns the impact factor, thanks to its already programmed wider international diffusion as well.

Following the best scientific tradition, we wish to invite all scientists of this field to widespread their knowledge through this journal for an open and fair exchange of experiences in the scientific ambit, respecting the editorial rules. At the same time we would like to invite the reviewers of the articles to answer within a relatively brief period of time by their comments and observations to the editorial board, considering the validity of each article from the scientific point of view, independently if one shares or not the contents. The history of science teaches us that what looks today as revolutionary and against any apparent logic, can become tomorrow a reference point for new fields of scientific research. If, conversely, the new reports are not based on any scientific basis they are likely to disappear as we are used to observe frequently reading the international literature.

It is with this spirit, inspired to the steady scientific strictness but opened to the fair exchange among different opinions of the international scientific community, that we start our editorial task, with the hard intent to increase the interest towards the EJLRP, journal that is based on a solid cultural tradition, that has always contributed in the spreading of the lymphological knowledge and that will widely continue to transmit it in the next years as a signal of continuity.

F.T. ALESSANDRO FAILLA
(Assistant Editor)

F.T. GIOVANNI MONETA
(Assistant Editor)

THE EUROPEAN JOURNAL OF
lymphology
and related problems
VOLUME 12 • No. 40 • 2004

ITALIAN SOCIETY OF LYMPHANGIOLOGY GUIDELINES

Prof. Corradino Campisi,
President of Società Italiana di Linfangiologia (SIL)
Full Professor of Surgery of the Lymphatics and Microsurgery
Department of Surgery - University of Genoa - S. Martino Hospital, Genoa

From the ***Consensus Document of the International Society of Lymphology*** *to the Guidelines of the Società Italiana di Linfangiologia. Diagnostic-therapeutic guidelines not only for lymphedema, but also for the treatment of more complex lymphedema-related lymph and chyliferous vessel diseases.*

On Friday December 5, 2004 an 'open' Session took place in Genoa of the University Master Course on Lymphology, with the participation of many authoritative experts from all over Italy and abroad (Belgium, Korea). It was the 1st Domestic Training Course on the 'Guidelines for the Diagnosis and Treatment of Lymphedema' accredited by the Ministry of Health under the Continuing Education in Medicine Program (ECM). Its novelty was that it did not just address general and specialist physicians, who were primarily invited to attend the course, but also other healthcare professionals concerned, such as physiotherapists, qualified nurses, healthcare educators, podologists. Many patients were also present in the crowded Anatomy Amphitheater of S. Martino Hospital.
The event, under the patronage of Regione Liguria, was organized by Società Italiana di Linfangiologia (SIL) with the collaboration of SIAPAV, Lombardy Section, and SIFCS, Liguria Section. Many distinguished authorities also took part: Prof. Paolo Elia Capra, Health Director, Prof. Virgilio Bachi, Director of the Surgery Department, and Prof. Mario Casaccia – both Honorary Chairmen of the event –, as well as many members of the National Scientific Committee, speakers and discussants, patient testimonials (most of them former patients!). Throughout the morning session, exciting papers were presented, all of them harmoniously and also unexpectedly integrated to provide interesting in-sight to the discussion of the Consensus Document proposals, rhythmically illustrated by Prof. Francesco Boccardo from Genoa and Dr. Sandro Michelini from Rome, who have been delegated by SIL to draw up the Guidelines which were presented to the audience for discussion.
The Guidelines illustrated below are the result of this debate. Through a seamless institutional and conceptual process, they are a practical 'translation' of the Consensus Document drawn up by the International Society of Lymphology (SIL), as recently updated and published in 'Lymphology', only wrapped up in a customized packaging to meet specific social-health needs of our country.
This contribution, which is open to interdisciplinary and inter-societal collaboration with other more or less similar domestic and international initiatives, is to be considered, jointly with ISL's Consensus Document, as a 'living document'. It will be periodically updated and adjusted to all new information expected to be produced by Evidence-Based and Problem-Oriented Medicine, through the analysis of the International Scientific Literature, which is indeed the necessary foundation of these Guidelines, as well as of all those generally meant to apply to all other Medical and Surgical disciplines.

* * *

SOCIETÀ ITALIANA DI LINFANGIOLOGIA
"EBM Guidelines on the Diagnosis and Treatment of Lymphedema"
Evidence-Based (Updated And Methodologically Validated Information from the Medical Literature)

GENERAL CONSIDERATIONS

Articles about lymphedema are often introduced with the misleading statement that the pathophysiology of the disease is unclear and treatment unsatisfactory Yet, the general principles of the pathophysiology of lymphedema are known, although the detailed pathogenesis is still open to question. On one hand, the central disturbance is a *'low output failure'* of the lymphatic system, that is overall lymphatic transport is reduced. This derangement arises either from congenital lymphatic dysplasia (primary lymphedema) or anatomical obliteration, such as after radical operative dissection (e.g. axillary, iliac-inguinal or retroperitoneal nodal dissection), from repeated lymphangitis with lymphangiosclerosis or as a consequence of functional deficiency (e.g. lymphangiospasm, paralysis and valvular insufficiency) (secondary lymphedema). The common denominator, nonetheless, is that lymphatic transport has fallen below the capacity needed to handle the presented load of microvascular filtrate including plasma protein and cells that normally leak from the bloodstream into the interstitium. 'High output failure' of the lymph circulation, on the other hand, occurs when a normal or increased transport capacity is overwhelmed by an excessive burden of blood capillary filtrate. Examples include hepatic cirrhosis (ascites), nephrotic syndrome (anasarca), and deep venous insufficiency of the leg (post-thrombophlebitis syndrome). Failure to control lymphedema may lead to repeated infections (dermato-lymphangio-adenitis- DLA), progressive elephantine trophic changes in the skin, and, on rare occasions, even the development of a highly lethal angiosarcoma (Stewart-Treves syndrome).

EPIDEMIOLOGY

According to data obtained from the International Literature – which correspond to the official data published by the World Health Organization in 1994 – the incidence of lymphedema worldwide amounts to 140 million cases (about one person out of 20). Almost half of lymphedemas are of primary origin, characterized by congenital lymphangio-dysplasia. Other 40 millions have a parasitic origin (the most common forms are caused by Filaria Bancroft infection), and they are mainly present in tropical and subtropical areas (India, Brazil, South-Africa). Some other 20 million cases are of post-surgical origin, mainly lymphedemas secondary to breast cancer treatment. The other 10 million cases are mostly caused by functional problems due to lymphatic circulation overload (especially after deep venous thrombosis of the leg and also in the so called Mayall Syndrome, namely artery-venous hyperstomy due to hyper-lymphogenesis).
With regard to the Italian situation, the results of domestic epidemiological research have shown that primary lymphedemas are more frequent than secondary ones. Lymphedemas of the upper limbs are mostly of secondary nature, whereas lymphedemas of the leg are mainly of primary origin. Females are more affected than males, and the most affected age group is the 3rd to 4th decade of life.
The incidence of more or less manifest lymphangitis as a complication of lymphostasis is very high (practically in the almost totality of cases), so much so that a prolonged antibiotic treatment is almost always required, for therapeutic as well as prophylactic purposes. In particular, out of 945 patients observed during an epidemiological study conducted by the Società Italiana di Linfangiologia, practically from all Italian regions and also from abroad (mainly from Europe), primary lymphedemas have been detected in 57% of globally considered cases, while primary lymphedemas of the arm amounted to 11% and of the legs amounted to 72%. With regard to the upper limbs, from an etiopathogenetic point of view, in the great majority of cases, lymphedema was due to axillary lymph node hypoplasia. Upon specific diagnostic investigations, even in lymphedema cases triggered by lymphangitis or traumas, an underlying lymphatic-lymph node hypoplasia – a condition which predisposes to the onset of lymph stasis in the affected limb – has been demonstrated. In almost all primary lymphedemas of the leg, lymphangio-adenodysplastic impairment has been detected, with hypoplasia and inguinal-crural lymph node fibrosclerosis in 93% of cases, and with lymphatic-chylous gravitation reflux, even in the external genitalia, due to valvular incontinence or failure of ectasic and incompetent vessels, in the remaining 7% of cases. The clinical onset of these forms of lymphedema has most frequently been spontaneous, without any apparent cause; conversely, in some cases it followed lymphangitis or trauma. Secondary lymphedemas have been diagnosed in 43% of patients. Most upper limb lymphedemas (98%) were secondary to axillary lymphoadenectomy and/or radiation therapy for breast cancer treatment, whereas in 2% of cases upper limb lymphedema ensued after the resection of axillary lipomas, axillary lymph node biopsies, or axillo-supraclavicular radiation therapy for lymphoma treatment. Secondary lymphedema in the leg was most frequently observed following uterine cervix carcinoma (46%), followed by lymphedemas as a consequence of urological tumor surgery (39%) (prostate, penis carcinoma, testicular seminal carcinoma), melanoma treatment (6%), Hodgkin lymphoma, and also after resection of lipomas from the thigh (3%), varices surgery (2%), and surgery for inguinal and crural hernia (1%).
Another important outcome of the assessment of approximately 200 women with arm lymphedema secondary to breast cancer treatment is that lymphedema developed in 20-25% of the women who had undergone mastectomy or quadrantectomy with axillary lympho-adenectomy, a percentage which went up to 35% when they were also treated with radiation therapy. These figures are in line with those found in the international literature. However, owing to the high incidence of secondary lymphedema, it is necessary to point out that lymphostasis prevention is possible, through early diagnosis, as well as timely treatment. This is very important, not only for the severe psychological implications and physical disability related to this disease, but also for the possibility to prevent severe and recurring lymphangitic complications and, in particular, the likely, although rare, onset of lymphangiosarcoma out of secondary lymphedema.

Recommendation: No final data are yet available on lymphedema epidemiology in Italy and in the world, in particular on primary lymphedema. As to secondary lymphedema, comparable data have been reported in the literature, not only on its diagnosis, complications, and prevention, but also on its incidence, prevalence, time of onset, risk factors. Grade B recommendation

CLASSIFICATION

Lymphedemas are generally divided into primary or congenital, and acquired or secondary lymphedemas.
Primary lymphedemas are further distinguished into connatal, namely already present at birth; early onset lymphedemas, if they develop before 35 years of age; late onset lymphedemas, if they develop after 35. In the connatal group of lymphedemas, a further distinction is made between sporadic and heredofamilial forms, mostly to be considered as more or less complex malformation syndromes either linked or not with genetic anomalies. C. Papendieck's Classification is generally followed to identify the type of dysplasia underlying the various forms of congenital lymphedema: LAD I (lymphangiodysplasia - dysplasia of the lymphatics); LAD II (lymphadenodysplasia - lymph node dysplasia); LAAD (lymphangioadenodysplasia - dysplasia of the lymphatics and lymph nodes). The term dysplasia includes agenesis, hypoplasia, hyperplasia, fibrosis, lymphangiomatosis, hamatomatosis, valvular insufficiency.
Secondary lymphedemas may be distinguished into post-surgical, post-trauma, post-lymphangitis, and parasitic lymphedemas.

Recommendation: In secondary lymphedemas, in particular in post-traumatic and post-lymphangitic forms, but also in those developed after surgery and/or radiation therapy, a constitutional predisposition is almost always observed (congenital dysplasia of the lymphatics and/or lymph nodes.) Grade B recommendation.

STAGING

For lymphedema staging, generally, a three stage scale is used, even if the 2nd and 3rd stage can each be subdivided into two sub-stages, thus ending up with a 5 stage scale. This staging includes primary as well a secondary lymphedemas, clinically overt and sub-clinical lymphedemas. Through proper diagnostic investigations, an initial lymph flow impairment can promptly be detected and clinical disease progression monitored, irrespective of lymphedema nature. The staging of lymphedema is based on clinical and diagnostic-instrumental criteria: e.g. extension of edema, clinical progression of disease during the day and changes due to decubitus, number and severity of lymphangitic complications, edema thickness, and disease-related skin changes. Stage 1A includes patients who have undergone surgery and are at risk of developing lymph stasis in the extremity homolateral to the site of primary disease (for example, the arm homolateral to the surgical and/or radiation therapy site in breast cancer treatment). At this stage, there is no clinical evidence of lymphedema yet, however a slower lymph flow is detected by lymphoscintigraphy, with initial dermal back flow.
Finally, severity of the clinical picture based on volume difference can be assessed as minimal (>20% increase) in limb volume, moderate (20-40% increase), or severe (>40% increase).

Recommendation:

Stage 1: a) *no edema but presence of lymphatics impairment (following mastectomy with axillary lymphadenectomy with equal extremities in volume and thickness).*
b) *Mild edema, reversible with limb elevation and night rest.*

Stage 2: *Persisting edema which subsides only partially with limb elevation and night rest.*

Stage 3: *Persisting edema (no spontaneous regression with limb elevation) and progressing disease (acute erysipeloid lymphangitis).*

Stage 4: *Fibrolymphedema (initial lymphostatic verrucosis) with 'column-shaped' limb.*

Stage 5: *Elephantiasis with severe deformation of the affected extremity, marked and extended sclerodermic pachydermitis and lymphostatic verrucosis.*

DIAGNOSIS

An accurate diagnosis of lymphedema is essential for appropriate therapy. In most patients, the diagnosis of lymphedema can be readily determined from the clinical history and physical examination: generalized edema with increased thickness, depending on its higher or lower fibrosclerotic tissue component, no pitting, even in early disease stages, Stemmer sign (e.g. lack of skin plication at the root of the second toe), dystrophic skin lesions (post-lymphangitic sequelae, lymphostatic verrucosis, lymphorrhoea, chylorrhea, etc.) frequent dermato-lymphangio-adenitis (DLA) complications. Further, lymph node examination is also useful, in order to detect any associated acute or chronic lymphadenopathy. In more complex forms of angiodysplasia, featuring arteriovenous hyperstomy (Mayall Syndrome) or congenital arteriovenous macro and microfistulas (Klippel Trenaunay or Klippel Trenaunay Servelle Syndrome), the clinical picture may feature the following: gigantism with elongation of the extremities, more or less marked foot dysmorphism, flat or map-like Port-wine stain angiomas, hyperhydrosis of the foot plant. However, there are also spurious forms, which are more difficult to diagnose, owing to prevailing lymphedematous components. Also, in some patients, confounding conditions such as morbid obesity, venous insufficiency, occult trauma, and repeated infection may complicate the clinical picture. Moreover, in considering the basis of unilateral or bilateral extremity lymphedema, especially in adults, an occult tumor needs to be considered. For these reasons, a thorough and integrated medical evaluation is indispensable before embarking on lymphedema treatment. Co-morbid conditions such as congestive heart failure, hypertension, and cerebrovascular disease including stroke may also influence the therapeutic approach undertaken.
If the diagnosis of lymphedema is unclear or in need of better definition for prognostic considerations, consultation with a clinical lymphologist or referral to a lymphologic center is recommended.

Imaging

Lymphangioscintigraphy is the first choice test for edema diagnosis, in order to confirm the nature of lymph stasis and to identify its cause (either obstacle or reflux), to evaluate the extension of disease (dermal back flow), any higher or lower damage to deep vs. surface lymphatic circulation, and drainage through lymph nodes. Therefore, the study of both deep and surface lymph circulation is useful, by proper tracer injection into specific drainage sites of both systems. This is a non invasive, easily repeatable procedure, even in newborn babies. With this imaging technique, even IA stage – not yet clinically manifest – lymph stasis can be detected, thus playing a fundamental role in secondary lymphedema prevention. This investigation technique is also useful in following up on the outcome of various lymphedema treatments and, in particular, of lymphatic microsurgery.
Lymphography is a modern investigation technique which is essential when studying complex congenital or acquired conditions of chyliferous vessels, the cisterna chyli, and the thoracic duct. Under the most modern facilities, it is performed in the operating room, under local anesthesia, with microsurgical preparation of the lymphatics. Ultrasonography, CT, and MRI are useful diagnostic tools to define complex syndromes featuring angiodysplasia and lymphedema associations, as well as to investigate the organic obstructive origin, if any, of lymphedema secondary to a tumor. In particular, for lymphedemas of the extremities, High Resolution Ultrasonography (with linear 10-14 MHz probes) depicts any increased sub- and suprafascial thickness, and its subsequent reduction after treatment. It is also useful to measure tissue compressibility and to highlight different echogenic features depending on the prevailing tissue component (e.g. water vs. tissue fibers). Hence, US is quite useful to monitor treatment outcome and for prognosis purposes. Lymphangio-MRI, in particular, using the fatty-tissue subtraction technique, provides useful information in advanced obstructive lymphedema conditions, featuring dilated

lymphatics swollen with lymph. Investigations of venous circulation with Color-Doppler Ultrasound – commonly employed for the instrumental assessment of an edematous limb –, Phleboscintigraphy, and Phlebography (if required, based on the Ultrasound examination outcome) are essential. Investigations of arterial circulation may also become necessary in pan-angiodysplasia conditions associated with lymphedema. In all these cases, in addition to Color-Doppler Ultrasound, digital arteriography may also be useful. Indirect Lymphography, Fluorescent Microlymphography, Houdack - McMaster Lymphochromic Test, flow and lymph pressure measurement, as well as Laser Doppler may all provide useful information on anatomic and functional conditions of blood micro-circulation (Laser Doppler), as well as of initial lymphatics and lymphatic collectors. However, their clinical use is limited.

Genetic Testing

Genetic testing is almost becoming practical to define a limited number of specific hereditary syndromes with discrete gene mutations such as lymphedema-distichiasis and some forms of Milroy disease. The future holds promise that such testing combined with careful phenotypic descriptions will become routine to classify familial lymphangiodysplastic syndromes and other congenital/genetic-dysmorphogenic disorders characterized by lymphedema, lymphangiectasia, and lymphangiomatosis. Recent studies have shown the association between lymphedema and anomalies of chromosomes 5, 16, 18, and 21.

Biopsy

Caution should be exercised before removing enlarged regional lymph nodes in the setting of longstanding peripheral lymphedema as the histological information is seldom helpful, and such excision may aggravate distal swelling. Fine needle aspiration with cytological examination by a skilled pathologist is a useful alternative if malignancy is suspected.

Immunohistochemical Investigations

Interesting immunohistochemical investigations have recently been conducted on lymphatics-lymph node material taken during lymphatic microsurgery and on the interstitial matrix. These studies have yielded valuable information on lymphedema physiopathology. In particular, dysfunctions of lymphatic vessel walls and of lymph nodes have been identified and classified. They progressively develop and evolve in parallel with lymphedema progression and, more specifically, proportionally with lymphedema duration. These observations have confirmed that, for a proper treatment of this disorder, whenever lymphatic drainage is lacking or obstructed, it is essential to resume its good functioning, as soon as possible. In this way, successful and long-lasting results will be obtained, through the preservation of a good autonomous lymphatic pump performance linked with smooth muscle fibrocells that are normally present in lymphatic pre-collectors and collectors, as well as in lymph node capsules. With disease progression, smooth muscle cells are gradually lost and replaced by non-dynamic fibrosclerotic tissue.

Recommendation: Lymphoscintigraphy, High Resolution Ultrasonography and Color Doppler Ultrasound are employed in the first level of diagnosis. Ultrasonography, CT, MRI and lymphography in the second level of diagnosis; phlebography, arteriography, genetic testing, and biopsy in the third level. Grade A.

TREATMENT

Therapy of peripheral lymphedema is divided into conservative (non-operative) and operative methods.

Non-operative Treatment

A) *Physical therapy*

1 - **Combined Physical Therapy (CPT).** This methodology generally involves a two-stage treatment program: the first phase consists of skin care, manual lymph drainage, range of motion exercise and compression, typically applied with multi-layered bandage-wrapping. Phase 2 (initiated promptly after Phase 1) aims to maintain and optimize the results obtained in Phase 1. It consists of skin care, compression by a low-stretch elastic stocking or sleeve, continued "remedial" exercise, and repeated manual lymph drainage, as needed. Prerequisites of successful combined physiotherapy are the availability of physicians (i.e., clinical lymphologists), nurses, and therapists highly trained and educated in this method. Compressive bandages, when applied incorrectly, can be harmful and/or useless. A prescription for low stretch elastic garments (custom made with specific measurement if needed) to maintain lymphedema reduction after CPT is essential for long-term care. Failure of CPT is confirmed only when intensive non-operative treatment in a clinic specializing in management of peripheral lymphedema and directed by an experienced clinical lymphologist has been unsuccessful.

2 - **Uniform and/or Intermittent Pneumatic Compression.** Pneumomassage is usually a three-phase program: treatment of lymph nodes proximal to the extremity, to prepare them and avoid engorgement; external compression therapy, using appropriate pressure values depending on the clinical stage of lymphedema; compression stockings or sleeves or multilayered bandaging are then used to maintain edema reduction.

3 - **Manual Lymph-drainage.** Mostly performed according to the conventional methods of the German and Belgian schools. The various massage techniques may also be combined, on a case by case approach. Not to be performed too vigorously, in order to avoid damage to lymphatic vessels and lymph nodes.

B) *Drug therapy*

1 - **Benzopyrones (b.):** these drugs include Coumarine and its derivatives (alpha-B.) and Bioflavonoids and their derivatives (gamma-b., Diosmine, Rutine, Esperidine, Quercetine, etc.)

Alpha-b. act as follows:

- Increase capillary tone
- Reduce capillary permeability to proteins

- Increase the number of macrophages
- Promote macrophage proteolytic action
- Stimulate lymphangion propulsion action
- Inhibit prostaglandin and leukotriene synthesis

Therefore their effects are as follows:
- Interstitial fluid reabsorption
- Gradual regression of fibrosis promoted by macrophage proteolysis
- Reduction of chronic inflammation with subsequent lower incidence of acute episodes and less tendency to fibrotic edema development.

Natural Coumarines, to be administered in 8 mg/die dosage for 60 days, have shown to be therapeutically effective in improving subjective symptoms, in functional recovery of the lymphedematous extremity, in reducing edema thickness, promoting bulk reduction after physical and/or microsurgical treatment, without toxic effects to the liver.

Gamma-b actions include the following:
- Reduction of endothelium permeability to protein macromolecules
- Capillary filtration reduction
- Venule tone increase

Hence, its effects are as follows:
- Stabilizing action on interstitial connective tissue and on the capillary wall
- Prostaglandin and leukotriene production inhibition.

2. **Antibiotics:** antibiotics are used during the acute phase (beta-hemolytic streptococcus therapy), for treating dermato-lymphangio-adenitis (DLA), and as a preventative prophylactic treatment against acute lymphangitis episodes (long-acting penicillin)

3. **Antimycotic drugs:** they are used to treat fungal infection of the extremities (flucanozole, etc.)

4. **Dietylcarbamazine:** To eliminate microfilariae from the bloodstream in patients with lymphatic filariasis and also for healthy carriers.

5. **Diuretics:** normally prescribed at low dosages and for short periods, specially when lymphedema is associated with phlebedema or other disorders such as heart and kidney disease, ascites, chyliferous vessels disorders, etc. They fail to remove the interstitial protein component, hence they have only a symptomatic and no etiologic effect.

6. **Diet:** In obese patients, reducing caloric intake combined with a supervised exercise program is of distinct value in decreasing limb bulk. Restricted fluid intake is not of demonstrated benefit. In chylous reflux syndromes, a diet low in lipids and the exclusive intake of medium-chain triglycerides (MCT) which are absorbed via the portal vein, without overloading the chyliferous vessel system, has proved to be of great benefit especially in children.

Therefore, there is a wide range of pharmacologic and therapeutic principles available. Which one is to be selected depends on etiopathogenic and physiopathologic features of each type of lymphedema.

The use of vascular endothelial lymphedema-specific growth factors (VEGF-C and VEGF-D) is still under investigation and waiting for final trials for both primary and secondary lymphedema.

C) Psychosocial rehabilitation

Psychosocial support with a quality of life assessment-improvement program is an integral and fundamental component of any lymphedema treatment.

> *Recommendation: The various non operative therapeutical methods must be applied in a combined and integrated manner, on a case by case basis, and depending on the clinical stage of lymphedema. Grade B.*

Operative Treatment

Surgical techniques employed in the past to treat lymphedema would focus on bulk reduction of the affected limbs by a debulking-resection operation (cutolipofascectomy, total surface lymphangectomy, Thompson's operation, etc.). However, these were only symptomatic treatments: since they would not remove the cause of lymph flow obstruction, they were reducing lymphedema only temporarily, while they would require long hospitalization periods, and would frequently be accompanied by infections, delayed wound healing, loss of sensitivity, residual and progressing edema of the ankle and foot, as well as extensive retracting and disfiguring scars. Following the advent of Microsurgery, functional and causal therapeutic solutions for lymphedema were investigated and implemented aiming at draining the lymph flow or reconstructing the lymphatic pathways where they had been obstructed or were missing. Fine, repairing techniques were employed with direct intervention on the very lymphatic structures. Microsurgery techniques have yielded positive and long-lasting results in the treatment of primary lymphedemas – including those in children – as well as in secondary lymphedemas following cancer treatment, involving lymph node resection in some 'critical' areas, such as in the armpit and the groin. Direct intervention on lymphatic-lymph node structures was first performed by multiple antigravitational ligatures of incompetent lymphatic and chyliferous vessels according to Servelle and Tosatti, to treat gravitational reflux lymphochyledema; Kinmonth (bridge) procedure was also employed, featuring the anastomosis of iliac-inguinal lymph nodes with an ileum segment, after mucosa removal from its mesenteric pedicle. However, with the progress made in surgical equipment design, armamentarium and techniques, two microsurgery methods have been developed for a 'conservative and functional' treatment of lymphedema, namely derivative and reconstructive microsurgery. Derivative microsurgery techniques aim to resume lymph flow at the obstruction site, through a lymph-venous drainage in which lymph nodes or, directly, lymphatics are employed: Lymph node-Venous Anastomosis (LNVA), Lymphatic-Capsular-Venous Anastomosis (LCVA), End-to-end Lymphatic - Venous Anastomosis (EE-LVA), End-to-side Lymphatic - Venous Anastomosis (ES-LVA). Most recently, multiple, end-to-end and end-to-side lymphatic-venous anastomoses are most commonly employed, which are fashioned directly with the use of major veins or their collaterals, depending

on the anatomic picture at the time of surgery, and performed at 1/3 midportion of the forearm volar surface and in the inguinocrural region for the arm and leg, respectively. Conversely, with reconstructive microsurgery techniques, the lymphatic flow is resumed by overcoming the obstruction site either through a direct anastomosis of afferent and efferent lymphatics, or through the implant of autologous or venous segments between collectors down and upstream the obstruction: Lymphatic-lymphatic Anastomosis (LLA), Segmental Lymphatic Vessel Autotransplantation (SLAT), Lymphatic-Venous- Lymphatic - Plasty or Lymphatic-Venous- Lymphatic Anastomosis (LVLA), Free Lymphatic- Lymph Nodal Flaps (FLF). With the LVLA technique, also bilateral lymphedemas can be treated, without risk of causing any iatrogenic lymphedema on the harvest site, as could instead happen when harvesting a lymphatic-lymph node specimen. Indications for the various microsurgical techniques depend on the presence of a viable lymphatic-venous pressure gradient in the affected limb. Should lymphostatic deficiency be associated with venous insufficiency (a condition mostly found in the lower extremities: varices, venous hypertension, valvular incontinence), derivative microsurgery is not recommended, while only reconstruction techniques can be applied.

Recommendation: Conventional surgical debulking-resective techniques are to be confined to cases in which it is necessary to remove excess skin and subcutaneous tissue of the lymphedematous limb, following a significant lymphedema reduction with CPT and/or microsurgery. Microsurgical procedures are highly beneficial specially in the early stages of disease: through the resumption of preferential lymph flow pathways in the affected extremity, good results (even healing) can be achieved with Microsurgery. Long term efficacy of lymphatic-venous anastomoses mainly depends on the accuracy of the adopted technique (the use of the operative microscope is essential) and on disease stage. Grade B.

PREVENTION

Prevention of lymphedema secondary to breast cancer treatment with surgery and/or radiation therapy is possible today specially thanks to lymphoscintigraphy, which permits the study – before or after tumor treatment – of the anatomic-functional lymph flow system in the homolateral arm.
In this way, it is thus possible to identify patients at (low, medium, or high) risk of secondary lymphedema onset. Therefore, these patients could successfully benefit from early – rather than late – therapeutic measures which best suit them on a case by case basis, depending on the identified lymph flow damage extension.
This investigation must be performed by subcutaneous (and not intradermal) radiotracer injection into the interdigital folds at the root of the extremity, in order to ensure that there is no tracer escape and, therefore, no false positive results from the test.
The Protocol for Secondary Lymphedema Prevention following breast cancer treatment drawn up by Società Italiana di Linfangiologia provides a list of clinical and lymphoscintigraphic criteria on which preventative measures have been established to be taken before, during, and after surgery, including the option of microsurgical lymphatic-venous anastomosis to be immediately performed together with axillary lymph node resection.
Further, lymphoscintigraphy performed in blood-relatives of patients with primary lymphedema or in patients who have undergone radical lymphadenectomy for cancer treatment at the root of the extremity or complementary radiation therapy, who show no edema in the affected limb, may show a slower radiotracer flow (presence of lymph node stops along the extremity which could not be otherwise displayed). This is a sign of some propensity to developing lymphedema (preclinical studies).

Recommendation: Today, the chances to prevent arm lymphedema secondary to breast cancer treatment are real, through the implementation of a prevention protocol based on clinical criteria, as well as on lymphoscintigraphy outcome. Grade B.

Società Italiana di Linfangiologia
"GUIDELINES - EBM
ON THE DIAGNOSIS AND THERAPY
OF LYMPHEDEMA"

Recommendations:

Grade A - Randomized clinical trials, meta-analyses, no heterogeneity

Grade B - Randomized clinical trials also on small populations, meta-analysis also of non randomized trials, some heterogeneity is possible

Grade C - Recommendation based on observational studies and on consensus reached by the authors of these guidelines.

Società Italiana di Linfangiologia
"GUIDELINES - EBM
ON THE DIAGNOSIS AND THERAPY
OF LYMPHEDEMA"
FUTURE PROSPECTS

- PREVENTION OF PRIMARY LYMPHEDEMA
- GENE THERAPY

ANGIODYSPLASIA AND LYMPHEDEMA

Cases of lymphatic dysplasia associated with vascular defects are defined as hemolymphatic malformations. According to the Hamburg classification (1988), congenital vascular malformations are grouped depending on the predominant defect: arterial, venous, lymphatic defects, A-V shunting defects or combined vascular defects. Each of these pictures is then subdivided into truncular and extratruncular forms, depending on the time and site of embryo defect onset.

Lymphatic malformations, classified under extratruncular (limited or diffuse) forms, are conventionally defined as lymphangiomas or lymphangiomatosis.
Truncular forms, which affect the major vessels (aplasia, hypoplasia, dilatation or hyperplasia), may cause lymphedema. Further, lymphatic malformations may be associated with osteodystrophic syndromes (s.): angio-osteohypertrophic s. (with bone segment elongation), or angio-osteohypotrophic s. (with bone segment shortening). Comprehensive and integrated diagnostic procedures must be implemented with investigations of the arterial, venous, and lymphatic components. CT and MRI are useful to define malformation extent and relationships. Treatment features conservative medical-physical methods, in the mildest cases. Surgical treatment includes derivative and reconstructive lymphatic microsurgery, resection of tissues mostly affected by dysplasia, and antigravitational ligatures of incompetent lymphatics. Alternatively or in association with surgery, there are also treatment options by percutaneous sclerotherapy of lymphangiomatous and lymphangectasic areas and/or embolotherapy of arteriovenous fistulas.

Recommendation: Hemolymphatic malformations, although rare, are due to highly complex vascular defects. They are nosographically classified according to the Hamburg Classification. Comprehensive and integrated diagnostic investigations must be conducted focused on the arterial, venous, and lymphatic components. CT and MRI are used to provide a comprehensive definition of malformation extent and relationships. Therapy features conservative, surgical, sclerotherapic methods, as well as percutaneous embolization, in varying mutual combinations, depending on the specific physiological features underlying each single case. Grade C.

NEONATAL LYMPHATIC DYSPLASIA

Lymphoscintigraphic investigations have recently been conducted on newborn babies with complex clinical pictures with hydrops, in order to determine the likely lymphatic origin of their malformation. The task of CPR professionals in these cases is to conduct a primary assessment with treatment of respiratory and heart-blood circulation problems they are faced with from time to time, in order to ensure the survival of the baby, followed by a second, more accurate assessment, and by the final treatment. Lymphatic circulation investigations by lymphoscintigraphy are part of the procedures of a secondary assessment. Indeed, from a physiopathologic point of view, if hydrops conditions are not due to congestive heart failure or to decreased osmotic plasma pressure and increased capillary filtration, they may well be due to lymphatic malformations (chylothorax, chylous ascites, lymphedema, etc.)

Recommendation: In the assessment of a newborn baby with hydrops, after giving support to his/her life functions, also lymphatic circulation is to be considered as a possible cause of hydrops, an investigation which today is helped by lymphoscintigraphy.

FUTURE PROSPECTS

Among future prospects, there is the possibility to successfully treat primary lymphedema, and, in particular, congenital heredofamilial forms.
The chance to prevent lymphedema in the members of a family affected by heredofamilial lymphangiodysplastic syndrome is based on diagnostic procedures, such as lymphoscintigraphy and laser-doppler ultrasound, which can provide direct and indirect morphological-functional parameters on lymph circulation in the extremities, and disclose lymphatic drainage failure even before any clinical onset of the edema. This 'latent' phase of lymphedema is important to identify patients at risk, who will then be referred for preventative medical-physical treatment.
On this point, currently ongoing genetic and molecular biology studies are very important.
Finally, investigations are being conducted on the application of gene therapy for the treatment of primary lymphedema.

Società Italiana di Linfangiologia
"GUIDELINES - EBM
ON THE DIAGNOSIS AND THERAPY
OF LYMPHEDEMA"

- Evidence based (143 References)
- Recommendations

REFERENCES

1. *Abalmasov KG, Egorov YS, Abramov YA, Chatterjee SS, Uvarov DL, Neiman VA. Evaluation of the greater omentum in the treatment of experimental lymphedema. Lymphology 1994 Sep; 27 (3): 129-36.*

2. *Al Assal F, Cordeiro AK, De Souza e Castro I. A new technique of microlympho-venous anastomoses. Experimental study. J Cardiovasc Surg 1988 Sep-Oct; 29(5): 552-5.*

3. *Alitalo K., Karkkainen M.: VEGF-C and VEGF-D growth factor therapy for lymphedema. Abstract book of XIX international congress of Lymphology. Friburgo, 1-6 settembre 2003.*

4. *Allegra C et al. Morphological and functional characters of the cutaneous lymphatics in primary lymphedemas. Europ J Lymphol Rel Probl 1996; 6: I, 24.*

5. *Badini A, Fulcheri E, Campisi C, Boccardo F. A new approach in histopathological diagnosis of lymphedema: pathophysiological and therapeutic implications. Lymphology 1996; 29 (S): 190-198.*

6. *Battezzati M., I.Donini: "Il sistema linfatico nella pratica clinica", Piccin, Padova, 1967.*

7. *Baumeister RG, Siuda S. Treatment of lymphedemas by microsurgical lymphatic grafting: what is proved? Plast Reconstr Surg 1990 Jan; 85(1): 64-74.*

8. *Becker C., Hidden G., Godart S., Maurage H., Pecking A.: "Free lymphatic transplant". EJLRP 1991, 2, 6, 75-77.*

9. *Belardi P.: "Terapia dei linfedemi", in Casaccia M., Campisi C. (eds.), Lymphology: advances in Europe, ecig, Genova, 215-220, 1989.*

10. Bellini C, Mazzella M, Arioni C, Campisi C, Taddei G, Toma P, Boccardo F, Hennekam RC, Serra G. Hennekam syndrome presenting as nonimmune hydrops fetalis, congenital chylothorax, and congenital pulmonary lymphangiectasia. Am J Med Genet. 2003 Jul 1; 120A(1):92-6.

11. Bellini C, Arioni C, Mazzella M, Campisi C, Taddei G, Boccardo F, Serra G. Lymphoscintigraphic evaluation of congenital lymphedema of the newborn. Clin Nucl Med. 2002 May;27(5):383-4.

12. Belov St, Loose DA, Weber J. Vascular Malformations. Periodica Angiologica 16 - Einhorn, Presse Verlag, 1989.

13. Benda K., Lebloch D., Bendova M.: Prevention of primary lymphedema- Possible way. Lymphology 31 (Suppl) 1998: 465-468.

14. Biassoni P., C.Campisi, G.Villa, F.Boccardo: "Isotopic lymphography in the diagnosis and follow-up of lymphedemas treated by microsurgery". Lymphology 29 (Suppl): 101-105, 1996.

15. Boccardo F, Campisi C et al. A Pilot Study on Prevention of Secondary Lymphedema. Lymphology 2000; 33: 222-225.

16. Boccardo F, Campisi C, Zilli A, Casaccia M. Direct lymphography with microsurgical technique: indications and results. Lymphology 1998; 31 (Suppl): 559-561.

17. Boccardo F, Michelini S, Zilli A, Campisi C. Epidemiology of Lymphedema. Phlebolymphology 1999; 26: 24-28.

18. Boccardo F, Zilli A, Pianezza M., Campisi C. A pilot study on prevention of secondary lymphedema. Lymphology 2000; 33S: 222-225.

19. Bollinger A, Jager K, Sgier F, Seglias J. Fluorescence microlymphography. Circulation 1981; 64(1): 195-200.

20. Bourgeois P, Leduc O, Leduc A. Imaging techniques in the management and prevention of posttherapeutic upper limb edemas. Cancer 1998 Dec 15; 83 (12 Suppl American): 2805-13.

21. Bourgeois P., Wolter F.: "Lymphoscintigraphy demonstration of a protein loosing enteropathy". EJLRP 1990, 18, 44-46.

22. Bruna J, Brunova J, Jurgova T. Direct lymphography as safe procedure. Lymphology 1996; 29 (Suppl): 111-113.

23. Bruna J.: "Indication for lymphography in the era of new imaging methods". Lymphology 1994, 27 (Suppl), 319-320.

24. Campisi C., Boccardo F. Role of microsurgery in the management of lymphoedema. Int Angiol 1999; 18: 47-51.

25. Campisi C, Boccardo F, Borralli V, Zilli A, Campisi M. Linfedema dell'arto superiore secondario a trattamento per cancro della mammella: moderni aspetti di prevenzione, diagnosi e terapia microchirurgica. Clinica Chirurgica e Microchirurgia 1998; 2: 110-5.

26. Campisi C, Boccardo F, Casaccia M. Il linfedema dell'arto superiore secondario a linfoadenectomia e radioterapia adiuvante per cancro della mammella. Ospedali d'Italia Chirurgia 1997; 3: 112-8.

27. Campisi C, Boccardo F, De Caro G, Ieracitano VM, Zilli A. Angiodysplasias, peripheral lymphoedema, and tumorigenous syndromes. Lymphology 1998; 31 (Suppl); 378-380.

28. Campisi C, Boccardo F, Tacchella M, Zilli A. Current Diagnostic Aspects and Surgical Treatment of Lymphedema. Lymphology 1998; 31 (Suppl): 589-591.

29. Campisi C, Boccardo F, Tacchella M. Reconstructive Microsurgery of Lymph Vessels: the Personal Method of Lymphatic-Venous-Lymphatic (LVL) Interpositioned Grafted Shunt. Microsurgery 1995; 16: 161-166.

30. Campisi C, Boccardo F, Zilli A, Borrelli V. Chylous reflux pathologies: diagnosis and microsurgical treatment. International Angiology, vol.18, n.1, March 1999; 10-13.

31. Campisi C, Boccardo F, Zilli A, Macciò A, Napoli F. Long-Term Results After Lymphatic-Venous Anastomoses for the Treatment of Obstructive Lymphedema. Microsurgery 2001; 21: 135-139.

32. Campisi C, Boccardo F, Zilli A, Macciò A, Napoli F. The Use of Vein Grafts in the Treatment of Peripheral Lymphedemas: Long-Term Results. Microsurgery 2001; 21: 143-147.

33. Campisi C, Boccardo F. Frontiers in Lymphatic Microsurgery. Microsurgery 1988; 18: 462-471.

34. Campisi C, Boccardo F. Lymphedema and Microsurgery (Invited Review). Microsurgery 2002; 22: 74-80.

35. Campisi C, Boccardo F. Lymphoedema. In: Geroulakos G, van Urk H, Hobson RW, Calligaro KD, eds. Vascular Surgery: Cases, Questions and Commentaries. Springer; 2003; 361-371.

36. Campisi C, Boccardo F. Prevention of secondary lymphedema. Possible role of Microsurgery. Lymphology 1996; 29 (Suppl): 41-43.

37. Campisi C, Jiménez Cossio JA, Pissas A, Leduc A, Michelini S, Boccardo F, Zilli A. Prevention of Secondary Lymphedema: Prospects for the Future. Lymphology 1998; 31 (Suppl): 513-515.

38. Campisi C, Michelini S, Boccardo F, Zilli A. Lymphedema Epidemiology in Italy. Lymphology 1998; 31 (Suppl): 243-244.

39. Campisi C. Angiodysplasia and Lymphedema: aspects of diagnosis and treatment. Lymphology 1994; 27 (Suppl): 154-159.

40. Campisi C. et al.: "Lymphatic or venous grafts in the microsurgical treatment of lymphoedemas: first clinical trials". Microsurgery Scientific Reports, 1984, 4: 20-24.

41. Campisi C. Il linfedema: aspetti attuali di diagnosi e terapia. Flebologia Oggi 1997; 1: 27-41.

42. Campisi C. Lymphatic microsurgery: a potent weapon in the war on lymphedema. Lymphology 1995; 28: 110-112.

43. Campisi C. Lymphoedema: modern diagnostic and therapeutic aspects. Int Angiol 1999 Mar; 18 (1): 14-24.

44. Campisi C., Badini A., Boccardo F.: "Anatomo-pathological bases in the management of primary lymphedema and microsurgical implications". Lymphology 1994, 27 (Suppl), 546-549.

45. Campisi C., Boccardo F., Campisi C.M.: "Use of autologous interposition vein graft in management of lymphedema: 11 year clinical experience". Lymphology 1994, 27 (Suppl), 810-814.

46. Campisi C., Boccardo F., Casaccia M.Jr.: "La greffe veineuse autologue en microchirurgie lymphatique recostructive". EJLRP, 1991, 2, 6, 48-61.

47. Campisi C., Boccardo F., Padula P., Tacchella M.: "Prevention of lymphedema: utopia or possible reality?". Lymphology 1994, 27 (Suppl), 676-682.

48. Campisi C., Boccardo F., Tacchella M.: "A protocol for studying and managing lymphedema". Lymphology 1994, 27 (Suppl), 543-545.

49. Campisi C., Boccardo F., Tacchella M.: "Lymphangitis and lymphedema: new personal method of thermotherapy". Lymphology 1994, 27 (Suppl), 639-643.

50. Campisi C., Boccardo F., Tacchella M.: "The present role of isotope lymphangioscintigraphy and conventional lymphography in delineating the status of lymphatic and chylous collectors". Lymphology 1994, 27 (Suppl), 282-285.

51. Campisi C., F. Boccardo: "Prevention of secondary lymphedema: possible role of Microsurgery". Lymphology 29 (Suppl): 41-43, 1996.

52. Campisi C., Olszewski W., Boccardo F.: "Il gradiente pressorio linfo-venoso in microchirurgia linfatica". Minerva Angiologica, 1994, 19.

53. Campisi C., Zattoni J., Siani C., Casaccia M., Tosatti E.: "Twenty year clinical experience in the microsurgical management of lymphedema". Lymphology 1994, 27 (Suppl), 651-657.

54. Campisi C., Boccardo F., Casaccia M. Jr., Padula P., Campisi C.M.: "Microsurgical indications and techniques in management of lymphedema". Lymphology 1994, 27 (Suppl), 803-809.

55. Campisi C.: "Lymphatic microsurgery: legend or reality?". Phlebolymphology, 1994, 7, 11-15.

56. Campisi C.: "Rational approach in the management of lymphedema". Lymphology 1991, 24, 48-53.

57. Campisi C.: "Surgery of the lymphatic vessels: state of art". Editorial, The European Journal of Lymphology and Related Problems (EJLRP), 1991, 2, 6.

58. Campisi C.: "The modern surgery of lymphedema". Lymphology, 29 (Suppl), 210-221, 1996.

59. Campisi C.: "Use of autologous interposition vein graft in management of lymphedema". Lymphology 1991, 24, 71-76.

60. Campisi, C.: Microchirurgia Applicata in Clinica Chirurgica Generale e d'Urgenza. Monography, 300 pages, Utet, 1991.

61. Casaccia M, Campisi C. Chyloedèmes. J Malad Vascul 1988; 13: 39-42.

62. Case TC, Witte CL, Witte MH, Unger EC, Williams WH. Magnetic Resonance Imaging in Human Lymphedema: Comparison with Lymphangioscintigraphy. JMRI 1992; 10: 549-558.

63. Casley-Smith J. Modern treatment for lymphoedema. The Lymphoedema Association of Australia, Inc., Adelaide, 1994.

64. Casley-Smith J.R., Casley-Smith Judith R.: "High-Protein Edemas and the Benzo-Pyrones". Sydney, J.B. Lippincott Company, 1986.

65. Casley-Smith JR. Alterations of Untreated Lymphedema and its Grades Over Time. Lymphology 1995; 28: 174-185.

66. Ch.L.Witte: "Breast Cancer-An Overview". Lymphology 27(Suppl.) 397-400, 1994.

67. Chang Ti-Sheng: "Micro-wave heating oven: progress in heating and bandage treatment of chronic lymphoedema of the extremities". Progress in Lymphology. Xth ISL Congress, Adelaide, 1985, 168-170.

68. Charles R.H.: "A system of treatment". Latham A. e English T.C. (eds.), Churchill, London, 1912, 3, 504.

69. Clodius L. et Al.: "The problems of lymphatic microsurgery for lymphoedema". Lymphology 1981, 14: 69.

70. Clodius L. Problems of microsurgery in lymphedema. Handchir Mikrochir Plast Chir 1982; 14(2): 79-82.

71. Cockett ATK, Goodwin WE. Chyluria: attempted surgical treatment by lymphatic venous anastomosis. J Urol 1962; 88: 566-8.

72. Cossio J.A.: "Diagnostico y tratamiento de los linfedemas". Barcellone, Ed. Centro de Documentacio de Laboratorios Uriach, 1987.

73. Cossio J.A.: "Progresos en Linfologia I". Madrid, Jarpyo Editores SA, 1987.

74. Degni M. New microsurgical technique of lymphatico-venous anastomosis for the treatment of lymphedema. Lymphology 1981 Jun; 14(2): 61-3.

75. Degni M.: "New techniques of lymphatic-venous anastomosis for the treatment of lymphoedema". Cardiovascular Rivista Brasileira, 1974, 10, 175.

76. Dellachà A, Fulcheri E, Boccardo F, Campisi C. Post-Surgical Lymphedema: Iatrogenic or Pre-existing Disease? Lymphology 1998; 31: 562-565.

77. Erickson VS, Pearson ML, Ganz PA, Adams J, Kahn KL. Arm edema in breast cancer patients. J Natl Cancer Inst 2001 Jan 17; 93(2): 96-111

78. Farrar WB et al. Breast Cancer. In: McKenna RJ, Murphy GP (eds). Cancer Surgery. Philadelphia: JB Lippincott Company, 1994; 209: 259.

79. Farrar WB et al. Breast Cancer. In: RJ McKenna, GP Murphy, Cancer Surgery, JB Lippincott Company, Philadelphia, 1994: 209-259.

80. Ferrandez JC, Serin D, Bouges S. Frequency of lymphedema of the upper limb after treatment of breast cancer. Risk factors. A propos of 683 cases. Bull Cancer 1996 Dec; 83 (12): 989-95.

81. Ferrel R.E., Levinson K.L., Esman J.H., Komak M.A., Lawrence E.C., Barmada M.M., Finegold D.N.: Hereditary lymphedema evidence for linkage and genetic heterogeneity. Hum. Mol. Genet. 1998 Dec. 7 :13, 2073-8.

82. Földi E, Földi M. Physiothérapie complete décongestive. Paris, Editions Frison-Roche, 1993.

83. Földi M.: "The conservative treatment of lymphoedema and physiology and pathophysiology of the lymphatic circulation". Proceedings of the 4th ISL Congress, Tucson, Arizona, 1973.

84. Földi M.: "The therapy of lymphedema". EJLRP 1993-1994, 14, 43-49.

85. Giampalmo, A: Patologia delle Malformazioni Vascolari. Società Ed. Universo, Roma, 1972.

86. Gloviczki P, Fisher J, Hollier LH, Pairolero PC, Schirger A, Wahn HW. Microsurgical lymphovenous anastomosis for the treatment of lymphedema: a critical review. J Vasc Surg 1988 May; 7(5): 647-52.

87. Gruwez J.: "Lymphoedema, basic mechanism, clinical problems, indications for therapy, chylous reflux". ISL Congress, Tucson, Arizona, 1973.

88. Gruwez, JA, T Lerut, T Rahardjo, F Van Elst: The lymphatics in angiodysplastic syndromes. Progress in Lymphology, Proc. VIIth Int. Congr. ISL, Florence 1979, Avicenum Czechoslovak, Medical Press, Prague 1981.

89. Gyapong JO, Adjei S, Sackey SO. Descriptive epidemiology of lymphatic filariasis in Ghana. Trans R Soc Trop Med Hyg 1996 Jan-Feb; 90 (1): 26-30.

90. Handley WS. Lymphangioplasty : a new method for the relief of the brawny arm of breast-cancer and for similar conditions of lymphatic oedema. Lancet 1908; i: 783-5.

91. Harel L, Amir J, Nussinovitch M, Straussberg R, Varsano I. Lymphedema praecox seen as isolated unilateral arm involvement: case report and review of the literature. J Pediatr 1997 Mar; 130 (3): 492-4.

92. Ho LC, Lai MF, Yeates M, Fernandez V. Microlymphatic bypass in obstructive lymphoedema. Br J Plast Sug 1988 Sep; 41 (5) : 475-84.

93. Huang GK, Hu RQ, Liu ZZ, Shen YL, Lan TD, Pan GP. Microlymphaticovenous anastomosis in the treatment of lower limb obstructive lymphedema: analysis of 91 cases. Plast Reconstr Surg 1985 Nov; 76(5): 671-85.

94. Insua EM: "Diagnostico por imagen de la patologìa veno-linfàtica de las extremidades". Linfologia, n. 3, año 2, 15-20, 1996.

95. Jamal S, Kumaraswami V, Witte MH, Witte CL, McNeill GC, Williams WH. Lymphatic abnormalities in microfilaraemics by lymphoscintigraphy. In: Progress in Lymphology XIV - Lymphology 1994; 27(Suppl).

96. Jamal S. Failure in Lymphedema Treatment (Filarial). The Patient Factor. Lymphology 1998; 31 (Suppl): 403-406.

97. Karlsson P, Holmberg E, Johansson KA, Kindblom LG, Carstensen J, Wallgren A. Soft tissue sarcoma after treatment for breast cancer. Radiother Oncol 1996 Jan; 38 (1): 25-31.

98. Kinmonth JB, Hurst PAE, Edwards JM, Rutt DL. Relief of lymph obstruction by use of a bridge of mesentery and ileum. Br J Surg 1978; 65: 829.

99. Kinmonth JB. The Lymphatics. Surgery, lymphography and diseases of the chyle and lymph systems. London: Edward Arnold (Publishers) Ltd, 1982.

100. Krylov Vs, Milanov NO, Abalmasov KG, Sandrikov VA, Sadovnikov VI. Reconstructive microsurgery in treatment of lymphoedema in extremities. Int Angiol 1985 Apr-Jun; 4(2): 171-5.

101. Leduc A. Le drainage lymphatique. Théorie et pratique. Paris, Masson, 1980.

102. Leitch AM, Meek AG, Smith RA, Boris M, Bourgeois P, Higgins S et al. American Cancer Society Lymphedema Workshop. Workgroup I: Treatment of the axilla with surgery and radiation -- preoperative and postoperative risk assessment. Cancer 1998 Dec 15; 83 (12 Suppl American): 2877-9.

103. Logan V. Incidence and prevalence of lymphoedema: a literature review. J Clin Nurs 1995 Jul; 4 (4): 213-9.

104. Mariani G, Campisi C, Taddei G, Boccardo F, Martini F, Rahimi Mansour A, Zilli A. The current role of lymphoscintigraphy in the diagnostic evaluation of patients with peripheral lymphedema. Lymphology 1998; 31 (Suppl): 316-319.

105. Matassi R, Vaghi M, Abbritti F. Superficial Lymphatic dysplasia: surgical treatment. The European J. Lymphology and Related Problems 2002-2003; Vol. 10 n. 37-38: 8-11.

106. Mayall RC, Mayall ACDG, Mayall JC, Freitas J, Kurten MO. Lymphatic dysfunction in conjunction with dysregulated hyperdunamic blood flow (The Hyperstomy Syndrome). Lymphology 1997; 30: 98-104.

107. Mayall, JC, ACDG Mayall: Standardization of methods of treatment of Lymphedema. Progress in Lymphology XI - Excerpta Medica (1988), 517.

108. Mayall, RC, ACDG Mayall, JC Mayall, J Freitas, MO Kurten: Lymphatic dysfunction in conjunction with dysregulated hyperdynamic blood flow (the hyperstomy syndrome). Lymphology 30, 2 (June 1997), 98-103.

109. Michelini S, Failla A, Paroni Sterbini GL, Micci A, Santoro A, Valle G. Limb phlebolymphedema: diagnostic non invasive approach and therapeutical implications. The EJLRP 1995; Vol. 5 n. 20: 103-8.

110. Michelini S, Campisi C, Cavezzi A, Boccardo F, Failla A, Moneta G. Epidemiologia del linfedema. Auxilia-Linfologia, 1998; n. 1: 22-25.

111. Michelini S, Campisi C, Failla A, Boccardo F. Proposal for stadiation of phlebolymphoedema. Europ J Lymphol Relat Probl 1995; 6(20): 1-14.

112. Nicolaides AN. Therapeutic outcome and quality of life in patients with chronic venous and lymphatic disorders. Editorial. Phlebolymphology n. 20: 2-3.

113. O'Brien BM, Hickey MJ, Hurley JV, Dvir E, Khazanchi RK, Pederson WC, Pribaz JJ. Microsurgical transfer of the freater omentum in the treatment of canine obstructive lymphoedema. Br J Plast Surg 1990 Jul; 43 (4): 440-6.

114. O'Brien BM, Mellow CG, Khazanchi RK, Dvir E, Kumar V, Pederson WC. Long-term results after microlymphaticovenous anastomoses for the treatment of obstructive lymphedema. Plast Reconstr Surg 1990 Apr; 85 (4): 562-72.

115. O'Brien BM, Sykes P, Threlfall GN, Browning FS. Microlymphaticovenous anastomoses for obstructive lymphedema. Plast Reconstr Surg 1977 Aug; 60(2). 197-211.

116. O'Brien B.: "Microlymphatic-venous and resectional surgery in obstructive lymphoedemas". World J Surg., 1979, 3, 3.

117. Olszewski W. Recurrent bacterial dermatolymphangioadenitis (DLA) is responsible for progression of lymphoedema. Lymphology 1996; 29 (Suppl): 331.

118. Olszewski W.: "Bacteriological Studies of skin, tissue fluid and lympho in filarial lymphedema". Lymphology 1994, 27 (Suppl), 345-348.

119. Olszewski W.: "Handbook of Microsurgery". CRC Press, Boca Raton, 1984.

120. Olszewski WL. The treatment of lymphedema of the extremities with microsurgical lympho-venous anastomoses. Int Angiol 1988 Oct-Dec; 7 (4): 312-21.

121. Olszewski WL. The treatment of lymphedema of the extremities with microsurgical lympho-venous anastomoses. Int Angiol 1988 Oct-Dec; 7 (4): 312-21.

122. Papendieck CM. Temas de Angiologia Pediatrica. Editorial Medica Panamericana, Buenos Aires, 1992.

123. Papendieck CM. The big angiodysplastic syndromes in pediatrics with the participation of the lymphatic system. Lymphology 1998; 31 (Suppl): 390-392.

124. Partsch H. Indirect lymphography in different kinds of leg oedema. Lymphology: Advances in Europe. Genova, Ecig, 1989: 95-9.

125. Pecking A.P. e Coll.: "Upper limb lymphedema's frequency in patients treated by conservative therapy in breast cancer". Lymphology 29 (Suppl): 293-296, 1996.

126. Pecking A.P., Cluzan R.V.: "Assessment of lymphatic function: 15 years experience using radionuclide methods". Lymphology 1994, 27 (Suppl), 301-304.

127. Pecking AP, Gougeon-Bertrand FJ, Floiras JL, Garbay JR, Banzet P, Roussé J. Lymphoscintigraphy. Overview of its use in the lymphatic system. Lymphology 1998; 31 (Suppl): 343-346.

128. Pissas A. Prevention of Secondary Lymphoedema. Proceedings of the International Congress of Phlebology, Corfù, Greece, 113, September 4-8, 1996.

129. Samaniego E.: "Progresos en Linfologia II". Madrid, Egraf, SA, 1991.

130. Servelle M, Noguès C. The chyliferous vessels. Paris: Expansion Scientifique Française, 1981.

131. Servelle M. La lymphangiectomie superficielle totale. Traitement chirurgical de l'éléphantiasis. Rev Chir 1947; 294.

132. Servelle, M: Pathologie Vasculaire. Masson et Cie, Paris 1975.

133. Stanton AW, Levick JR, Mortimer PS. Current puzzles presented by postmastectomy oedema (breast cancer related lymphoedema). Vasc Med 1996; 1 (3): 213-25.

134. Stewart FW, Treves N. Lymphangiosarcoma in postmastectomy lymphedema; a report of six cases in elephantiasis chirurgica. Cancer 1948; 1: 64.

135. Stratigos JD, Potouridon I, Katoulis AC, Hatziolov E, Christofidou E, Stratigos A, Hatzakis A, Stavrianeas NG. Classic Kaposi's sarcoma in Greece: a clinico-epidemiological profile. Int J Dermatol 1997 Oct; 36 (10): 735-40.

136. Suneson BL, Lindholm C, Hamrin E. Clinical incidence of lymphoedema in breast cancer patients in Jonkoping County, Sweden. Eur J Cancer Care (Engl) 1996 Mar; 5 (1): 7-12.

137. Thompson N. The surgical treatment of chronic lymphoedema of the extremities. Surg Clin North Am 1967; 47: 2.

138. Tosatti E. Lymphatique profonds et lymphoedèmes chroniques des membres. Paris, Masson, 1974.

139. Trévidic P., Marzelle J., Cormier J.M.: "Apport de la microchirurgie au traitement des lymphoedèmes". Editions Techniques - Encycl. Méd. Chir. (Paris-France), Techniques chirurgicales - Chirurgie vasculaire, 1994, F.a. 43-225, 3.

140. Vodder E. La méthode Vodder – Le drainage lymphatique manuel. Inst. For Lymph Drainage, DK-2880, Bagsvaer, 1969.

141. Werngren-Elgstrom M, Lidman D. Lymphoedema of the lower extremities after surgery and radiotherapy for cancer of the cervix. Scand J Plast Reconstr Surg Hand Surg 1994 Dec; 28 (4): 289-93.

142. Witte C., McNeill G., Witte M. et Al.: "Whole-body lymphangioscintigraphy: making the invisible easily visible". Progress in Lymphology XII, Elsevier Science Publishers B.V., 1989, 123.

143. Witte Ch L. Breast Cancer-An Overview. Lymphology 1994; 27S: 397-400.

144. Witte CL, Witte MH. Consensus and dogma. Lymphology 1998 Sep; 31(3): 98-100.

145. Witte MH et al. Lymphangiogenesis: mechanisms, significance and clinical implications. In: Goldberg ID, Rosen EM eds. Regulation of Angiogenesis. Basel / Switzerland: Birkhuser Verlag, 1996: 65-112.

146. Yamada Y. Studies on lymphatic venous anastomosis in lymphedema. Nagaya J Med Sci 1969; 32:1-21.

147. Zhu JK, Yu GZ, Liu JX, Pang SF, Lao ZG, Tang HY. Recent advances in microlymphatic surgery in China. Clin Orthop 1987 Feb; 215: 32-9.

THE EUROPEAN JOURNAL OF
lymphology
and related problems
VOLUME 12 • No. 40 • 2004

TRANSCUTANEOUS OXYGEN PARTIAL PRESSURE BEFORE AND AFTER MANUAL LYMPHATIC DRAINAGE IN PATIENTS WITH CHRONIC LYMPHEDEMA OF THE LIMBS

A. Reißhauer, A. Bischoff, K. Mathiske-Schmidt
Department of Physical Medicine and Rehabilitation, Charité University Hospital, Medical Faculty of the Humboldt University, Berlin, Germany

Address for correspondence:
Universitätsmedizin Berlin, Klinik für Physikalische Medizin und Rehabilitation, Charité Campus Mitte, Schumannstrabe 20/21, 10117 Berlin

SUMMARY

The aim of the present study was to investigate changes in transcutaneous oxygen partial pressure (pO_2) in patients with chronic lymphedema during a comprehensive treatment program including up to 10 days of manual lymphatic drainage combined with compressive bandaging and physical exercising. The clinical course of edema and the outcome of therapy were assessed by additional serial measurement of the volumes and circumferences of edematous and nonedematous limbs.
A positive immediate effect on the edematous limbs was seen in all age groups of patients during the daily treatment sessions. During the 10-day treatment course, there was an increase in transcutaneous pO_2 in the edematous limbs, which reached values comparable to those of healthy subjects at the end of treatment. The results presented here confirm that lymphedema impairs transcutaneous pO_2 and hence reduces the oxygen supply of the skin, thereby promoting the development of complications such as erysipelas and hyperkeratosis.

Key words: chronic lymphedema, transcutaneous oxygen partial pressure, manual lymphatic drainage, immediate effect, long-term effect

INTRODUCTION

Chronic lymphedema is characterized by the presence of abnormally large amounts of high-protein fluid in the interstitial spaces (Földi, Kubik 1989) (1). The lack of drainage of plasma proteins leads to reactive connective tissue proliferation with perivascular fibrosis and sclerosis, accumulation of fat, and damage to blood vessels and parenchymal cells induced by stasis of lymphatic flow (Talarico et al. 1991, Lotze, Richter 1989, Földi, Kubik 1989) (2, 3, 1). The resulting impairment of microcirculation and excessive metabolic burden of the tissue promotes the formation of radicals (Siems et al. 1999) (4). Connective tissue proliferation and radical formation reduce the oxygen supply to the skin, affecting in particular the subcutaneous layer in lymphedema patients. In addition, the excessive retention of fluids and proteins in lymphedema results in a longer diffusion pathway for oxygen and nutrients.
Published data (Wienert and Lentner 1993) (5) show that measurement of oxygen partial pressure (pO_2) allows for assessing the microcirculation of the skin and the oxygen content of the tissue. The measured values correlate with the vitality of the skin, which decreases with the pO_2 (Jünger et al. 1994) (6).
In the present study, we investigated changes in transcutaneous pO_2 in patients with chronic stage II lymphedema of the limbs of different origin during a comprehensive physical treatment program. A total of 6 edematous arms and 13 edematous legs were investigated and compared to the results in 22 normal controls.
The therapy of choice in chronic lymphedema is comprehensive physical therapy (Brunner, Frei-Fleischin 1993, Földi) (7, 1) comprising manual lymphatic drainage (MLD), compressive bandaging, and physical exercising. A course of MLD reduces edema size and the circumference of the affected limb and improves tissue consistency.
Assuming that the tissue alterations occurring secondary to chronic lymphedema change the oxygen supply of the tissue, we undertook the present study to show for the first time that there is an association between changes in pO_2 and changes of the tissue structure in chronic lymphedema. If such an association can be demonstrated, noninvasive measurement of transcutaneous pO_2 could be used for assessing lymphedema.
A further aim of our study was to evaluate the therapeutic efficacy of manual lymphatic drainage by means of the measured changes in pO_2.

MATERIAL AND METHODS

The study included 11 female and 3 male patients with chronic lymphedema of one or both limbs. The patients had a mean age of 54 years (range 34 to 76 years) and a mean BMI of 27.1 (± 3.9). Thirteen patients (92.8%) had stage II lymphedema and one patient had an artificial edema. Most patients (71.4%) had undergone MLD and compression therapy before.
The control group comprised 22 healthy, physically normal (BMI: 21.7 ± 2.6) individuals. These were 21 females and 1 male with a mean age of 34 years (range 21 to 56 years).
Normal blood pressure was an inclusion criterion for patients and controls. Exclusion criteria for both groups were venous insufficiency, peripheral arterial occlusive disease, congestive dermatitis, skin infections, status post radiotherapy, status post

venous surgery, malignant edema, BMI > 28, smoking, and thyroid dysfunction.
One patient dropped out during therapy due to erysipelas.
An additional exclusion criterion for the control group was the presence of lipedema or lymphedema.
Since transcutaneous pO_2 has been shown to change with age (Wienert and Lentner 1993), patients and controls were subdivided into 3 age groups (Table 1).

TABLE 1
AGE GROUPS AND NUMBERS OF PATIENTS AND CONTROLS PER GROUP

GROUP	AGE (YEARS)	NUMBER OF PATIENTS	NUMBER OF CONTROLS
1	20-29	n = 0	n = 12
2	30-49	n = 7	n = 6
3	> 50	n = 7	n = 4

Transcutaneous pO_2 measurement of the limbs was performed with the universal pO_2 meter MO 10.1 (Präcitronic, Dresden, Germany). This is a device for the electrochemical, polygraphic determination of pO_2 (Jaszcak 1991) (8) using a Clark electrode for noninvasive, transcutaneous measurement.
The Clark electrode is covered by a membrane permeable to oxygen and registers fluctuations in electrochemical potential through the reduction of oxygen at its cathode. Oxygen partial pressure is proportional to the flow of current, i.e., the measured value is proportional to the amount of oxygen molecules that diffuse from papillary capillary loops into the interstitial space and through the epidermis to the skin surface. The measured pO_2 values are given in kPa; the measuring accuracy is 1/10.
To optimize conditions, a 20-minute hyperemia period was induced in the measuring region by warming the skin to 45° Celsius with an adjustable heating element attached to the anode (Lehnert 1988) (9). An optimal electrode current was ensured by using distilled water as coupling medium between the epidermis and the membrane and preparing the skin by shaving and cleansing with 70% ethanol. These measures served to enable air-tight placement of the electrode.
The electrode membrane was kept in a steam-saturated atmosphere between measurements. Each time the instrument was put into operation, two-point calibration was performed (local partial oxygen pressure (barometer), partial oxygen pressure – zero value (zero solution)).
All measurements were performed under identical conditions at an ambient temperature of 22 ± 1°C with the subject in the supine position and his or her eyes closed.
To determine whether and at which time a therapy-induced change in pO_2 occurred during the 10-day course of MLD, pressure measurements were performed before and after each MLD.
The pO_2 measurements were compared with the clinical course of lymphedema, which was assessed by measuring the circumference of the affected limb at 5 defined sites (Table 2) and by optoelectric volume measurement. Circumference measurements were performed before and after the 1st, 5th, and 10th MLD.
The optoelectric volume measurements were performed as part of the pretherapeutic and posttherapeutic examinations (day 10) by means of a volumometer (Volometer, Bösl Medizintechnik);

TABLE 2
SITES FOR MEASURING CIRCUMFERENCE

SITE	LEG	ARM
1	at the level of the malleoli	wrist joint
2	15 cm above the lateral malleolus	10 cm above the wrist joint
3	30 cm above the lateral malleolus	15 cm above the wrist joint
4	10 cm above the lateral knee joint space	10 cm above the lateral epicondyle of humerus
5	20 cm above the lateral knee joint space	15 cm above the lateral epicondyle of humerus

accuracy of 1 ml, maximum measuring error ± 0.5%), which has proven effective in the diagnostic assessment and follow-up of lymphedema (Neumann, v.d. Broeck 1995) (10).
Statistical analysis was performed using nonparametric tests.

RESULTS

Transcutaneous pO_2 measurement in the control group showed no side differences, so that a mean value (= normal value) for all arms and all legs was calculated for each age group (Table 3).

TABLE 3
NORMAL VALUES OF OXYGEN PARTIAL PRESSURE IN THE CONTROL GROUP (KPA)

	AGE GROUP 1	AGE GROUP 2	AGE GROUP 3
Number of limbs	24	12	8
Arms	9.5 +/- 2.0	9.1 +/- 1.6	7.2 +/- 0.7
Legs	9.8 +/- 1.0	8.4 +/- 1.0	8.1 +/- 1.3

Comparison of the pretherapeutic pO_2 values in the patient group with the normal values of the controls demonstrated a significant difference for the edamatous upper and lower limbs in age group 3 (Diagram 1). The normal value for the upper limbs (n = 8 arms) in this age group was 7.2 ± 0.8 kPa compared to a pretherapeutic pO_2 of 5.8 ± 0.8 kPa in patients with edema of the upper limbs (n = 2 arms). The normal pO_2 value for the lower limbs in 4 controls (n = 8 legs) was 8.1 ± 1.3 kPa compared to a pretherapeutic pO_2 of 4.7 ± 3.2 kPa in the edematous lower limbs of 5 patients of this age group (n = 7 legs).
In age group 2, pO_2 in edematous limbs differed from the normal values of the control group but the difference was not significant. The pretherapeutic pO_2 values measured in the nonedematous limbs of the patients did not differ significantly from the normal values of the controls in the respective age groups.
The immediate effect of MLD was assessed by analyzing the transcutaneous pO_2 measured before and immediately after each treatment for the 3 age groups.
In age group 2, a series of 10 MLDs was performed on 3

Diagram 1
Comparison of normal oxygen partial pressure (pO_2) in healthy controls with pretherapeutic pO_2 in edematous limbs



Diagram 2
Pretherapeutic oxygen partial pressure in affected limbs before the 1st and 10th MLD

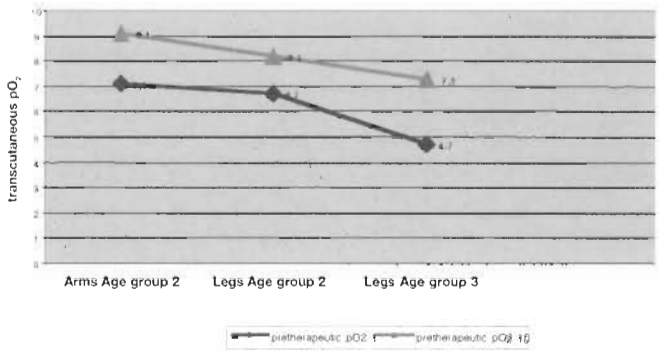

edematous arms. There was a beneficial immediate effect after each treatment session but there was no significant difference between the pretherapeutic and posttherapeutic pO_2. The mean difference between these values was 0.6 ± 0.3 kPa. The greatest difference in pO_2 was seen after the 7th MLD (maximum of 1.5 ± 0.9 kPa).

The edematous legs in age group 2 (n = 6) showed a positive immediate response to treatment but the effect was again not significant. The mean difference in trancutaneous pO_2 was 0.9 ± 0.3 kPa. The difference between the pretherapeutic and posttherapeutic pO_2 was greatest after the 9th MLD (maximum of 1.4 ± 0.8 kPa).

Age group 3 comprised 2 patients with chronic edema of the upper limbs (n = 2) who underwent a course of 6 MLDs. There was no positive immediate effect.

The edematous lower limbs (n = 7) in age group 3 showed a positive immediate effect but without a significant difference in pO_2 before and after completion of the course of treatment. Comparison of the posttherapeutic transcutaneous pO_2 values measured in the patients with the normal values determined in the controls according to age group and affected limb revealed nearly normal values for the upper limbs in age group 2. The transcutaneous pO_2 at the end of therapy was 10.0 ± 1.6 kPa compared to 9.1 ± 1.6 kPa in the controls (Diagram 2). The difference was no longer significant. There was likewise no significant difference for the lower edematous limbs in age group 2 between the normal pO_2 value (8.4 ± 1.0 kPa, n = 12) and the posttherapeutic value (9.0 ± 2.1 kPa) in the patient group (n = 6). In age group 3 the transcutaneous pO_2 of the lower edematous limbs at the end of therapy (8.0 ± 2.2 kPa) was close to the normal value of the controls (8.1 ± 1.3 kPa). The difference was not significant. The posttherapeutic pO_2 for the lower edematous limbs in age group 3 was 6.3 ± 0.6 kPa compared to 7.2 ± 0.7 kPa in the controls. There was no significant change (Table 4).

DISCUSSION AND SUMMARY

The study presented here investigated changes in transcutaneous oxygen partial pressure in patients with chronic lymphedema of

TABLE 4

		MEAN OXYGEN PARTIAL PRESSURE [KPA]							
		CONTROL GROUP		PATIENT GROUP					
				EDEMATOUS SIDE			NONEDEMATOUS SIDE		
AGE GROUP	LIMB	NO. OF LIMBS	NORMAL PO_2	NO. OF LIMBS	PRETHERA-PEUTIC PO_2	POSTTHERA-PEUTIC PO_2	NO. OF LIMBS	PRETHERA-PEUTIC PO_2	POSTTHERA-PEUTIC PO_2
2	arm	12	9.1 +/- 1.6	3	7.1 +/- 0.5	10.0 +/- 1.6	1	7.4	9.7
2	leg	12	8.4 +/- 1.0	6	6.7 +/- 1.5	9.0 +/- 2.1	2	6.6 +/- 0.7	6.0 +/- 1.2
3	arm	8	7.2 +/- 0.7	2	5.8 +/- 0.8	6.3 +/- 0.6	2	8.1 +/- 1.3	7.6 +/- 1.1
3	leg	8	8.1 +/- 1.3	7	4.7 +/- 3.2	8.0 +/- 2.2	3	8.8 +/- 1.8	9.1 +/- 1.8

the arms and legs of different pathogenesis during a comprehensive physical treatment program. The study included 14 patients with chronic, partly bilateral, lymphedema of the limbs affecting the arms in 5 cases and the legs in 9 patients. Twenty-two healthy volunteers were examined to determine normal values of transcutaneous pO_2 in three different age groups. Additional measurements of the volumes and circumferences of the edematous and nonedematous limbs served to evaluate the clinical course of edema and the effect of therapy.
In patients over 50 years of age transcutaneous pO_2 in affected limbs was significantly lower than in the healthy controls of the same age group. The difference was up to 40%. This observation suggests that the accumulation of interstitial fluid associated with chronic lymphedema results in a longer diffusion pathway for oxygen.
The measurements confirm that lymphedema has adverse effects on transcutaneous pO_2 and is associated with a reduced oxygen supply of the skin. This situation promotes the development of complications and provides an additional explanation for known complications such as streptococcal infection and myocosis of the skin and/or nails.
Daily MLD tended to have positive immediate effects on the pO_2 of the affected limb in all age groups. The demonstration of such immediate benefits suggests that the diffusion pathway for transcutaneous pO_2 can be shortened by enhancing lymphatic outflow through MLD. This immediate effect occasionally persisted for up to 2 days.
An increase in the transcutaneous pO_2 of the edematous limbs was observed in the course of treatment. Significant differences in transcutaneous pO_2 before and after a 10-day course of daily MLD were seen for the legs in age group 3 and for edema of the upper and lower limbs in age group 2. In these instances, the pO_2 values after completion of therapy reached the normal values of the controls (Diagram 3).

Diagram 3
Oxygen partial pressure in the course of therapy

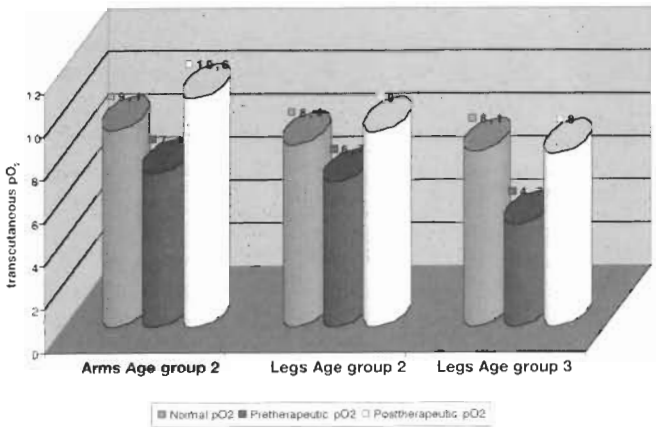

The patients with lymphedema of the arms in age group 3 underwent a course of 6 MLDs, which likewise increased transcutaneous pO_2, but the increase was not significant.
In this group the pO_2 values at the end of therapy did not reach the normal values of the controls, indicating that a 6-day course of therapy is insufficient to normalize pO_2 in chronic lymphedema.

Clinical evaluation of the outcome of therapy showed a decrease in the volumes and circumferences of the edematous limbs but the difference to the pretherapeutic values was significant only for the legs in age groups 2 and 3.
In addition, there was an improvement in tissue consistency.
Notwithstanding the little number of patients for each age group, we can conclude, however, that the results of this preliminary study point out that chronic lymphedema is associated with changes in oxygen partial pressure. This observation provides an additional explanation for secondary tissue changes associated with lymphedema. Moreover, the results show that measurement of transcutaneous oxygen partial pressure using the procedure presented here can serve as an additional noninvasive tool for the assessment of lymphedema.

REFERENCES

1. *Földi M, Kubik S: Lehrbuch der Lymphologie. Gustav Fischer Verlag Stuttgart, New York; 1989.*

2. *Talarico F et al.: Fibrosclerotic lymphedema: pathophysiology and therapy. Lymphol 1991; 24 (1): 11-15.*

3. *Lotze W, Richter P: Sekundäre Lymphödeme bei gynäkologischen Malignomen. Zentralbl Gynäkol 1989; 111 (2): 92-98.*

4. *Siems WG et al.: Therapieoptimierung beim chronischen Lymphödem chirurgisch behandelter Tumorpatienten durch Natriumselenit. Dtsch Ztschr Onkol 1994; 26: 128-132.*

5. *Wienert V, Lentner A: Transcutaneous oxygen pressure measurement: Methods, implementation and possible applications. In: Frosch PJ, Klingman AM (eds): Noninvasive Methods for the Quantification of Skin Functions. Springer Verlag, Berlin-Heidelberg, 1993; 280-290.*

6. *Jünger M et al.: Bedeutung der kutanen Mikroangiographie für die Entstehung von Stauungsdermatosen bei chronischer Veneninsuffizienz (CV). Wien Med Wschr 1994; 144: 206-210.*

7. *Brunner U, Frei-Fleischin C: Gegenwärtiger Stand der kombinierten physikalischen Entstauungstherapie beim primären und sekundären Lymphödem der Beine. VASA 1993; 22 (1): 8-14.*

8. *Jaszcak P: Skin oxygen tension, skin oxygen consumption and skin blood flow measured by tc-pO_2 electrode. Acta Physiol Scand (Suppl 603) 1991 ; 143: 53 – 57.*

9. *Lehnert W: Ulcus cruris venosum – Komplexe Therapie. Habilitation Thesis, Charité, Medical Faculty of the Humboldt-Universität zu Berlin, 1988; 67-97.*

10. *Neumann HAM, van den Broek MJRT: A comparative clinical trial of graduated compression stockings and O-(ß-hydroxyethyl)-rutosides (HR) in the treatment of patients with chronic venous insufficiency. Lymphol 1995; 19: 8-11.*

THE EUROPEAN JOURNAL OF
lymphology
and related problems
VOLUME 12 • No. 40 • 2004
INDEXED IN EXCERPTA MEDICA

LYMPHATIC LESIONS AND VIBROACOUSTIC DISEASE

José Martins dos Santos, MD, PhD (1), Nuno R. Grande, MD, PhD (2), Nuno A. Castelo Branco, MD (3), Carlos Zagalo, MD, PhD (1), Pedro Oliveira, DDS (1), Mariana Alves-Pereira, MS (3)

(1) Health Sciences Institute - Lisbon
(2) Abel Salazar Institute for Biomedical Sciences, University of Porto - Porto
(3) Center for Human Performance - Lisbon

Correspondence to:
José Martins dos Santos
Instituto Superior de Ciências da Saúde - Sul
Quinta da Granja - Monte de Caparica
2829-511 Caparica, Portugal
Fax.: 351212946800

ABSTRACT

Introduction. *Long-term (years) exposure to low frequency noise (LFN) (≤ 500 Hz, including infrasound) can lead to the development of vibroacoustic disease (VAD). In animal models, oedema is an immediate and sustained response to LFN exposure.* Goal. *To investigate possible a) alterations of lymphatic morphology, and b) lesions of the lymphatic network in LFN-exposed rodents.* Methods. *Twenty rats were exposed to LFN (8 hrs/day, 5 day/week, weekends in silence), and 10 rats were kept in equal conditions but in silence. After a cumulative exposure 1576 hours, animals were sacrificed, and fragments of femoral artery and vein and femoral lymphatics from both hindlimbs were collected for histological examination.* Results. *Lymphatic walls are greatly thickened with numerous small lymphatics exhibiting severe lumen dilation. Disruption of the valvular apparatus is also identifiable.* Discussion. *Changes in lymphatic morphology and disruption of lymphatic valvular apparatus in LFN-exposed rodents are sequelae of the organism's LFN-induced response.*

Keywords: Vibroacoustic disease; Low frequency noise; Lymphatics

1. INTRODUCTION

Low frequency noise (LFN) (≤ 500 Hz, including infrasound) is a ubiquitous agent of disease that is not assessed during routine noise evaluations, because no legislation exists concerning LFN [3]. Although sources of LFN exist outside the workplace, particularly in leisurely activities and urban residential areas, the foremost concern has been for the professionals who must remain within LFN environments due to their job descriptions.
The biological effects of LFN have been under investigation by researchers at the Center for Human Performance since 1980 [7]. As a result, studies have identified vibroacoustic disease (VAD) as a whole-body pathology, caused by long-term (years) exposure to LFN, and fundamentally characterized by an abnormal proliferation of extra-cellular matrices [9, 11]. VAD has been diagnosed among aircraft technicians [19], military [14] and commercial [5] pilots and aircrews, in a civilian population exposed to environmental LFN [24] and in several individuals who were unsuspectingly exposed to LFN [13].
In humans, proliferation of the extra-cellular matrix is most evident in the cardiovascular structures, particularly the pericardium [14, 12, 15]. This was first identified in 1987, during the autopsy of a deceased VAD patients in 1987 [8]. All blood vessel walls were thickened, with consequent decrease in lumen size. However, instead of the classical atherosclerotic lesions, there was a continuous thickening, blanketing the intima. Normal pericardial thickening is <0.5 mm, while in this deceased VAD patient it was 2.8 mm [8]. Subsequent echocardiography studies confirmed the existence of thickened pericardia in all LFN-exposed individuals examined [19, 5, 24, 4]. Light and electron microscopy revealed the formation of a new layer of loose tissue, on par with extraordinary micrographic images of cellular death, apoptotic and otherwise [14, 12, 15]. Today, pericardial thickening in the absence of an inflammatory process and with no diastolic dysfunction, is the hallmark of VAD [17].
The carotid arteries are also abnormally thickened in VAD patients [1, 2]. In some cases, vascular surgery was conducted, and fragments revealed intense fibrosis with a very evident elastic component. Vascular neoformations were also observed, including some very small lymphatics. Curiously, in most cases, carotid thickening is asymmetrical, and observations have suggested that the side where the carotid artery is most thick corresponds to the side that is usually closer to the LFN source [1, 6]. Thickening of vascular structures has since been reproduced in LFN-exposed rodents [21].
In animal models, oedema was observed to be an immediate and sustained effect of LFN. The tracheal epithelium of small rodents after 6 hours of LFN exposure exhibited exuberant oedema [16]. In other studies, the presence of oedema interfered with imaging possibilities, and so LFN-exposed animals began to be sacrificed after spending 1 week in silence. In this case, electron microscopy imaging allowed for a more detailed investigation into the behaviour of cellular populations [10].

Goal

To investigate, in LFN-exposed rodents, possible a) alterations of lymphatic morphology, and b) lesions of the lymphatic network.

2 – MATERIAL AND METHODS

Noise Exposure

A sound signal was generated by an analogue noise generator, amplified and frequency filtered. Fig. 1 shows the overall linear and A-weighted noise levels, as well as the spectral analysis of the excitation signal collected at the position near the rat test group inside the chamber. This noise was analysed by a digital real time analyser (B&K 2144). The acoustic energy was highly concentrated in the lower frequency bands due to the influence of the low-pass filter. In the frequency bands ranging from 50-500 Hz the noise levels were larger than 90dB. The overall levels were registered above 109dB, with the A-weighted levels at around 98dB (A).

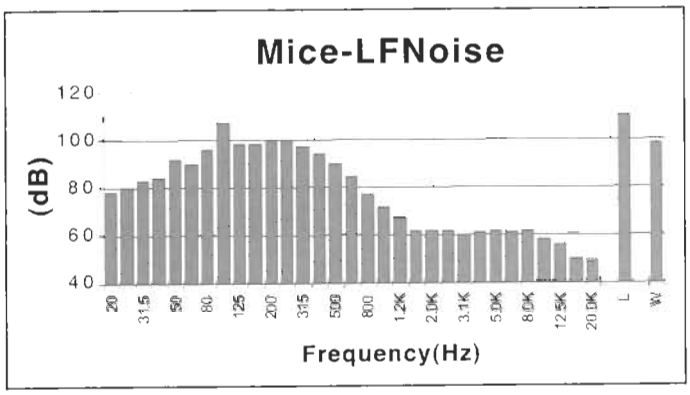

Figure 1. *Linear (L) and A-weighted (W) noise levels and spectral analysis to which the rat populations were exposed.*

Animals

Thirty male, adult, Wistar rats were used as the study group. All animals were obtained from a local breeder (Gulbenkian Institute of Science, Oeiras, Portugal), and were treated in accordance with the European Community Ethics Committee guidelines and regulations for the use of experimental animals (86/609/CE), as well as with Portuguese legislation for the same purpose. They were fed standard rat food and had unrestrained access to water. Twenty rats were exposed to LFN in an occupationally simulated schedule: 8 hours/day, 5 day/week, and weekends in silence. The remaining 10 rats were kept in identical conditions but in silence.

Experimental Protocol

The animals were sacrificed after 1576 hours of cumulative LFN exposure. The rats were anesthesized with an intravenous injection of ketamine (Ketalar, Parke-Davis Co., Barcelona, Spain; 4.0-8.0 mg/Kg of weight). The abdominal aorta was cut to exsanguinate, and the vascular system was washed with saline at 37 °C before a perfusion fixation with 10% buffered formaline. Fragments of femoral artery and vein and femoral lymphatics from both hind limbs were collected. Care was taken to include supporting muscle, in order to prevent "shrinking" of the vessel, in accordance with the guidelines of the American Heart Association [23]. The fragments were fixed in a 10% buffered formaline, sectioned and prepared for histological observation by standard methods. The sections were stained with hematoxylin-eosin and trichrome solution.

3. RESULTS

In the LFN–exposed specimens the femoral lymphatics showed histologic lesions in 70% of the cases.

Lymphatic walls exhibited an abnormal thickness in exposed specimens, due to fibrosis of the wall (Fig. 2). Severe dilation of lymphatic lumens was also identifiable, and disruptions of the valvular apparatus were evident (Figs. 3, 4). A proliferation of small lymphatics accompanied the rich vascular neo-formation, however, this was not associated with any cellular infiltration, i.e., no inflammatory process was involved. Small and medium arteries and veins were ectasic and congested, and walls were also thickened.

In the control group, lymphatics, arteries and veins appeared normal.

4. DISCUSSION

These findings were not reported before.

There is a direct or indirect action of LFN and vibration on the blood vessel walls that causes, in small blood vessels an increase in permeability and the proliferation of the intimal layer, with the

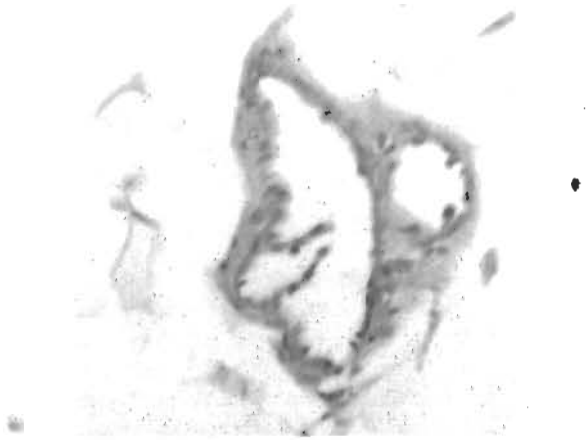

Figure 2. *Femoral lymphatic (hematoxylin-eosin x 400). Disruption of the valvular apparatus with dilation.*

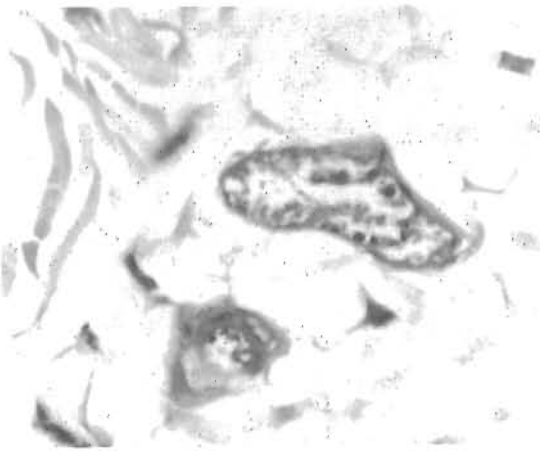

Figure 3. *Femoral lymphatic (hematoxylin-eosin x 400) Disruption of the valvular apparatus.*

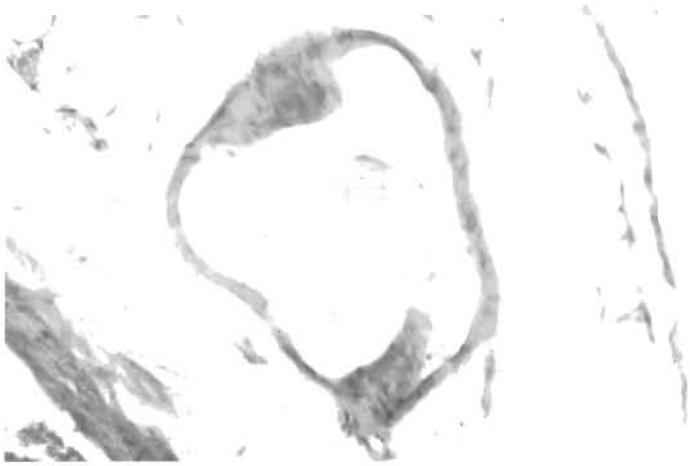

Figure 4. *Femoral lymphatic (hematoxylin-eosin x 200). Thickening of the lymphatic vessel wall and marked dilation.*

appearance of a fibrocellular thickening [18]. Repeated or chronic endothelial injury caused by local vibration can be the responsible mechanism for this finding [22].

It can not be entirely surprising to find these changes in the lymphatic vessels, given that it was already known that the consequences of LFN exposure are oedema and cell death, in the absence of any inflammatory process.

Generalised oedema usually leads to vascular stasis, which in turn, can lead to stasis of the lymphatic vessels with lumen dilation.

Ultimately, lymphatic stasis causes ectasia and disruption of the valvular apparatus. In a previous animal study, where stasis was achieved by paralysing the limbs, a similar pattern of lymphatic vessel alterations, together with increased tortuosity of the lymphatic tree, was part of the general vascular response [20]. Nevertheless, for the reasons pointed out above, valvular disruption caused by the direct impact of the acoustic phenomena on the living tissue cannot be discarded.

The death of cells, especially mechanical death, gives rise to an enormous amount of debris, which easily explains the need to develop drainage mechanisms. However, similarly to other hollow organs, which are targeted by LFN (blood vessels, lung, kidney, bladder, intestine), lymphatic vessel walls increase in thickness. Simultaneously, due to the LFN-induced haemodynamic stasis, lymphatics become ectasic, and ultimately valvular disruption becomes apparent.

LFN-induced vascular proliferation, including the lymphatics, has a chronic and progressive nature, and raises important issues that need to be confronted by the medical community at large. The long-term consequences can lead to severe vascular lesions, and in most cases, the real etiological factor is never identified.

5. ACKNOWLEDGEMENTS

The authors thank Emanuel Monteiro (ICBAS) and Carlos Lopes (CIMO) for all their assistance. The authors also thank the Portuguese Air Force Occupational Medicine Research Center for all animal facilities, and the Ministry of Defense for funding.

6. REFERENCES

1. Albuquerque e Sousa J., Dinis da Gama A., Macedo M.V., Cassio I., Castelo Branco N.A.A. (1991) Carotid angiodynographic studies in individuals occupationally exposed to noise and vibration. Aviat Space Environ Med 62: 134.

2. Albuquerque e Sousa J., Martinho Pimenta A.J.F., Castelo Branco N.A.A. (1995) Three cases of the vibroacoustic syndrome with significant carotid stenosis. Aviat Space Environ Med 66: 494.

3. Alves-Pereira M. (1999) Extra-aural noise induced pathology. A review and commentary. Aviat Space Environ Med 70 (3, Suppl): A7.

4. Araujo A., Ribeiro C.S., Correia M.J.F., Pais F., Castelo Branco N.A.A. (1989) Echocardiographic appearances in patients with the Whole-Body Noise and Vibration Disease. MEDICEF-Direct Information 2: 101.

5. Araujo A., Pais F., Lopo Tuna J.M.C., Alves-Pereira M., Castelo Branco N.A.A. (2001) Echocardiography in noise-exposed flight crew. Internoise 2001, The Hague, Holland: 1007.

6. Carmo G., Albuquerque e Sousa J., Dinis da Gama A., Castelo Branco N.A.A. (1992) Carotid angiodynographic studies in helicopter pilots. Aviat Space Environ Med 63: 385.

7. Castelo Branco N.A.A. (1983) Doença das vibrações [Vibration Disease]. Rev Port Med Mil 31 (Pt 4): 134.

8. Castelo Branco, N.A.A. (1999) A unique case of vibroacoustic disease: A tribute to an extraordinary patient. Aviat Space Environ Med 70 (3, Suppl): A27.

9. Castelo Branco N.A.A. (1999) The clinical stages of vibroacoustic disease. Aviat Space Environ Med 70 (3, Suppl): A32.

10. Castelo Branco N.A.A. (2001) The respiratory system as a target of low frequency noise. Reports on human and animal models. Proc. 8th ICSV, Hong Kong, P.R. China: 1501.

11. Castelo Branco N.A.A., Rodriguez Lopez E. (1991) The vibroacoustic disease – An emerging pathology. Aviat Space Environ Med 70 (3, Suppl): A1.

12. Castelo Branco N.A.A., Águas A.P., Sousa Pereira A., Monteiro E., Fragata J., Tavares F., Grande N.R. (1999) The human pericardium in vibroacoustic disease. Aviat Space Environ Med 70 (3, Suppl): A54.

13. Castelo Branco N.A.A., Rodriguez Lopez E., Alves-Pereira M., Jones D.R. (1999) Vibroacoustic disease: some forensic aspects. Aviat Space Environ Med 70 (3, Suppl): A145.

14. Castelo Branco N.A.A., Monteiro E., Alves-Pereira M., Águas A.P., Sousa Pereira A., Grande N.R. (2001) Morphological changes in the pericardia of military helicopter pilots. Proc. Microscopy Barcelona: 318.

15. Castelo Branco N.A.A., Águas A.P., Sousa Pereira A., Monteiro E., Fragata J., Grande N.R. (2001) The pericardium in noise-exposed individuals. Internoise 2001, The Hague, Holland: 1003.

16. *Gomes-Ferreira P., Mirones J., Sousa Pereira A., Águas A.P., Monteiro E., Grande N.R., Castelo Branco N.A.A. (2001) Prolonged and continuous low frequency noise stress on the tracheae of Wistar rats. Aviat Space Environ Med 72(3): 253.*

17. *Holt B.D. (2000) The pericardium. In: Furster V., Wayne Alexander R., Alexander F., eds.* Hurst's The Heart. *10th ed. New York: McGraw-Hill Professional Publishing: 2061.*

18. *Inaba R., Furuno T., Okada A. (1988) Effects of low- and high-frequency local vibration on the ocurrence of intimal thickening of the peripheral arteries of rats. Scand J Work Environ Health 14: 312.*

19. *Marciniak W., Rodriguez E., Olszowska K., Atkov O., Botvin I., Araujo A., Pais F., Soares Ribeiro C., Bordalo e Sá A., Loureiro J., Prazeres de Sá E., Ferreira D., Castelo Branco M.S.N., Castelo Branco N.A.A. (1999) Echocardiographic evaluation in 485 aeronautical workers exposed to different noise environments. Aviat Space Environ Med 70 (3, Suppl): A46.*

20. *Martins dos Santos J., Grande N.R. (2000) Vascular lesions of muscular atrophy. Eur J Lymphol 31(8): 41.*

21. *Martins dos Santos J., Grande N.R., Castelo Branco N.A.A., Zagalo C., Oliveira P. (2001) Vascular lesions and vibroacoustic disease. Eur J Anat 6(1): 17.*

22. *Okada A., Inaba R., Furuno T. (1987) Usefulness of blood parameters, especially viscosity, for the diagnosis and elucidation of pathogenic mechanisms of the hand-arm vibration syndrome. Scand J Work Environ Health 13: 358.*

23. *Stary H.C., Blankenhorn D.H., Chandler A.B. (1992) A definition of the intima of human arteries and of its atherosclerosis-prone regions. Circulation 85 (1): 391.*

24. *Torres R., Tirado G., Roman A., Ramirez R., Colon H., Araujo A., Pais F., Marciniak W., Nóbrega J., Bordalo e Sá A., Lopo Tuna J.M.C., Castelo Branco M.S.N., Alves-Pereira M., Castelo Branco N.A.A. (2001) Vibroacoustic disease induced by long-term exposure to sonic booms. Internoise, The Hague, Holland: 1095.*

THE EUROPEAN JOURNAL OF lymphology and related problems
VOLUME 12 ▪ No. 40 ▪ 2004

FOCAL DERMAL HYPOPLASIA (GOLTZ SYNDROME) ASSOCIATED WITH LYMPHEDEMA

Isabel Forner-Cordero (1), Carmen Grao-Castellote (2), Pilar Morant-Guillén (1), Pilar Rel-Monzó (3)

(1) Medical Doctor, Physical Medicine and Rehabilitation Specialist. Lymphedema Unit. Universitary Hospital La Fe. Valencia, Spain
(2) Medical Doctor, Physical Medicine and Rehabilitation Resident. Universitary Hospital La Fe. Valencia, Spain
(3) Physiotherapist. Lymphedema Unit. Universitary Hospital La Fe. Valencia, Spain

Correspondence:
Isabel Forner-Cordero
C/ Andrés Mancebo 36, 12
46023 Valencia, Spain
iforner@saludalia.com
Telephone number Work: (Internacional Spain code) + 96 386 27 78
Home Telephone: (Internacional Spain code) + 963 37 44 75

ABSTRACT

Focal Dermal Hypoplasia (Goltz syndrome) was diagnosed in a 4 years-old girl with pathological long bones fractures due to giant cell tumours. She presented a lower limb lymphedema that is a rare feature, never previously reported in the Goltz syndrome literature. She was treated with Complex Physical Decongestive Therapy with excellent results.

Key-words: Focal Dermal Hypoplasia, Goltz syndrome, Lymphedema, Complex Physical Therapy, Giant cell tumours.

CASE REPORT

A 6-years-old girl with a severe lymphedema in her left lower limb was attended at our Lymphedema Clinic. She has been diagnosed of a Goltz syndrome 2 years ago. She presented since birth **cutaneous anomalies**: dermal hypoplasia, areas of cutis aplasia congenita on the face and scalp, hyperpigmented spots in abdomen and limbs; **ocular anomalies**: hydrocystomas near the eyes, and **dental anomalies**; growth retardation and hypercalcemia. Proteinemia was within normal levels.
The first manifestation leading to the diagnosis was a pathological fracture of the humerus neck that had been caused by a giant cell tumor. Skeletal radiologic study revealed metaphyseal tumors in many long bones: tibia, fibula, femur, and she underwent surgery to extract a mandibular giant cell granuloma (Figure 1).
Her mother noticed the onset of lymphedema of the left lower limb 2 years ago without any identified cause, although this oedema worsened as a consequence of a femoral fracture (Figure 2). She did not receive any specific advice or diagnosis or treatment until she arrived to our hospital.

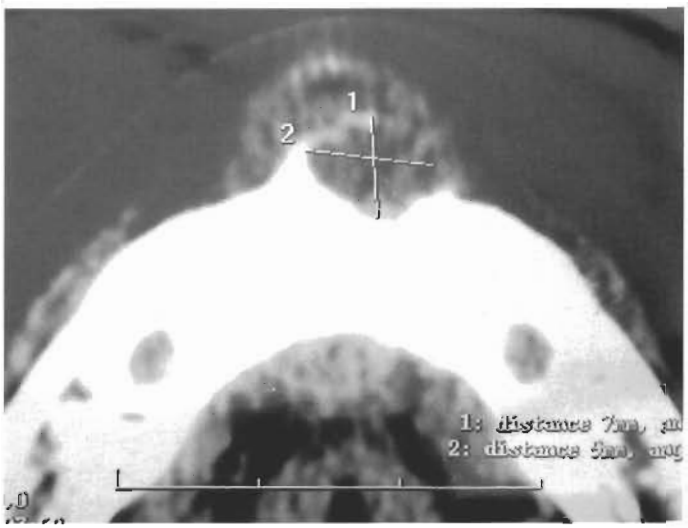

Figure 1. *Mandibular tumour.*

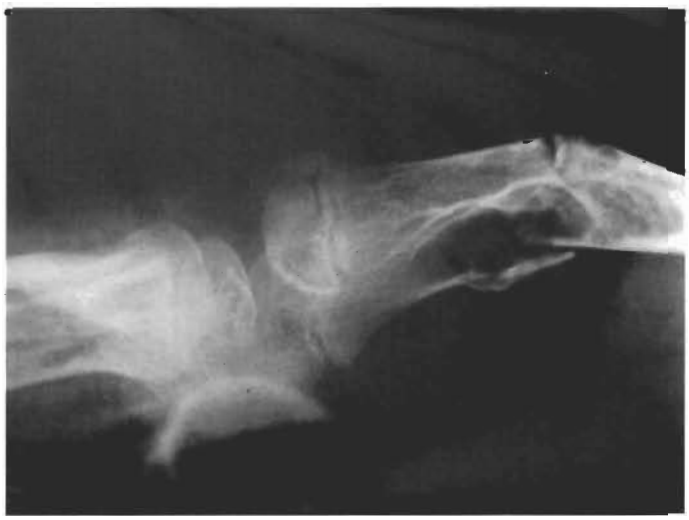

Figure 2. *Pathological femoral fracture.*

The patient presented lymphedema of a 2 years evolution, affecting severely the limb from the foot to the hip. She had 3 episodes of erysipelas-lymphangitis that needed hospitalisation. Complementary exams: Doppler ultrasonography was normal and abdominal CT scan revealed no abdominal or pelvic tumour or

adenopaties causing obstruction of the lymph system.
At examination, a measurement in centimetres (cm) of the perimeter of the lower limb was made at the foot, ankle and every 4 cm above (C1 to Cn). The initial exam showed a difference until 12 cm between both limbs at ankle point and 4 cm above.
The volume calculated with the Kuhnke formula, was 3125 ml for the left lower limb, and 1717 ml for the right limb. These data are impressing if we take into account that the weight of the patient was only 17.2 Kg and her height was 103.5 cm. (Figures 3, 4 and 5).

Kuhnke method:

$$Volume = \frac{C1^2 + C2^2 + Cn^2}{\pi}$$

TREATMENT AND RESULTS

She was treated with Complex Physical Decongestive Therapy during 4 weeks: 21 sessions of Manual Lymphatic Drainage, Multicompartimental pressotherapy, followed by multilayer bandages and kynesitherapy. The final results can be seen in pictures 6, 7 and 8.
The volume of the left lower limb after the treatment was 1954 ml, so the percentage of volume reduction was 37,46% (Graphic 1).

Volume reduction =

$$\frac{\text{Volume pre-treatment} - \text{Volume post- treatment}}{\text{Volume pre-treatment}} \times 100$$

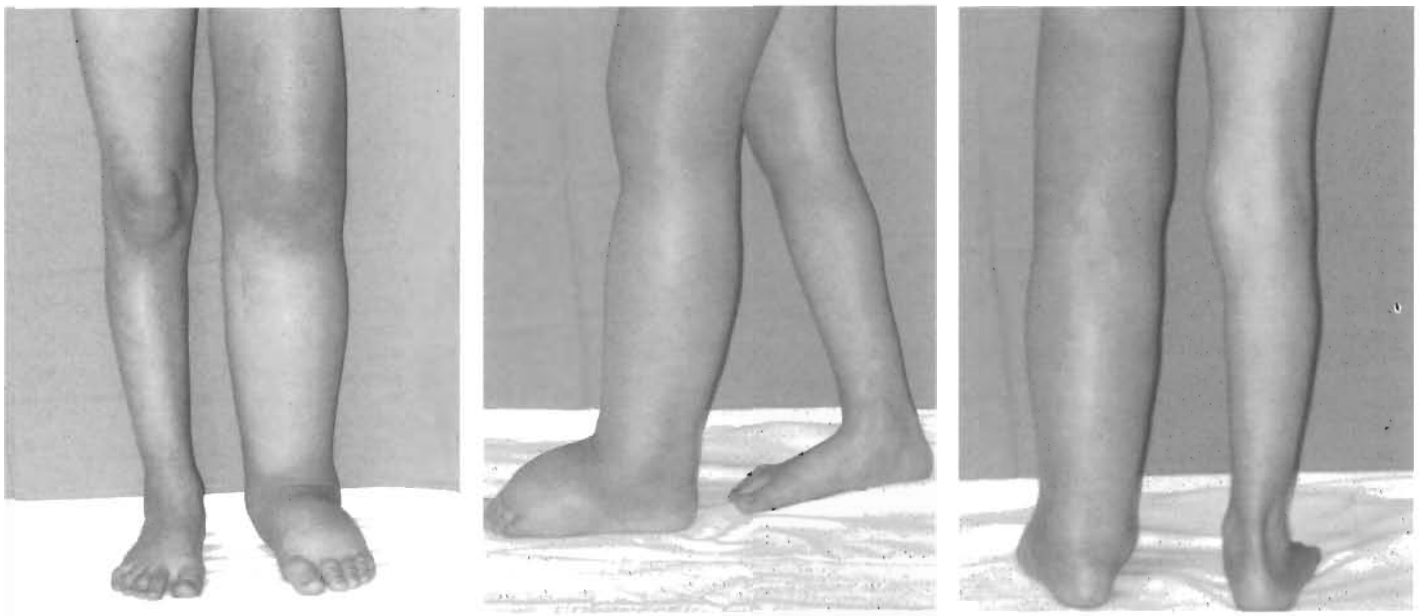

Figures 3, 4 and 5. *Lymphedema before treatment.*

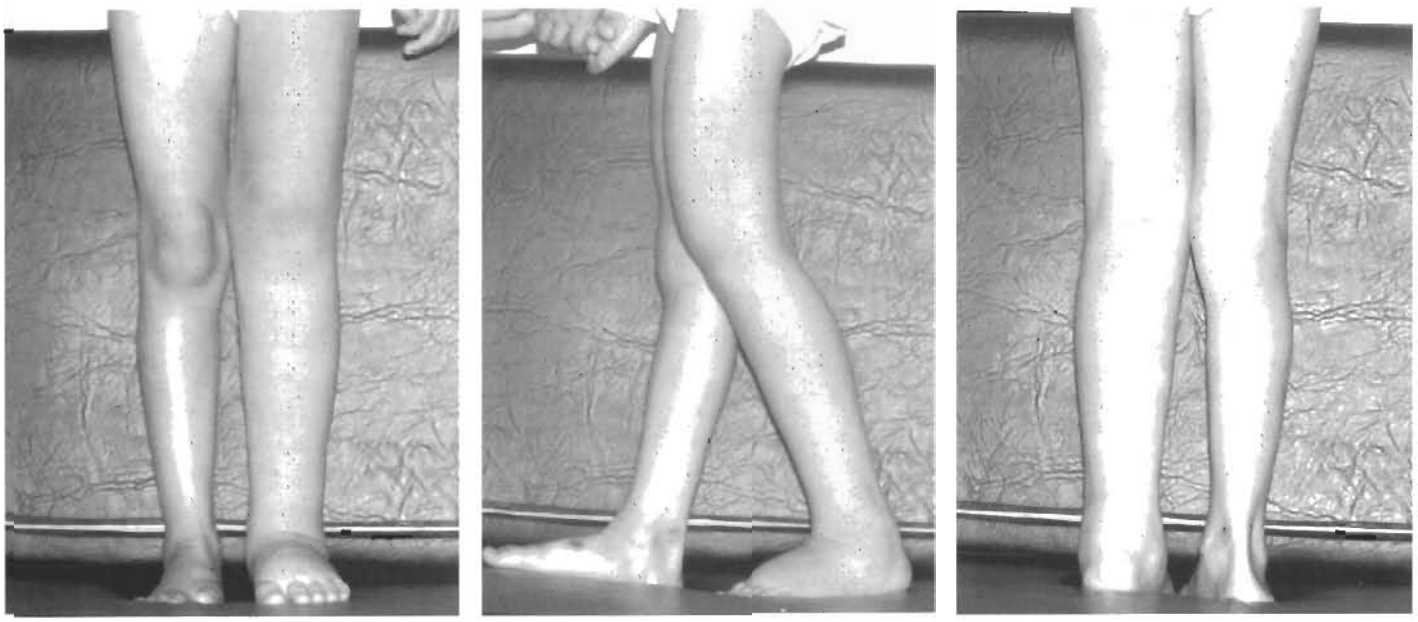

Figures 6, 7 and 8. *After Complex Physical Therapy.*

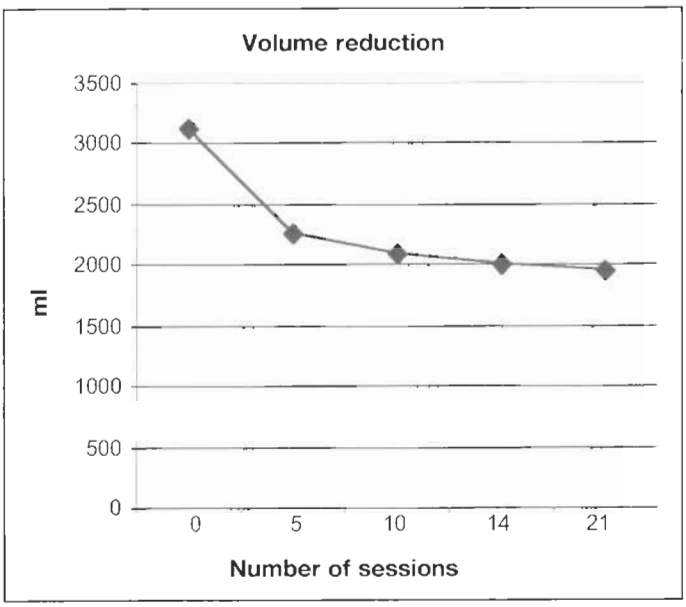

Graphic 1. *Volume reduction with Complex Physical Therapy.*

After the treatment, the reduction of the oedema was 83.1% out of the initial difference between limbs.
The girl is wearing a Medi® stocking during the day and carrying out daily exercises and hygiene precautions for lymphedema, and is now stabilized.

DISCUSSION

Focal dermal hypoplasia (Goltz Syndrome) is a rare disorder that affects tissues and organs of mesoectodermal origin (1, 2). The anomalies are present in the mucous membranes or skin, musculoskeletal system, ocular and oral structures and central nervous system. More than 200 cases (1) have been reported, most of them in female patients. It has been described in some males too (3, 4).
Clinical signs (1, 5, 6, 7, 8): Clinical findings vary from cutaneous atrophy to the involvement of many organs, and from mild to severe affectation.
Typical cutaneous abnormalities include atrophic macules, telangiectasia, and hypo or hyperpigmented lesions that follow linear and asymmetrical distribution (Blaschko's lines). The reduction in the thickness of the dermis leads to the "fat herniation", the second common lesion in Goltz syndrome. The skeletal manifestations are described in 80% of the patients, being the most frequent findings: digital anomalies as syndactyly, polydactyly and absence deformities; scoliosis and asymmetries in trunk and face; and osteopathia striata, none of them were found in our patient. Omim database (7) reports that Gorlin pointed out the occurrence of giant cell tumors of bone in this disorder, as other authors (1, 9), and this was the first manifestation in our case. Oral abnormalities in 60% of the cases include dental hypoplasia and enamel alteration, oral papillomas... etc. Ocular anomalies are present in 40%: coloboma of iris, strabismus, and microphthalmia... Mental retardation can often be observed in different degrees of severity. Other clinical disorders have been described as short stature (10) as our case, congenital cardiopaty, deafness, dystrophic nails, kidney abnormalities...
The lymphatic cells derive from mesoderm (11, 12, 13). The lymphatic system begins to develop at the end of the sixth week (11) of gestation, similarly to the vascular system and connects with venous system. Primary lymphedema results from the dilatation of primitive lymphatic vessels or lymphatic hypoplasia. In the literature consulted of Goltz syndrome (1, 4, 5, 8, 10, 14), we did not find any previously reported case with lymphedema. Only dermal oedema is described in a case of focal dermal hypoplasia with an initial inflammatory phase (15), and a ring constriction with distal swelling in a new born with focal dermal hypoplasia (16).
Lymphedema is an abnormal fluid accumulation due to primary dysfunction of the lymphatic system (hypo or hyperplasia), or secondary to obstruction or malignant infiltration. The secondary cause of lymphedema was discarded by complementary exams, and it is known that a fracture can be the onset of a silent disease. The management of lymphedema consists in two stages; the first one is an intensive phase to reduce volume, by means of the Complex Physical Decongestion Therapy (17), and a second phase to maintain the improvement. The COMPLEX PHYSICAL THERAPY include a four-week program of daily sessions of MANUAL LYMPHATIC DRAINAGE, a special massage technique that tries to stimulate the lymphatic pathways and the anastomoses; the COMPRESSION THERAPY with a multicompartimental device, followed by a COMPRESSION BANDAGING with inelastic material that prevents any back flow of lymph after manual lymphatic drainage, and maintains pressure until next day. While wearing the bandages, the treatment is best completed with active exercises. The maintenance phase includes the use of compression stockings that must be tailor-made for each individual, exercises and skin care to prevent the appearance of erysipelas. The results of the treatment were very good in our patient despite the volume and chronicity of her lymphedema. As this disturbance has not cure at the moment, she is encouraged to follow the skin care, the use of the stocking and the exercises.

REFERENCES

1. Goltz RW. Focal dermal hypoplasia syndrome: an update. Arch Dermatol 1992; 128: 1108-1111.

2. Adornato MC, Perras S, Penna KJ. Focal dermal hypoplasia. Goltz syndrome. A case report. N Y State Dent J 2001; 67(1): 30-32.

3. Büchner SA, Itin P. Focal dermal hypoplasia syndrome in a male patient. Arch Dermatol 1992; 128: 1078-82.

4. Tapia-Barrios JM, Rodríguez-Ruiz IM, Casanova-Román M, Cañizares-Molle JC, Casanova-Bellido M. Síndrome de Goltz: Aportación de un caso en un varón. An Esp Pediatr 1998; 49: 513-515. (electronic journal at: <http://www.aeped.es/anales/anales96-99/suma/vol49/49-5/49-5-17.pdf> [Consulted February 2003]).

5. Orphanet. Focal Dermal Hypoplasia. <http://www.orpha.net/consor/cgi-bin/form/> [Consulted February 2003].

6. Temple IK, MacDowall P, Baraitser M, Atherton DJ. Focal dermal hypoplasia (Goltz syndrome). J Med Genet 1990; 27: 180-187.

7. Online Mendelian Inheritance in Man, OMIM(TM). Johns Hopkins University, Baltimore, MD. MIM Number: 305600: 25-10-2002: World Wide Web URL: <http://www.ncbi.nlm.nih.gov/htbin-post/omim/dispim?305600> [Consulted April 2003].

8. Holden JD, Akers WA. Goltz's syndrome: Focal Dermal Hypoplasia. A combined mesoectodermal dysplasia. Amer J Dis Child 1967; 114: 292-300.

9. Selzer G, David R, Revach M, Cvibah T, Fried A. Goltz syndrome with multiple giant cell tumor-like lesions in the bones. Ann Intern Med 1974; 80: 714-717.

10. Lofti M, Firooz A, Nosrati A, Tabatabai H, Dowlati Y. Linear atrophy, telangiectases, and soft nodules along the lines of Blaschko with skeletal abnormalities. Arch Dermatol 2001; 137: 1095-1100.

11. Moore KL, Persaud TVN. Periodo organogenético. De la cuarta a la octava semanas. In: Embriología Clínica. 6th Ed. Mexico: McGraw-Hill Interamericana; 1999. p. 88-111.

12. Moore KL, Persaud TVN. Aparato cardiovascular. In: Embriología Clínica. 6th Ed. Mexico: McGraw-Hill Interamericana; 1999. p. 370-425.

13. Acín García A. Embriología: Morfogénesis linfática. In: Pietravallo A. Linfedema. Tratamiento farmacológico, fisioterápico y quirúrgico. Buenos Aires: Phoenix, 1987, p. 26-28.

14. Barre V, Drouin-Garraud V, Marret S, Young P, Bachy B, Lechevallier J et al. Le syndrome de Goltz: à propos de trois observations. Arch Pédiatr 1998; 5:513-6.

15. Mann M, Weintraub R, Hashimoto K. Focal dermal hypoplasia with an initial inflammatory phase. Pediatr Dermatol 1990; 7: 278-82.

16. Ramsing M, Kn Ngo T, Holzgreve W, Rackowitz A, Küster W, Rehder H. Disruptive anomalies in a newborn with focal dermal hypoplasia (Goltz syndrome). European Journal of Dermatology 1997; 7: 15-8. (electronic journal at: <http://www.john-libbey-eurotext.fr/articles/ejd/7/1/15-8/index.htm [Consulted February 2003])

17. Schingale FJ. Lymphoedema. Lipoedema. Diagnosis and Therapy: a guide for those affected. Hannover: Schlütersche; 2003.

THE EUROPEAN JOURNAL OF lymphology and related problems
VOLUME 12 • No. 40 • 2004
INDEXED IN EXCERPTA MEDICA

LIPOSUCTION IN ARM LYMPHEDEMA TREATMENT

Håkan Brorson, M.D., Ph.D.
Consultant Plastic Surgeon, The Lymphedema Unit, Department of Plastic and Reconstructive Surgery, Lund University, Malmö University Hospital, Malmö, Sweden

CORRESPONDENCE:
HÅKAN BRORSON, THE LYMPHEDEMA UNIT, DEPARTMENT OF PLASTIC AND RECONSTRUCTIVE SURGERY, LUND UNIVERSITY, MALMÖ UNIVERSITY HOSPITAL, SE-205 02 MALMÖ, SWEDEN
TEL: +46 40 34 37
FAX: +46 40 33 62 71
EMAIL: hakan.brorson@plastsurg.mas.lu.se

ABSTRACT

Breast cancer is the most common disease in women, and up to 38% develop lymphedema of the arm following mastectomy, standard axillary node dissection and postoperative irradiation. Limb reductions have been reported utilizing various conservative therapies such as manual lymph and pressure therapy. Some patients with long-standing pronounced lymphedema do not respond to these conservative treatments because slow or absent lymph flow causes the formation of excess subcutaneous adipose tissue.
Previous surgical regimes utilizing bridging procedures, total excision with skin grafting or reduction plasty seldom achieved acceptable cosmetic and functional results. Microsurgical reconstruction involving lympho-venous shunts or transplantation of lymph vessels has also been investigated. Although attractive in concept, the common failure of microsurgery to provide complete reduction is due to the persistence of newly formed subcutaneous adipose tissue, which is not removed in patients with chronic non-pitting lymphedema.
Liposuction removes the hypertrophied adipose tissue and is a prerequisite to achieve complete reduction. The new equilibrium is maintained through constant (24-hour) use of compression garments postoperatively. Long-term follow up (7 years) does not show any recurrence of the edema.

KEY WORDS: arm lymphoedema, arm lymphedema, lymphoedema, lymphedema, breast cancer, liposuction, compression therapy, lymph therapy

1. INTRODUCTION

Lymphedema is a chronic disease with increased volume giving considerable dysfunction in terms of decreased mobility, heaviness, susceptibility to infections, psychological and cosmetic problems.
This influences activities of daily living and leisure as well as dress. In spite of the development of modern cancer treatment, lymphedema is still an important and to a great extent an underestimated problem.
Cancer treatment implies often removal of lymph glands and radiation therapy. Breast cancer affects more than 6000 women per year in Sweden, and about a third are affected with lymphedema (1).
Treatment of gynaecological tumors (about 2000 cases per year) leads to leg lymphedema in up to 40 per cent. Prostate cancer treatment (about 7000 cases per year) can lead to lymphedema where the incidence varies due to the aggressiveness of the therapy (5-66%).
The incidence of lymphedema after treatment of penis cancer (60 cases per year) and inguinal metastases is very high. Other tumors where treatment can lead to lymphedema is for example lymphoma, malignant melanoma, head and neck tumors and lung cancer.
In contrast to other types of edema, e.g. cardiac edema, chronic lymphedema has a high content of adipose tissue. Due to the decreased or absent lymph transport there is, in course of time, an increased formation of adipose tissue, and in later stages also fibrosis.
Soft tissue infection (cellulitis or erysipelas) can worsen the lymphedema and is mostly caused by streptococci.
Lymphedema can be divided into various stages due to the tissue changes (2). It can also be divided into primary and secondary forms. The later in life a lymphedema appears, the more important it is to exclude other diseases, especially cancer, as a cause of the edema.
Patients with lymphedema represent a large group and must be treated because an untreated edema can give considerable dysfunction. If diagnosed early the suffering of the patients can be prevented and economic resources can be saved.
There is, so far, no cure for lymphedema. The basis for all lymphedema treatment is adequate compression therapy. If conservative therapy is fails liposuction can give complete reduction of the excess limb volume.
To maintain this outcome it is an absolute necessity to provide the patient with ample amounts of compression garments. It is important to measure the excess volume, as changes can be a sign of progession of the underlying disease.
The Swedish national guidelines for lymphedema treatment have been released in 2003 and can be accessed on Internet: www.lymfödem.nu

2. PATHOPHYSIOLOGY

The lymph normally removes the proteins from the interstice. If the transport is blocked, the proteins remain in the tissues and will osmotically bind lymph fluid. The increased amount of lymph dilates the lymph vessels and gradually the valves become insufficient and the lymph transport is obstructed or ceases (3-7).

3. DEFINITIONS

Edema is defined as a volume increase in a body part and is initially caused by an accumulation of fluid. Edema is a symptom and not a diagnose. A lymphedema is caused by decreased lymph transport capacity caused by disease, malformation or earlier treatment (e.g. surgery, radiation) and leads to accumulation of lymph in the interstice with secondary changes in the tissues. Pitting means that a depression is formed after pressure with the fingertip on edematous tissue, resulting in squeezing lymph into the surroundings (figure 1a). To standardize the pitting-test one presses as hard as possible with the index finger, during one minute, on the region to be investigated. The amount of depression is estimated in mm. Edema dominated by hypertrophied adipose tissue and/or fibrosis shows little or no pitting (figure 1b). *Stemmer's sign* implies that one with difficulty, or not at all, can pinch the skin at the base of the toes or fingers. This is due to increased fibrosis and is characteristic for lymphedema.

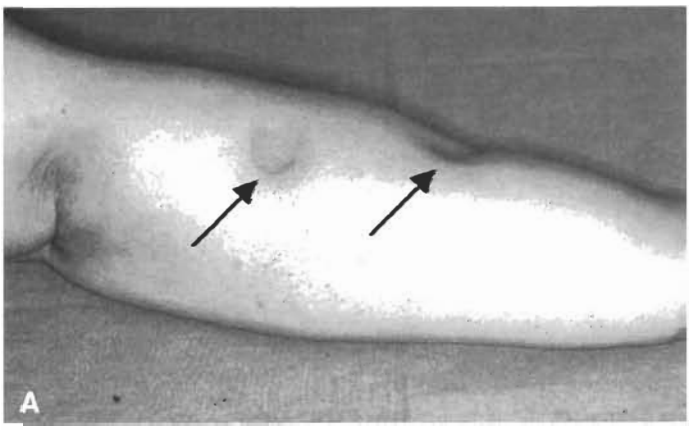

Figure 1a. *Marked arm lymphedema after breast cancer treatment with deep pitting of several centimeters (grade I edema). The arm swelling is dominated by fluid, i.e. accumulation of lymph. (© Håkan Brorson 2003)*

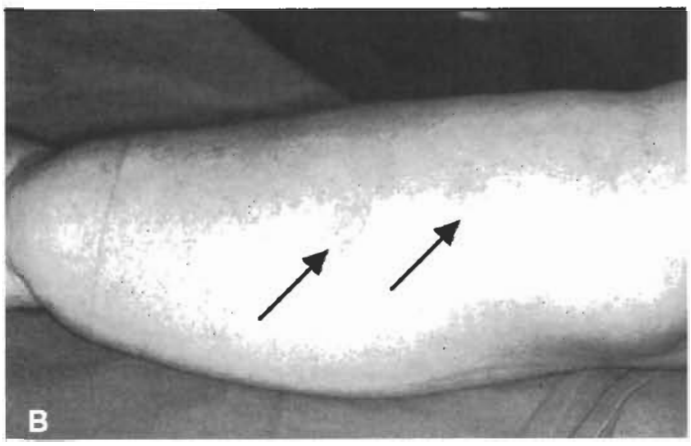

Figure 1b. *Pronounced arm lymphedema after breast cancer treatment (grade II edema). There is no pitting is spite of hard pressure by the index finger during one minute. A slight reddening is seen at the three spots where pressure has been exerted. The 'edema' is completely dominated by adipose tissue. The term 'edema' is in this stage improper as the swelling is dominated by hypertrophied adipose tissue and nor lymph. In this stage the aspirate contains no or minimal amount of lymph (figure 8). (© Håkan Brorson 2003)*

4. LYMPHEDEMA LEADS TO ADIPOSE TISSUE ACCUMULATION AND FIBROSIS

This phenomenon can be illustrated by the following example: Breast cancer treatment typically includes excision of regional axillary lymph nodes as staging and often radiotherapy for eradication of regional tumor spread. Both measures interfere with normal lymph drainage from the arm, and subcutaneous arm lymphedema, dominated by fluid, commonly ensues. Pitting is seen after pressure (figure 1a).
In healthy subjects the rate of blood flow and lymph flow through adipose tissue is inversely related to its growth, and a slow flow rate is considered one condition for lipogenesis and further deposition of fat. This process is enhanced by the transformation of macrophages into adipocytes (8). This may explain the marked hypertrophy of the adipose tissue seen in patients with chronic lymphedema (figure 2) (9). Subsequently subcutaneous lymphedema becomes firm and denser and is dominated by adipose tissue hypertrophy, and pitting is usually less pronounced or sometimes absent (figure 1b). Probably pinocytosis of white blood cells, in combination with activation of fibrocytes, increases the connective tissue component of the primordial loose subcutaneous fat (10). Fibrosis can totally dominate the excess volume of the extremity in patients with longstanding lymphedema, especially in the lower extremity.

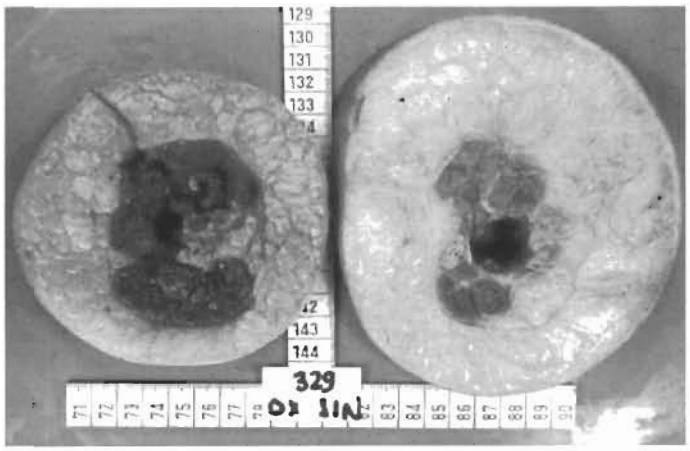

Figure 2. *Cross section of upper arms, autopsy samples. The hypertrophied adipose tissue of the lymphedematous left arm is clearly seen (Source: C-H Håkansson, Dept. of Oncology, c/o Southern Swedish Regional Tumor Registry, Lund University Hospital, Lund, Sweden). (© Håkan Brorson 2003)*

5. DIAGNOSIS

5.1. Anamnesis

A careful anamnesis for example regarding earlier diseases, operations, and irradiation is important. When, where, and how the edema started, the progression of the edema, which treatments have been tried and the result, are other important questions for a correct diagnosis.

5.2. Clinical examination

Skin changes are investigated: reddening, hyperkeratosis, pigmentations, leakage of lymph, scars, wounds, dermatitis due to irradiation. Palpation of the affected area(s) and all regional nodes shall be done. The range of motion in nearby joints is measured, as well as presence of pitting and Stemmer's sign are noted. The volume of the edema can easily be measured with the water displacement method, the extremity is lowered into water and the displaced volume is a measure of the volume of the extremity. The difference between the lymphedematous and healthy extremity represents the edema volume. The volume can also be calculated with the help of repeated circumferential measurements along the extremity, but this method takes longer time and is less accurate. The clinical investigation can in doubtful cases be supplemented with indirect lymphoscintigraphy, CT, or MRI, especially in patients with primary lymphedema.

5.3. Other investigations

Laboratory investigations are not necessary to establish a lymphedema. In doubtful cases, for example when suspecting a malignancy, some blood tests (hemoglobin, EVF, albumin, creatinin, liver tests) can give an indication of a disease in kidneys, liver or gastrointestinal tract with associated protein loss. When suspecting a cardiac insufficiency an X-ray of the heart and lungs is taken. Pen-doppler (CW-doppler) can be used to demonstrate reflux in the saphenous and popliteal veins. Color-duplex, pletysmography, vein pressure recordings, and phlebography can be used to further delineate the venous system. Direct lymphangiography, where oily contrast medium is injected direct into the lymph vessels, is seldom used as local infection or inflammation with damage to the lymphatics can occur. Also hypersensitive reactions and pulmonary embolism can ensue. Indirect lymphoscintigraphy using intradermal or subdermal injection of ^{99m}Tc-labeled microcolloid has nowadays replaced direct contrast lymphography as the preferred imaging tool for peripheral lymphedema, and is therefore particularly suited for studying patients with lymphedema where microcirculatory dynamics are already suboptimal. (11). CT and MRI can be used when suspecting primary or secondary malignancy in enlarged lymph glands. Differentiation between adipose tissue and water from other soft tissue can also be made. This can be seen as a reticular pattern reminding of a honeycomb (honeycomb pattern) (figure 3). Venous insufficiency can often be differentiated to a lymphedema with MRI.

6. TREATMENT

Up to date there is no cure for lymphedema in the aspect that one can reconstruct the damaged lymph system so that the normal function is completely reestablished. Patients must therefore be informed that lymphedema is a chronic disease, but that conservative treatment, where compression with a garment plays an important part, can relieve the symptoms. Sometimes surgery is needed, but even after a successful operation, compression garments must be used.

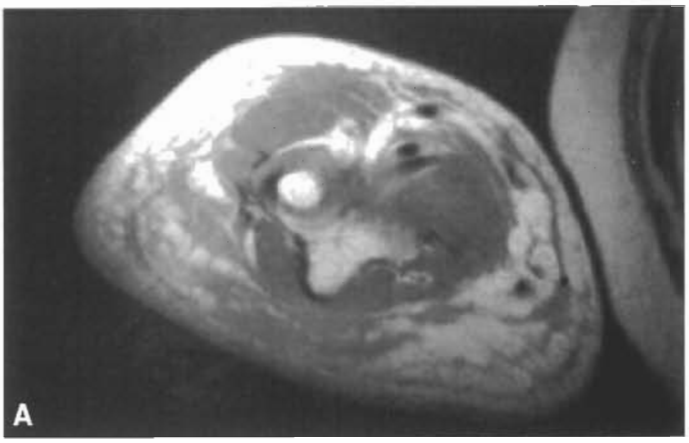

Figure 3a. *MRI (elbow region) showing a right-sided, secondary arm lymphedema after breast cancer treatment in the elbow region. Note the honeycomb pattern. (© Håkan Brorson 2003)*

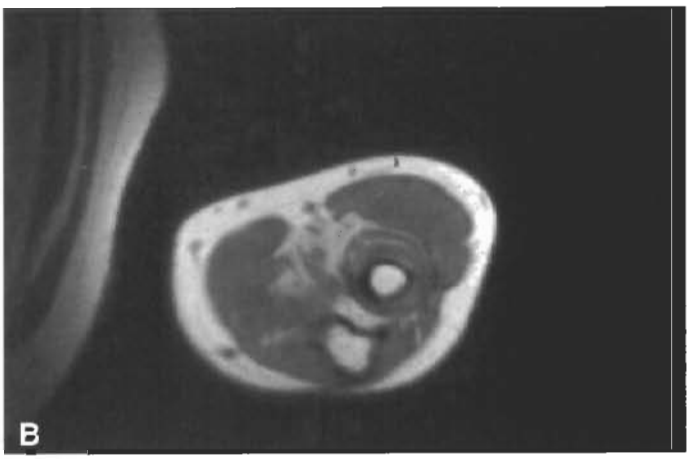

Figure 3b. *The healthy left side in the same patient for comparison. (© Håkan Brorson 2003)*

6.1. Surgical treatment

Despite prophylaxis the lymphedema will often progress slowly but steadily, necessitating a surgical approach. Surgical treatment, when tissue is removed, becomes indicated in patients, who fail to respond to conservative treatment because of hypertrophy of the subcutaneous adipose tissue, and later fibrosis (8-10). The swelling, the 'edema', does not show any pitting. The surgical intervention is therefore consequently directed towards the adipose tissue hypertrophy of the swelling, and not towards the fluid component, i.e. the lymph.

Various surgical procedures have therefore been proposed to reduce lymphedema, including interventions to the subcutis and deep fascia (13-19) (), and skin grafting (20, 21). None of these methods gave satisfactory or long-lasting results.

The breakthrough in reconstructive microsurgery has stimulated the interest to create such connections. During the last decades, anastomoses have been established between lymph nodes (22) or lymph collectors (23, 24) and the venous system. Promising results have recently been reported after transplantation of lymph collectors (25, 26), as well as after the creation of various forms of lymphatic venous anastomoses (27, 28).

Even if the microsurgical methods are attractive from a

physiological point of view, they do not give consistently satisfactory results. The patients need to wear compression garments after surgery, which indicate that normal lymph transport has not been achieved. Complete reduction can not be achieved in patients with a chronic lymphedema because the hypertrophied adipose tissue remains unchanged.
A prerequisite for a successful result is the continuous use of a compression garment after surgery.

6.1.1. Liposuction

A surgical approach, with the intention to remove the hypertrophied adipose tissue, seems logic when conservative treatment has not yielded satisfactory edema reduction and the patient has subjective discomfort of a heavy arm. This condition is especially seen in chronic, large arm lymphedemas around one liter in volume, or when the volume ratio (edematous arm/healthy arm) ≈ 1.3. The edema must not show any, or possibly minimal, pitting on pressure. By removing the excess adipose tissue the risk of developing lymphangiosarcoma will decrease. Preliminary clinical reports, although not impressive, warranted further refinement and evaluation of the procedure (29, 30).
At the Department of Plastic and Reconstructive Surgery, Malmö University Hospital, Malmö, Sweden the first liposuction of an arm lymphedema was undertaken in 1987, but it was not until 1993 that a more detailed treatment protocol was established and a lymphedema unit with a team was founded. The aim and direction was arm lymphedema after breast cancer treatment, as this is a large and common problem. There is no upper age limit in order to be accepted for surgery, but active tumor disease and ulcerations are contraindications (31).

6.1.1.1. Surgical technique

By the use of liposuction the excess hypertrophied adipose tissue is removed under bloodless conditions (figure 4-9). General anesthesia is used in most cases but some patients prefer nerve blockade in the combination of a plexus and scalenus block. Neither local anesthetic nor epinephrine is injected locally; hence the 'dry technique' is used.
Through around 15-20, 3 mm long incisions, the shoulder and arm – and even the hand and proximal phalanges when indicated – are treated (figure 5, 6).

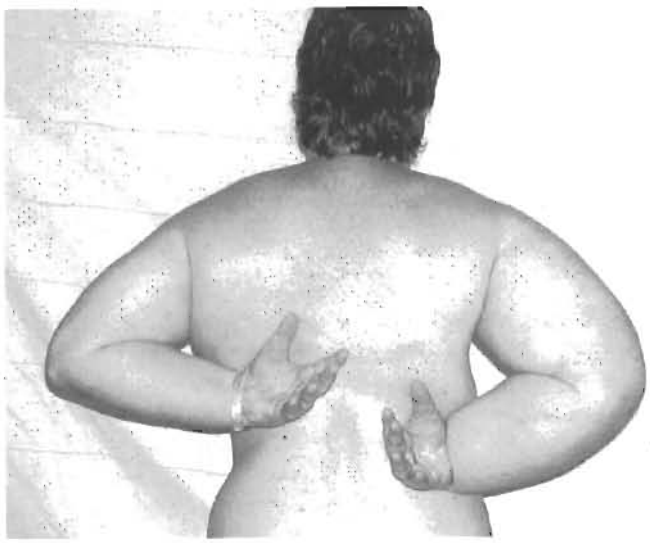

Figure 4. *Preoperative picture showing a patient with a large lymphedema (2865 ml) and decreased mobility of the right arm. (© Håkan Brorson 2003)*

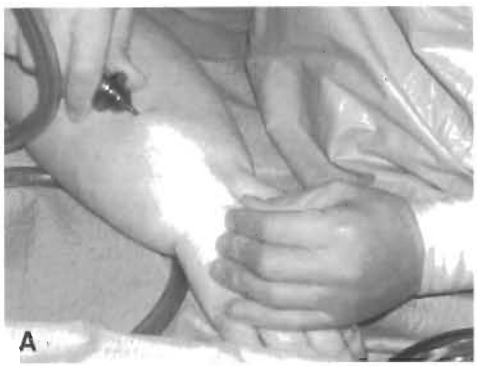

Figure 5a. *Liposuction is performed on the distal forearm. As much hypertrophied adipose tissue as possible is removed. (© Håkan Brorson 2003)*

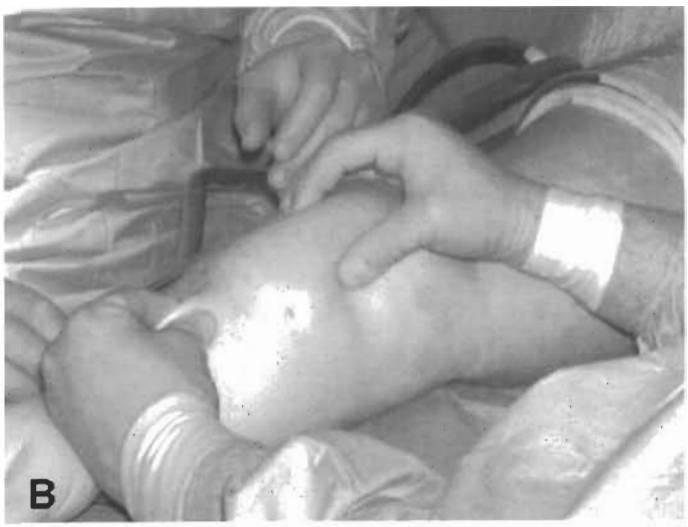

Figure 5b. *The left hand pinches the treated distal forearm, while the right pinches an untreated area. (© Håkan Brorson 2003)*

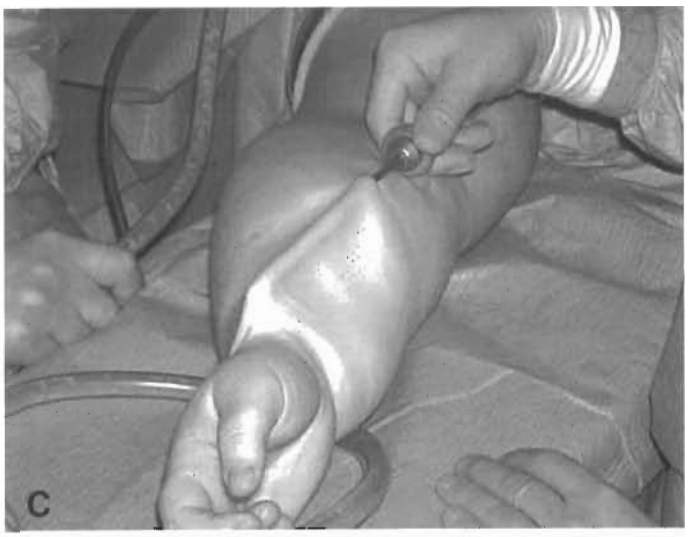

Figure 5c. *The cannula lifts the loose skin of the treated forearm. (© Håkan Brorson 2003)*

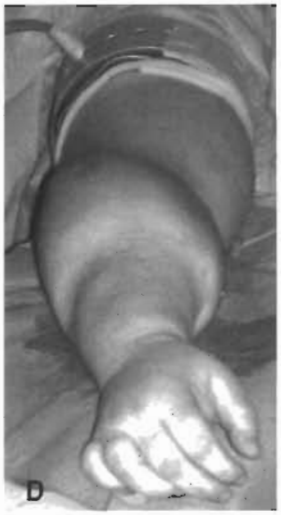

Figure 5d. *The distal half of the forearm has been treated. (© Håkan Brorson 2003)*

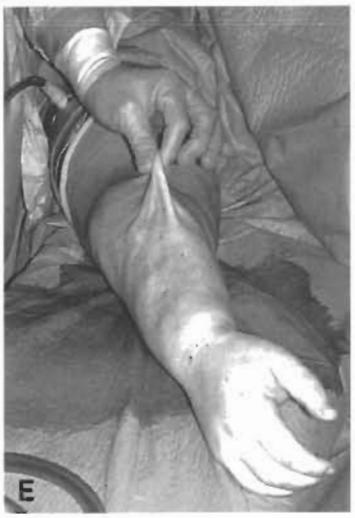

Figure 5e. *Lifting the excess skin after liposuction. The skin contracts within a few days. (© Håkan Brorson 2003)*

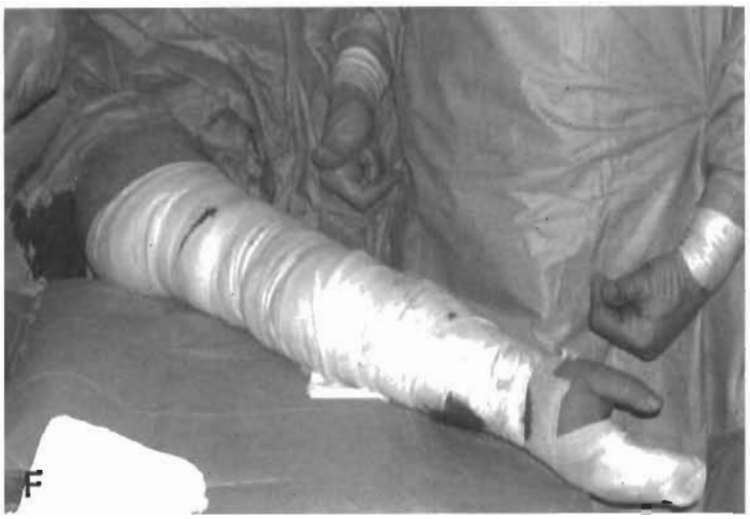

Figure 5f. *Treated areas are subsequently compressed firmly to stem bleeding after removal of the tourniquet in order to perform liposuction also of the proximal upper arm. After liposuction a standard compression garment is applied. (© Håkan Brorson 2003)*

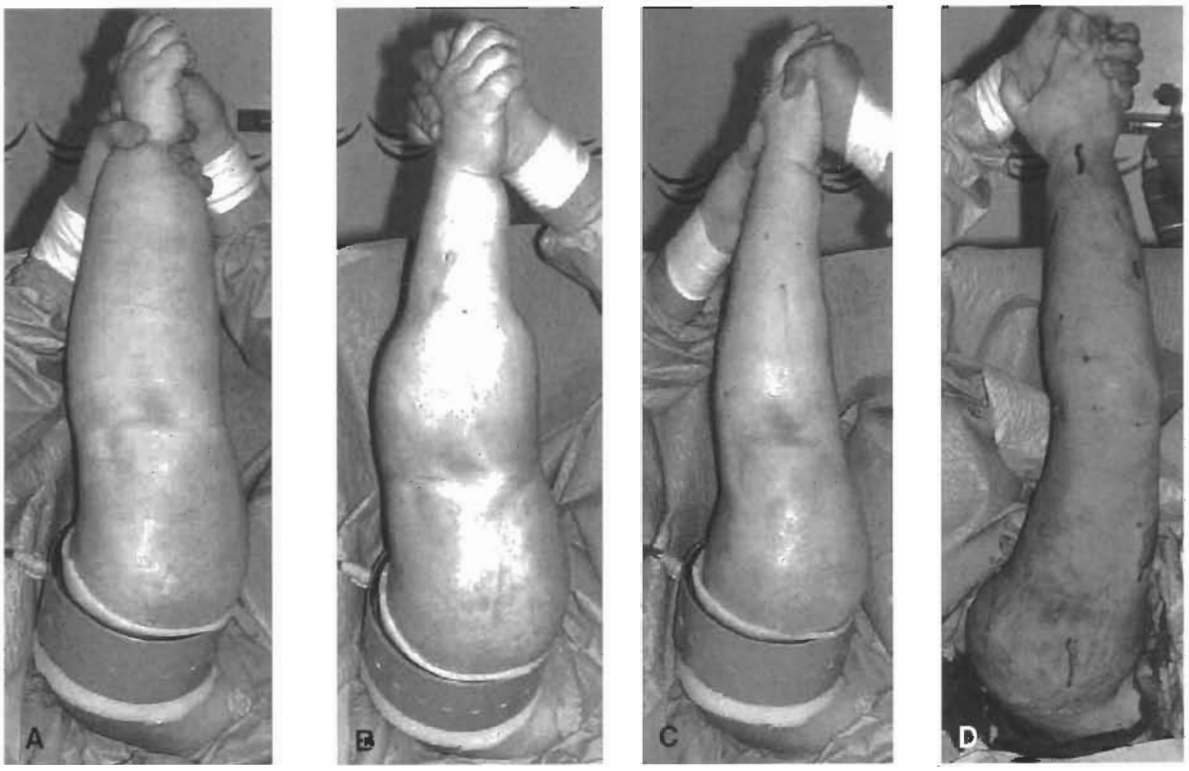

Figure 6. *Peroperative pictures from the beginning (a), during (b, c), and at the end (d) of surgery in the patient shown in figures 10 and 15. (© Håkan Brorson 2003)*

Cannulas are connected to a vacuum pump giving a negative atmospheric pressure of 0.9.
The cannulas are 15 cm long with an outer diameter of 3 and 4 mm and have three openings at the tip.
The finer cannula is used mainly for the hand, fingers, and distal part of the forearm, and also when irregularities were remedied.
The openings differ from normal liposuction cannulas in that they take up almost half of the circumference in order to facilitate the liposuction, especially in lymphedemas with excess fibrosis (figure 7).
Liposuction is executed circumferentially, step-by-step from hand to shoulder, and the hypertrophied and edematous fat is removed as completely as possible (figure 5, 6, 8)
When the arm distal to the tourniquet has been treated it is compressed by using sterile rolls of bandage to stem bleeding and postoperative edema. The tourniquet is removed and the most proximal part of the upper arm is treated (figure 6d). The incisions are left open to drain. A clean, but non-sterile, standard compression garment is applied (Jobst® Elvarex BSN medical), compression class 2) on the arm. The size of this garment is measured according to the size of the healthy arm. An interim glove (no 111089, Jobskin® interim care garment for burn scar

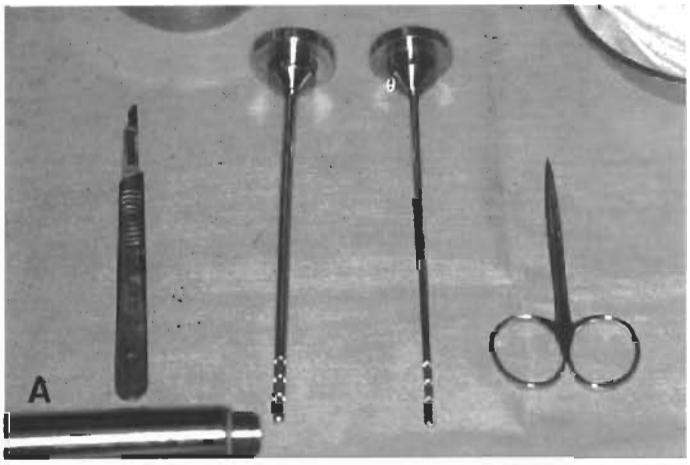

Figure 7a. *The liposuction cannulas are 15 cm long and have an outer diameter of 3 and 4 mm. (© Håkan Brorson 2003)*



B

Figure 7b. *Standard liposuction cannula (upper cannula) and liposuction cannula for lymphedema (lower cannula). (© Håkan Brorson 2003)*



C

Figure 7c. *In the tip there are 3 openings (frontal view). Note that the openings of the lower lymphedema cannula take up almost half of the circumference, compared to the upper standard liposuction cannula, in order to make liposuction more efficient, see figure 7d (side view). (© Håkan Brorson 2003)*

D

Figure 7d. *Side view of the cannulas shown in figure 7c. The lower cannula is used for lymphedema and the upper one for standard liposuction procedures. (© Håkan Brorson 2003)*



Figure 8. *The aspirate contains 90-100 per cent adipose tissue. This picture shows the aspirate from the lymphedematous arm of the patient shown in figures 4, 5, 6, and 8 before removal of the tourniquet. The aspirate sediments into an upper adipose fraction and a lower fluid fraction. The adipose fraction was 90 per cent. (© Håkan Brorson 2003)*

management, Smith & Nephew), where the tips of the fingers have been cut to facilitate gripping, is put on the hand.
The following day, a standard gauntlet (= a glove without fingers, but with a thumb) is put over the interim glove after the thumb of the glove has been cut off (Jobst® Elvarex BSN medical compression class 2). If the gauntlet is put on right after surgery, it can exert too much pressure on the hand when the patient is still not able to move the fingers after the anesthesia. Operating time is 2 hours on average. An isoxazolylpenicillin or a cephalosporin is given intravenously for the first 24 hours and then in tablet form for 2 weeks.

6.1.1.2. *Postoperative care*

The arm is held raised during the hospital stay, usually for 3-4 days. Two days postoperatively, measurements are taken for a custom-made compression garment, a sleeve and glove, compression class 2 (Jobst® Elvarex BSN medical).

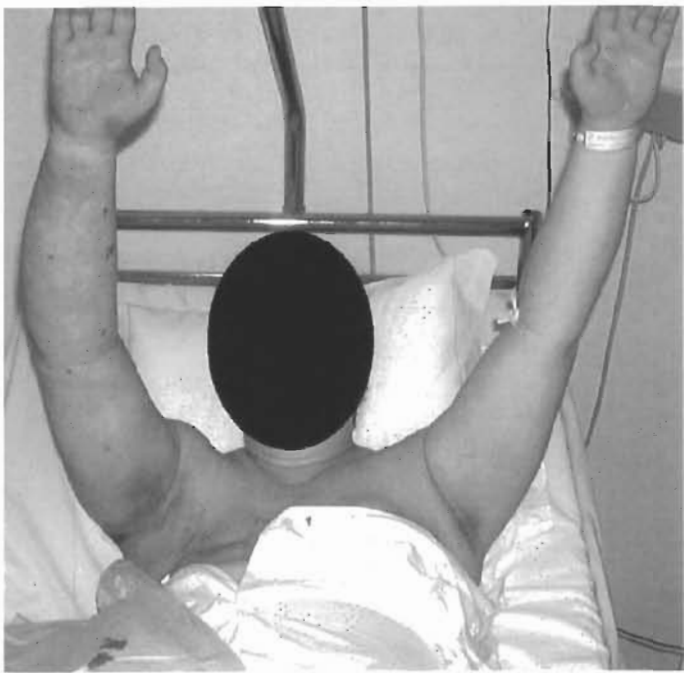

Figure 9. *The compression garment is removed two days after surgery in order to take measurements for a custom-made compression garment. A significant reduction of the right arm has been achieved as compared to the preoperative condition seen in figure 4. (© Håkan Brorson 2003)*

The patient alternates between two standard compression sleeves and gloves the first two postoperative weeks. At the 2-week control the new custom-made compression garment is applied, alternating this with a standard one until the 1-month visit. During the subsequent course, this rigorous compression regime, referred to as Controlled Compression Therapy (CCT), is maintained exactly as described below (12).

6.1.1.3. *Controlled Compression Therapy (CCT)*

The compression therapy is crucial, and its application is therefore thoroughly described and discussed at the first clinical evaluation. If the patient has any doubts about continued CCT, she is not accepted for treatment.
After institution of the compression therapy, the custom-made garment (Jobst® Elvarex BSN medical, compression class 2, rarely class 3) is taken in at each visit, using a sewing machine, to compensate for reduced elasticity and reduced arm volume.
This is most important during the first 3 months when the most notable changes in volume occur. At the 1-month visit another custom-made compression garment is measured for, alternating this with the old one until the 3-month visit.
At the 3-month visit, the arm is measured for new custom-made garments. This procedure is repeated at 6 and 12 months. It is important however, to take in the garment repeatedly to compensate for wear and tear.
This requires additional visits in some instances, although the patient can often make herself such adjustments. When the edema volume has decreased as much as possible and a steady state is achieved, new garments can be prescribed, using the latest measurements. In this way, the garments are renewed three or four times during the first year.
Two sets of sleeve-and-glove garments are always at the patients' disposal; one being worn while the other is washed. Thus, a garment is worn permanently, and treatment is interrupted only briefly when showering and, possibly, for formal social occasions. The patient is informed about the importance of hygienic measures and skin care.
The life span of two garments worn alternate is usually 4 to 6 months. After complete reduction has been achieved the patient is seen once a year when new garments are prescribed for the coming year, usually 4 garments and 4 gloves (or 4 gauntlets). In very active patients the 6 to 8 garments a year may be needed.

6.1.1.4. *Arm volume measurements*

Arm volumes are recorded for each patient using the water displacement technique. The displaced water is weighed on a balance to the nearest 5 g, corresponding to 5 ml. Both arms are always measured at each visit, and the difference in arm volumes is designated as the edema volume (32, 33). The decrease in the edema volume is calculated in percent, thus:

$$\frac{(EA_{pre} - HA_{pre}) - (EA_{post} - HA_{post})}{EA_{pre} - HA_{pre}} \times 100,$$

where

EA_{pre} = edematous arm before treatment
HA_{pre} = healthy arm before treatment
EA_{post} = edematous arm after treatment
HA_{post} = healthy arm after treatment

Arm volume measurements for calculating the edema volume is measured at each visit.

6.1.1.5 *Results*

A prerequisite to maintain the effect of liposuction is the continuous use of a compression garment (figure 10, 11).
The already decreased lymph transport capacity is not further impaired by liposuction (34). Liposuction decreases the incidence of erysipelas.
The point of bacterial entry may be a minor injury to the edematous skin, and impaired skin blood flow may respond inadequately to counteract impending infection. Reducing the edema volume by liposuction increases skin blood flow, and probably decreases the reservoir of proteinaceous fluid and adipose tissue, which may enhance bacterial overgrowth (35).
Through the combination of liposuction and CCT the lymphedema can be completely removed. Long-term follow up (7 years) does not show any recurrence of the edema (12, 33, 36, 37).

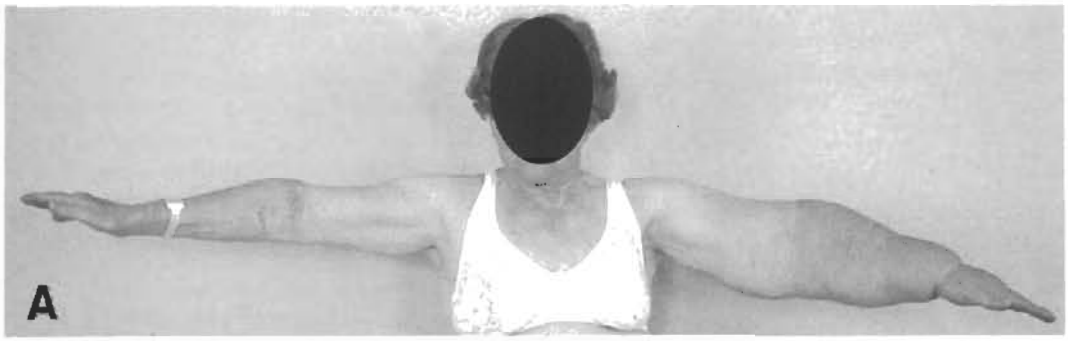

Figure 10a. *A 74-year-old-woman with a preoperative edema volume of 3090 ml in the left arm since 15 years. (© Håkan Brorson 2003)*

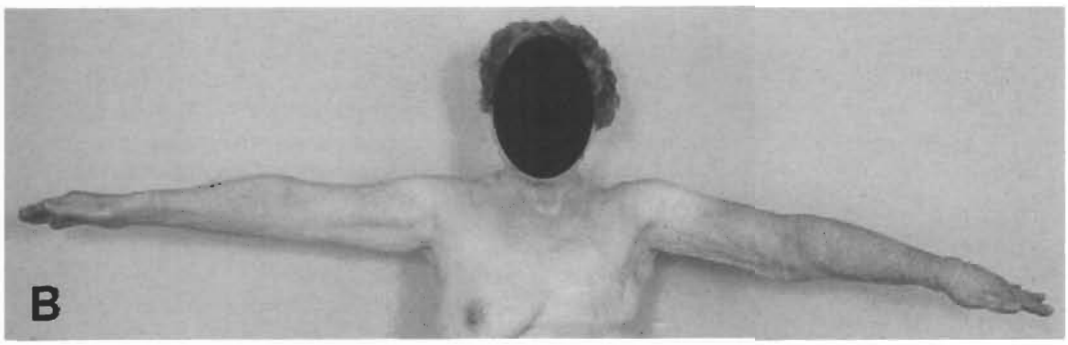

Figure 10b. *Clinical result 1 year after liposuction. (© Håkan Brorson 2003)*

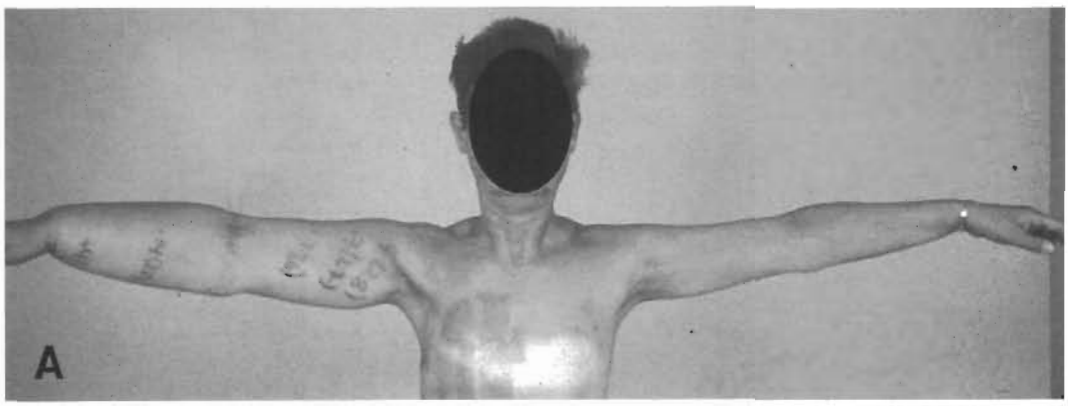

Figure 11a. *53-year-old woman with a preoperative edema volume of 2050 ml in the left arm since 8 years. (© Håkan Brorson 2003)*

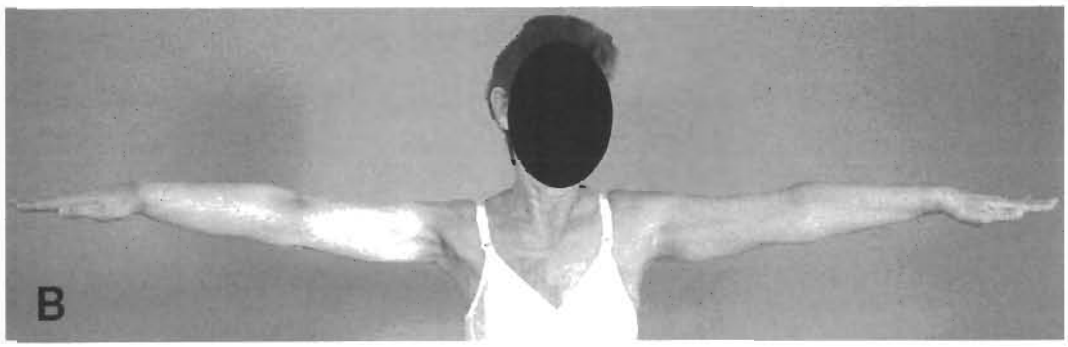

Figure 11b. *Clinical result 7 years after liposuction. (© Håkan Brorson 2003)*

7. THE LYMPHEDEMA TEAM

To investigate and treat patients with lymphedema, a lymphedema team comprising a plastic surgeon, an occupational therapist, a physiotherapist and a social welfare officer is a must. A 60-minute period is reserved for each scheduled visit to the team, when arm volumes are measured, garments are adjusted or renewed, the social circumstances are assessed, and other matters of concern are discussed. The patient is also encouraged to contact the team whenever any unexpected problems arise, so that these can be tackled without delay. In retrospect, a working group such as this one seems to be a prerequisite both for thorough preoperative consideration and informing patients, and for successful maintenance of immediate postoperative improvements. The team also monitors the long-term outcome, and our experiences so far indicate that a visit once a year is necessary to maintain a good functional and cosmetic result in most cases after complete reduction.

7. REFERENCES

1. Kissin MW, Quercì della Rovere G, Easton D, Westbury G. Risk of lymphoedema following the treatment of breast cancer. Br J Surg 1986; 73: 580-584.

2. International Society of Lymphology. Summary of the 10th International Congress of Lymphology Working Group Discussions and Recommendations. Lymphology 1985; 18: 175-180.

3. Földi M, Casley-Smith JR, eds. Lymphangiology. Stuttgart, New York: Schattauer Verlag; 1983.

4. Földi M, Kubik S, eds. Lehrbuch der Lymphologie. 4ed. Stuttgart, Jena, Lübeck, Ulm: Gustav Fischer Verlag; 1999.

5. Weissleder H, Schuchhardt C, eds. Lymphedema. Bonn: Kagerer Kommunikation, 1997.

6. Clodius L. Lymphatics, lymphodynamics, lymphedema: an update. Plastic Surgery Outlook 1990; 4: 1-6.

7. Witte CL, Witte MH, Dumont AE. High flow failure of the lymph circulation. Vasc Surg 1977; 11: 130-151.

8. Ryan TJ. Lymphatics and adipose tissue. Clin Dermatol 1995; 13, 493-498.

9. Brorson H, Åberg M, Svensson H. High content of adipose tissue in chronic arm lymphedema – an important factor limiting treatment outcome. Lymphology 1999; 32(Suppl): 52-54.

10. Gaffney RM, Casley-Smith JR. Excess plasma proteins as a cause of chronic inflammation and lymphoedema: biochemical estimations. J Pathol 1981; 133: 229-242.

11. Weissleder H, Weissleder R. Lymphedema: evaluation of qualitative and quantitative lymphoscintigraphy in 238 patients. Radiology 1988; 167: 729-735.

12. Brorson H, Svensson H. Liposuction combined with controlled compression therapy reduces arm lymphedema more effectively than controlled compression therapy alone. Plast Reconstr Surg 1998; 102: 1058-1067.

13. Sistrunk WE. Contribution to plastic surgery. Ann Surg 1927; 85; 185-193.

14. Ghormly RK, Overton LN. The surgical treatment of severe forms of lymphedema (elephantiasis) of the extremities. A study of end-results. Surg Gynecol Obstet 1935; 61: 83-89.

15. Thompson N. Surgical treatment of chronic lymphoedema of the lower limb. With preliminary report of new operation. BMJ 1962; ii: 1566-73.

16. Clodius L, Smith PJ, Bruna J, Serafin D. The lymphatics of the groin flap. Ann Plast Surg 1982; 9: 447-458.

17. Standard S. Lymphedema of the arm following radical mastectomy for carcinoma of the breast; new operation for its control. Ann Surg 1942; 116: 816-xxx.

18. Goldsmith SH, De Los Santos R. Omental transposition in primary lymphedema. Surg Gynecol Obstet 1967; 125: 607-610.

19. Tanaka Y, Tajima S, Imai K, Tsujiguchi K, Ueda K, Yabu K. Experience of a new surgical procedure for the treatment of unilateral obstructive lymphedema of the lower extremity: adipo-lymphatico venous transfer. Microsurgery 1996; 17: 209-216.

20. Charles H. Elephantiasis of the leg. In: Latham A, English TC, editors. A system of treatment. Vol 3. London: Churchill; 1912. p. 516.

21. Poth EJ, Barnes SR, Ross GT. A new operative treatment for elephantiasis. Surg Gynecol Obstet 1947; 84; 642-644.

22. Olszewski W, Niehubowicz J. Surgical lymphatico-venous communication in the treatment of lymphstasis. Proceedings of the 43rd Congress of Polish Surgeons; 1966; Lodz, Poland.

23. Laine JB, Howard JM. Experimental lymphatico-venous anastomosis. Surg Forum 1963; 14: 111-112.

24. O'Brien BM, Mellow CG, Khazanchi RK, Dvir E, Kumar V, Pederson WC. Long-term results after microlymphaticovenous anastomoses for the treatment of obstructive lymphedema. Plast Reconstr Surg 1990; 85: 562-572.

25. Baumeister RG, Siuda S, Bohnert H, Moser E. A microsurgical method for reconstruction of interrupted lymphatic pathways: autologus lymph-vessel transplantation for treatment of lymphedemas. Scand J Plast Reconstr Surg 1986; 20: 141-146.

26. Baumeister RG, Siuda S. Treatment of lymphoedemas by microsurgical lymphatic grafting: what is proved? Plast Reconstr Surg 1990; 85: 64-74.

27. Campisi C, Boccardo F, Tacchella M. Reconstructive microsurgery of lymph vessels: the personal method of lymphatic-venous-lymphatic (LVL) interpositioned grafted shunt. Microsurgery 1995; 16: 161-166.

28. Campisi C, Boccardo F, Alitta P, Tacchella M. Derivate lymphatic microsurgery: indications, techniques, and results. Microsurgery 1995; 16: 463-468.

29. Sando WC, Nahai F. Suction lipectomy in the management of limb lymphedema. Clin Plast Surg 1989; 16: 369-373.

30. O'Brien BM, Khazanchi RK, Kumar PA, Dvir E, Pederson WC. Liposuction in the treatment of lymphoedema: a preliminary report. Br J Plast Surg 1989; 42: 530-533.

31. Brorson, H. Liposuction and Controlled Compression Therapy in the Treatment of Arm Lymphedema following Breast Cancer. Lund University 1998. [Thesis]

32. Bernas M, Witte M, Witte C, Belch D, Summers P. Limb volume measurements in lymphedema: issues and standards.Lymphology 1996; 29 (Suppl). Pp. 199-202.

33. Brorson H, Svensson H. Complete reduction of lymphoedema of the arm by liposuction after breast cancer. Scand J Plast Reconstr Surg Hand Surg 1997; 31: 137-143.

34. Brorson H, Svensson H, Norrgren K, Thorsson O. Liposuction reduces arm lymphedema without significantly altering the already impaired lymph transport. Lymphology 1998; 31: 156-172.

35. Brorson H, Svensson H. Skin blood flow of the lymphedematous arm before and after liposuction. Lymphology 1997; 30: 165-172.

36. Brorson H, Åberg M, Svensson H. Complete reduction of arm lymphedema by liposuction following breast cancer - 5 year results. Lymphology 1999; 32(Suppl): 250-253.

37. Brorson H. Liposuction gives complete reduction of chronic large arm lymphedema after breast cancer. Acta Oncologica 2000; 39: 407-420.

Article already reported in: Scand. J. Surg. 2003; 92: 287-295.

groupement européen de lymphologie

Second announcement

XXXth Scientific Meeting of the

European Lymphology Group

BRUSSELS – 16, 17 OCTOBER 2004

PRESIDENTS OF CONGRESS O. Leduc
JC. Wautrecht

HONOUR PRESIDENTS M. Beaujean
G. Hidden
A. Leduc

TOPICS

❶ ***Content of lymphedema***

❷ ***Imaging of lymphatics and peripheral lymphedema***

❸ ***Lymphovenous diseases and dermatology***

❹ ***Peripheral lymphedema: from diagnosis to treatment***

PRESIDENTS OF SESSIONS H. Brörson, M. de la Brassine, M. Flour, E. Fumière, O. Leduc, D. Matter, S. Michelini, P. Mortimer, W. Olzewski, JC. Wautrecht

Congress Secretary postage
F. WILPUTTE - JP. BELGRADO
Department of Vascular Diseases
CUB - Hôpital ERASME
Route de Lennik, 808, B-1070 BRUSSELS
Fax + 32 2 555 35 36 / e-mail Fabienne.Wilputte@ulb.ac.be

Call for abstracts

Brussels – 16, 17 october 2004

DEAD LINE: JUNE 1st 2004

Abstract typing instructions:

- Please use the enclosed abstract form
- Arrange the abstract in the following order:
  - Title (in capital letters)
  - Author(s) first name and last name
  - Underline names of authors presenting the paper
  - Origin of work, city, country
  - Purpose
  - Methods
  - Results
  - Conclusions
- Type size should neither be smaller than 10 point nor larger than 12 point, true-type setting must be used.
- Don't write beyond the black frame, the text must fit into the space provided.
- The abstract has to be send exclusively by e-mail to the congress secretary.

Oral presentation ☐ Poster ☐

Topics* ❶ ☐ ❷ ☐ ❸ ☐ ❹ ☐ (* Tick one)

Note: Equipement required is data projection (CD-Rom will be available on operating system minimum Windows 98).

The CD-Rom of the presentation has to be send to the Congress Secretary before september 30th.

Name of the Presenting Author: _____

Institution: _____

Country: _____

Comments: _____

Congress Secretary postage
F. WILPUTTE - JP. BELGRADO
Department of Vascular Diseases
CUB - Hôpital ERASME
Route de Lennik, 808, B-1070 BRUSSELS
Fax + 32 2 555 35 36 / e-mail Fabienne.Wilputte@ulb.ac.be

Call for abstracts

Brussels – 16, 17 october 2004

DEAD LINE: JUNE 1st 2004

Abstract form

Address of the Presenting Author:

First name, last name: _____

Address: _____

_____

Phone: _____

Fax: _____

E-mail: _____

CALENDAR

XXX th SCIENTIFIC MEETING OF THE EUROPEAN LYMPHOLOGY GROUP
Groupement Européen de Lymphologie (GEL)
Brussels, 16-17 October 2004
Presidents: Prof Dr J-C Wautrecht, Prof O. Leduc.
Secretary: Lic J-P Belgrado, Lic F. Wilputte
E-Mail: www.ulb.ac.be/assoc/gel
Postage: F.Wilputte, Service de Pathologie Vasculaire, CUB Erasme Hospital,
808 route de Lennik, 1070 Brussels, Belgium

• • •

FIRST EUROPEAN LYMPHOLOGY COURSE
Brussels, 18-24 October 2004
Organized by the European Lymphology School
Informations and Program of the Course:
E-Mail: Pierre.bourgeois@bordet.be
Postage: Pr Pierre Bourgeois, Service of Nuclear Medicine,
Jules Bordet Institute, 1, rue Héger-Bordet, B-1000, Brussels, Belgium

• • •

22-26 May 2004, Rome (ITA)
21st WORLD CONGRESS OF THE INTERNATIONAL UNION OF ANGIOLOGY
ref.: 21st IUA World Congress, Via Sardegna 76, 90144 Palermo, Italy
Tel + Fax: + 39 091 511375

• • •

23-26 May 2004, Cancun (México)
XI CONGRESO DE FLEBOLOGIA Y LINFOLOGIA
DA SOCIEDADE PANAMERICANA DE FLEBOLOGIA E LINFOLOGIA
ref.: Dr.Flota Cervera - phone: (52)(999) 9944546 Fax: (52)(999) 9444610

• • •

22-25 September 2004, Vitoria (ES) (BRA)
8° CONGRESSO BRASILEIRO DE FLEBOLOGIA E LINFOLOGIA.
ENCONTRO LATINO AMERICANO DE FLEBOLOGIA.
ref: http://www.winproducoes.com.br/flebologia2004/

• • •

26-30 September 2005, Salvador-Bahia (BRA)
20th ISL INTERNATIONAL CONGRESS OF LYMPHOLOGY
ref: Phone/Fax: 55-11-3341-2980 / 3207-8241 Email: lymphology2005@uol.com.br
Email: numen@terra.com.br

21st World Congress of the International Union of Angiology
Rome, Italy, May 22-26, 2004

Joint Symposium IUA-GEL

LYMPHOLOGY IN EUROPE AND IN THE WORLD

May 25, 2004

Honorary Chairmen: M. Foeldi (Germany), A. Leduc (Belgium), M. Ohkuma (Japan)

Chairmen: P. Bourgeois (Belgium), C. Campisi (Italy)

Invited Speakers:

J.P. Belgrado (Belgium)
"Intermittent compression. Therapy to use or not to use. A review of literature"

F. Boccardo (Italy)
"Prevention of secondary arm lymphedema: diagnostic and therapeutic strategies"

E. Foeldi (Germany)
"Complete decongestive treatment (CDT) in lymphedema"

E. Iker (U.S.A.)
"Complication of Pelvic Lymphedenectomy"

O. Leduc (Belgium)
"Rehabilitation protocol in upper limb lymphedema"

S. Michelini (Italy)
"Management of primary and secondary lymphedema"

W. Olszewski (Poland)
"Effectiveness of longterm penicilin in dermatolymphangioadenitis"

A. Pissas (France)
"Prevention of lymphedema.Hazard or fatality?"

G. Thibaut (France)
"Activity of the Lymphology Center of the University Hospital of Nancy Eastern France"

M. Witte (U.S.A.)
"Genetics of lymphedema-Angiodysplasia Syndromes: Past, Present and Future"

C. Campisi (Italy)
"S.I.L. Guide-Lines and the activity of Genoa University Hospital Center"

P. Bourgeois (Belgium)
"Lymphology in Europe"

CONVEGNO INTERNAZIONALE
(Primo Annuncio)

"GENOVA, CAPITALE EUROPEA DELLA LINFOLOGIA"

Genova, Aula Magna del Padiglione Chirurgico Universitario
Sabato 30 ottobre 2004

Presidente: Prof. C. Campisi

Temi generali:

- *Basi biologiche e fisiopatologiche della Linfologia*
- *Epidemiologia e risvolti sociali*
- *La clinica, con particolare riferimento alle malattie di interesse chirurgico*
- *Percorsi diagnostici clinico-strumentali*
- *Attualità terapeutiche*
- *Ruolo della Chirurgia, con specifico riguardo per la Microchirurgia*
- *Day Surgery in Linfologia*
- *Protocolli di prevenzione*
- *L'approccio multidisciplinare*
- *Linfologia d'organo e d'apparato*
- *Attività clinica e di ricerca del Centro di Genova e relazioni internazionali*

Esperti invitati:

Studiosi del *European Group of Lymphology* (g.e.l), della *International Society of Lymphology (ISL)* e della Società Italiana di Linfangiologia (SIL)

Per informazioni:

PROF. C. CAMPISI, Dipartimento di Chirurgia, Centro di Chirurgia dei Linfatici e Microchirurgia,
Padiglione Chirurgico Universitario, Ospedale San Martino, Università degli Studi, Largo R. Benzi 8, 16132 Genova.
Tel. 010 3537297; Fax: 010 811465; E-mail: campisi@unige.it

È prevista la registrazione del Convegno presso il Ministero della Salute ai fini dell'accreditamento

Comfortable compression garments for controlling primary or secondary lymphoedema

Medi has the range of garments needed for the challenge of lymphoedema wherever it presents

The largest range of upper and lower limb compression garments. Sensitively designed to enhance patient compliance. Offering excellent compression and comfort. Available as "made to measure" for complex situations.

- Medi Standard and medi 95
- Armsleeve ccl 1 and 2
- Mediven 550 Armsleeves
- Mediven Plus and mediven forte lower limb garments
- Mediven 550 "made to measure"
- Mediven maxi 590 "made to measure"
- Mediven mondi 580 "made to measure"

Modern, medically proven compression solutions

Medi Bayreuth
Medicusstraße, 1 • D-95448 Bayreuth
Tel. +49-921912-0 • Fax +49-921912-57
e-mail: info@medi.de • www.medi.de