

OFFICIAL ORGAN
OF THE



EUROPEAN GROUP OF LYMPHOLOGY
LATIN-MEDITERRANEAN CHAPTER OF ISL
SOCIETÀ ITALIANA DI LINFANGIOLOGIA
CZECH SOCIETY OF LYMPHOLOGY
ROMANIAN SOCIETY OF LYMPHOLOGY
GREEK SOCIETY OF LYMPHOLOGY

THE EUROPEAN JOURNAL OF lymphology

and related problems

VOLUME 26 • No. 72 • 2015

INDEXED IN EXCERPTA MEDICA

SUMMARY

41st ESL Congress

**Centre Hospitalier Universitaire Vaudois (CHUV),
Rue du Bugnon 21
1011 Lausanne, Switzerland**

SCIENTIFIC PROGRAM	p. 3
Scientific Sessions (Abstracts):	
– Session I <i>Lymphatics in health and disease</i>	p. 8
– Session II <i>Lymphatic malformations and genetics</i>	p. 9
– Session III <i>Lymphatics' imaging</i>	p. 11
– Session IV <i>Immune cells, lymphatics, and cancer: from bench to bedside</i>	p. 11
– Session V <i>Patient education and lymphoedema in particular situations</i>	p. 12
– Session VI <i>Lymphoedema treatment: where do we stand in 2015?</i>	p. 13
Free Communications 1	p. 17
Free Communications 2	p. 19
Free Communications 3	p. 21
Free Communications 4	p. 24
Free Communications 5	p. 27
Free Communications 6	p. 29
Poster Session 1	p. 31
Poster Session 2	p. 34
Poster Session 3	p. 39
Poster Session 4	p. 44

THE EUROPEAN JOURNAL OF LYMPHOLOGY AND RELATED PROBLEMS (EJLRP)

The EJLRP - official organ of the European Group of Lymphology (ESL), Czech Society of Lymphology, Romanian Society of Lymphology, Greek Society of Lymphology, the Latin-Mediterranean Chapter of Lymphology (LMCL), the Società Italiana di Linfangiologia (SIL) covers all fields of Lymphology and aims to present a multidisciplinary approach to diseases of the lymphatic system, with information on the analysis, control and treatments of such diseases.

Topics

The topics include:

- anatomy and anatomopathology
- physiology and physiopathology
- pharmacology
- diagnostic methods (conventional radiology, nuclear medicine, ultrasonography, computed tomography, biopsy, nuclear magnetic resonance)
- therapy (surgery, medicine, radiotherapy, physical)
- oncology (primary lymphatic system diseases, lymphonodal metastatic process)
- immunology
- post-therapeutic complications
- upper and lower limb edemas

Manuscripts publications

Submitted manuscripts will be published in the form of Editorial, Review article, Original article, Teaching article, Special article, Work in progress, Case Report, Short Communications, Letter to the Editor (in English), Abstract (in English)

They will be subdivided in Clinical and Basic Sciences.

Send manuscripts to:
the Executive Editor

Dr. S. MICHELINI

Department of Vascular Rehabilitation
S. Giovanni Battista Hospital
Via L.E. Morselli, 13 - 00148 Rome, Italy
Tel. +39 06 655961 - Fax +39 06 65596235
e-mail: sandro.michelini@fastwebnet.it

The Editor-in-Chief

Prof. Dr. F. BOCCARDO

Department of Surgery, Lymphatic Surgery and Microsurgery
S. Martino Hospital, University of Genoa
Largo R. Benzi, 8 - 16132 Genoa, Italy
Fax 0039010532778 - e-mail: Francesco.boccardo@unige.it

Associate-Editors also can receive and promote articles and start the review process.

Publications languages

Official language of the Journal is English.

Publication rate

The EJLRP is published on a quarterly basis.

Subscription rates - All members of European Group of Lymphology or of National societies (with which the ESL has a cooperation agreement and whose fee includes a subscription to the EJLRP) receive the Journal free of charge.

Subscription rate for non-members is:

- for all issues, 30 € within European Countries, 50 € elsewhere,
- for single issue, 15 € within European Countries, 18 € elsewhere.

Annual subscription rate of ESL: 80 €

Please make cheque (in euro) to order of the ESL and to be sent to the Treasurer of the ESL: Mr J.P. BELGRADO, Treasurer of the ESL, Service de Kinésithérapie, Avenue Paul Héger, 28, OF 168, 1050, Brussels, Belgium.

E-mail: belgrado@ulb.ac.be or transfer the corresponding amount on the following Bank Account of the ESL n. 210-0557380-70 N° IBAN BE60 2100 5573 8070 BIC GEBABEBB (Générale de Banque), with mention of your name and of the year(s) subscription.

Change of address - Please notify the Secretary and the Treasurer of the ESL of any change of address and telephone number at least 30 days prior to the issue date by sending both the old and new address.

Data base & Treasurer of the ESL - J.P. BELGRADO: Université Libre de Bruxelles, CP 168, Av. F.D. Roosevelt, 50, 1050 Bruxelles, Belgium. Tel. +32 2 650.24.34 - Fax: +32 2 280.13.33 - Mobile +32 475 63.34.34

Business communications - Business communications concerning advertising, subscriptions, change of address, and permission requests should be sent to the Secretary, O. LEDUC, Service de Kinésithérapie, Avenue Paul Héger, 28 CP 168, 1050 Brussels, Belgium. Tel. (32) (2) 650.24.70 - Fax: (32) (2) 650.24.73.

Advertisements are subject to editorial approval and restricted to products or services pertinent to lymphology.

Advertising rates can be obtained from the Secretary and Treasurer.

Miscellaneous - The use of general descriptive names, trade names, trademarks, etc., in the publication, even if not specifically identified, does not imply that these names are not protected by the relevant laws and regulations.

While the advice and information in this Journal is believed to be true and accurate at the date of its going to press, neither the authors, the Editors, nor the publisher can accept any legal responsibility for any errors or omissions that may be made. The publisher makes no warranty, express or implied, with respect to the material contained herein.

The Editors do not accept any responsibility for opinions that may be made by the authors.

Areas of distribution - Austria, Belgium, Czech Republic, Denmark, Egypt, France, Germany, Greece, Holland, Hungary, Israel, Italy, Japan, Norway, Poland, Portugal, Rumania, Russia, Spain, Sweden, UK, USA.

E.S.L. EXECUTIVE COMMITTEE

Distinguished Honorary President
LEDUC ALBERT (Belgium)

President

BOCCARDO FRANCESCO (Italy)

Vice-Presidents

BAUMEISTER RUEDIGER (Germany)

FÖLDI ETHEL (Germany)

Secretary

LEDUC OLIVIER (Belgium)

Treasurer

BELGRADO JEAN PAUL (Belgium)

Scientific Committee President

PISSAS ALEXANDRE (France)

Scientific Committee Vice President

DIMAKAKOS EVANGELOS (Greece)

FÖRNER CORDERO ISABEL (Spain)

Members

BOURGEOIS PIERRE (Belgium)

BRORSON HÅKAN (Sweden)

BRUN JEAN PATRICE (France)

CESTARI MARINA (Italy)

ELIŠKA OLDŘICH (Czech Rep.)

HAMADÉ AMER (Lebanon)

JOHANSSON KARIN (Sweden)

MICHELINI SANDRO (Italy)

MONETA GIOVANNI (Italy)

RIQUET MARC (France)

THIBAUT GILBERT (France)

WALD MARTIN (Czech Rep.)

EUROPEAN JOURNAL OF LYMPHOLOGY AND RELATED PROBLEMS

Editor-in-Chief: P. BOURGEOIS (Belgium)

Executive-Editor-in-Chief: S. MICHELINI (Italy)

Assistant Executive Editors: O. ELIŠKA (Czech Rep.), M. CESTARI (Italy)

Assistant-Editors: J.P. BELGRADO (Belgium), I. FÖRNER CORDERO (Spain), A. HAMADÉ (Lebanon), E. IKER (USA), O. LEDUC (Belgium)

National delegates and Scientific Committee: G. AZZALI (Italy) - A. BEHAR (France) - K. BENDA (Czech. Rep.) - E. DIMAKAKOS (Greece) - E. ELIŠKA (Czech Rep.) - E. FÖLDI (Germany) - M. FÖLDI (Germany) - I. FÖRNER-CORDERO (Spain) - P.S. MORTIMER (Great-Britain) - W. OLSZEWSKI (Poland) - A. PECKING (France) - A. PISSAS (France) - A. SOUSA PEREIRA (Portugal) - G. THIBAUT (France) - M. WALD (Czech. Rep.)

International Board of Trustees: MFC ANDRADE (Brazil) - M. WITTE (USA) - C. PAPENDIECK (Argentina) - M. OHKUMA (Japan)

Secretary: O. LEDUC (Belgium)

Treasurer: J.P. BELGRADO (Belgium)

ESL Awards: Caplan price (anatomie, clinical) one year and the other year Papamiltiades price (physiology or patho physiology).

Graphics: Duògrafi snc, Rome - Printed by Arti Grafiche Europa srl, Pomezia (Rome)

Instructions to authors

General

Submission of an original article implies: that the work described has not been published before (except in the form of an abstract or as part of a published lecture, review, or thesis); that it is not under consideration for publication elsewhere; that its publication has been approved by all coauthors, if any, as well as by the responsible authorities at the institute where the work has been carried out (including ethical committees and national licencing authorities); that, if and when the manuscript is accepted for publication, the authors agree to automatic transfer of the copyright to the publisher; and that the manuscript will not be published elsewhere in any language without the consent of the copyright holders.

Manuscripts should be submitted in triplicate (original and two copies); they should be double-spaced, with wide margins on one side of the paper only, and should be carefully prepared in the style of this journal and checked before submission. Typing errors should be corrected legibly.

All manuscripts are subject to copy editing and, if necessary, will be returned to the authors for open questions to be answered or for missing information to be supplied before being sent to the printers. When extensive corrections are necessary, authors are responsible for having manuscripts retyped.

Pages should be consecutively numbered, starting with the title page. The desired position of figures and tables should be marked in the margin.

Changes in the proofs should be kept to a minimum: a charge will be made for changes introduced after the manuscript has been set in type.

Organization of the manuscript

The speed of publication depends greatly upon following these guidelines precisely.

1. The manuscript should be divided clearly into an Introduction, Materials and Methods, Results, Discussion and Conclusion and References. The text should be concise and consistent as to spelling, abbreviations, etc...

2. The **title page** should include the title of the work, first and last name(s) of author(s), name of institution, any footnotes referring to the title (marked with an asterisk), and the address of the author to whom the proofs are to be sent.

To facilitate communication between the authors, editors and publisher, the author should furnish a **telex or fax number** on the title page of the manuscript.

3. The **abstract** should be a summary of the hypothesis or aims of the work, the basic material and methods and the conclusion of the study.

4. Immediately following the abstract, up to 7 relevant **key words** should be supplied for subject indexing.

5. **Footnotes**, other than those referring to the title heading, should be numbered consecutively.

6. The accuracy of the **References** is the responsibility of the authors.

The list of references should only include works that are cited in the text and that have been published or accepted for publication. Personal communications should be mentioned in the text only. The list should be in alphabetical order according to the first author's name. Works by two authors should be listed alphabetically according to the second author's name, then chronologically; those by three or more authors should be in chronological order. References should be styled as follows.

Biancos J.A., Eimaleh D.R., Leppo J.I.A. (1986) Effect of glucose and insulin infusion on the myocardial extraction of a radioiodinated methyl-substituted fatty acid. *Eur. J. Nucl. Med.* 12: 120-124.
Gullberg G.T., Malko J.A., Eisner R.L. (1983) Bounday determination methods for attenuation correction in single photon emission computed tomography. In: Esser PD (ed). *Emission computed tomography: current trends*. Society of Nuclear Medicine, New-York, pp. 33-53.
Meltzer YL (1971) Hormonal and attractant pesticide technology. Noyes data, Park Ridge, New Jersey.

Citations in the text should be given in parentheses (Child 1941; Godwin and Cohen 1969; MacWilliams et al., 1970), except when the author is mentioned, as in "and the study of Hiliman and Tasca (1977)".

7. **Tables** should be submitted on separate sheets. Numerical data given in graphs and tables must not be duplicated.

8. All **figures**, whether photographs, graphs or diagrams, should be numbered consecutively throughout and submitted on separate sheets. Plate layouts or single figures may either match the width of the column (9 cm) or be 11.8 cm in width with the legend at the side.

The maximum height for a figure or plate is 23 cm, including the legend printed at its foot. Photographs can be grouped into plates. They must be mounted on regular bond paper, not on cardboard.

All photographs and electron micrographs should be supplied as high-contrast glossy prints trimmed at right angles. Inscriptions on illustrations should allow for reduction if this is necessary; figures and letters should have a final height of 2 mm after reproduction.

Color illustrations will be accepted: however, the authors will be expected to make a contribution (approximately BF 7.500 per page) to the additional costs involved.

9. Typewritten **mathematical equations** should be clear, so that there is no opportunity for misinterpretation by the printer.

All letters contained in formulae as well as single letters in the text are automatically set in italics and therefore require no underlining. Hence, abbreviations that appear in formulae and are to be set in roman type (the type normally used for the text) should be specially marked by underlining in yellow, if possible.

It will be helpful to the printer if *Greek characters are underlined in red and script in green*. Lowercase letters should then be underlined once and capital letters twice; this applies also to Latin letters in formulae (in pencil). Boldface type (heavy type) should be marked by wavy underlining.

Subscripts and superscripts should be indicated by an inverted caret below the line, or a caret above the line, respectively: 12_2 ; a subscript to a subscript is styled: 12_{12} .

Obscure primes and dots must be clarified for the printer. The following must be differentiated clearly: number 1 and letter l; zero 0 and letters O, o, e, c, n, u, v, primes and apostrophes. Fractional exponents should be used in, stead of root signs and the solidus (/) for fractions whenever they are horizon. tal; an exp notation must be numbered sequentially in arabic numerals in parentheses on the right-hand side of the page.

10. Fifty (50) *offprints* of each paper with additional copies are available in lots of 100, (provided the order is teceived with the corrected proofs) may be supplied charged to the authors.

11. Enclose the picture of the first author of each article.



European Society of Lymphology

41st ESL CONGRESS

Lausanne (Switzerland) - June 4-6, 2015

Congress Venue:

**Centre Hospitalier Universitaire Vaudois (CHUV),
Rue du Bugnon 21**

President: Prof. Lucia Mazzolai, MD, Ph.D

LOCAL ORGANIZING COMMITTEE

Amann-Vesti Beatrice (CH)
Baumgartner Iris (CH)
Delaloye Jean-François (CH)
Depairon Michele (CH)
Hayoz Daniel (CH)
Lessert Claudia (CH)
Matter Maurice (CH)
Mazzolai Lucia (CH)
Petrova Tatiana (CH)
Prior John (CH)
Ramelet Albert Adrien (CH)
Righini Marc (CH)
Staub Daniel (CH)
Tomson Didier (CH)
Swartz Melody (CH)
Wagner Stephan (CH)

ESL EXECUTIVE COMMITTEE

<i>President:</i>	Boccardo Francesco (Italy)
<i>Honorary President:</i>	Leduc Albert (Belgium)
<i>Vice-Presidents:</i>	Baumeister Ruediger, Foeldi Ethel (Germany)
<i>Secretary:</i>	Leduc Olivier (Belgium)
<i>Treasurer:</i>	Belgrado Jean Paul (Belgium)
<i>Scientific Committee President:</i>	Bourgeois Pierre (Belgium)
<i>Scientific Committee Vice President:</i>	Dimakakos Evangelos (Greece)
<i>Members</i>	Brorson Hakan (Sweeden) Brun Jean Patrice (France) Campisi Corradino (Italy) Cestari Marina (Italy) Eliška Oldrich (Czech Rep.) Forner-Cordero Isabel (Spain) Johansson Karin Hamadé Amer Michelini Sandro (Italy) Moneta Giovanni (Italy) Olszewski Waldemar (Poland) Papendieck Cristobal (Argentina) Pissas Alexandre (France) Riquet Marc (France) Thibaut Gilbert (France) Wald Martin

ISL EXECUTIVE COMMITTEE

<i>Past President:</i>	Gurusamy Manokaran (India)
<i>President:</i>	Hakan Brorson (Sweeden)
<i>President Elect:</i>	Ningfei Liu (China Rep.)
<i>Secretary-General:</i>	Marlys H. Witte (USA)
<i>Treasurer:</i>	Alexandre Pissas (France)
<i>Members</i>	Miguel Amore (Argentina) Mauro Andrade (Brazil) Ruediger Baumeister (Germany) Francesco Boccardo (Italy) Corrado Cesare Campisi (Italy) Evangelos Dimakakos (Greece) Karin Johansson (Sweden) Stanley P.L. Leong (USA) Sandro Michelini (Italy) Moriya Ohkuma (Japan) Eikichi Okada (Japan) Andrzej Szuba (Poland)
<i>Advisory Committee:</i>	Corradino Campisi (Italy) Cristobal Papendieck (Argentina)
<i>Auditors:</i>	Alberto Macciò (Italy) Makoto Mihara (Japan)

SCIENTIFIC PROGRAM

Credits: 25 SSA, 18 SSML, 18 SSMG, 18 PHYSIOSWISS

June 4th, Thursday Auditoire C. Roux

- 08.30-09.30 PRE CONGRESS WORKSHOP**
sponsored by MEDI (French)
V. Weibel, R. Oberfeld (DE)
- 09.30-10.00 Welcome coffee**
- 10.00-10.15 CONFERENCE OPENING**
L. Mazzolai (CH); F. Boccardo (IT)
- 10.15-10.35 OPENING LECTURE**
Chair: F. Boccardo (IT)
Epidemiology and economic impact of lymphoedema: a world perspective
C. Moffatt (GB)

10.35-12.15 Plenary Session 1 Auditoire C. Roux

- LYMPHATICS IN HEALTH AND DISEASE**
Chair: C. Campisi (IT); I. Baumgartner (CH)
- 10.35-11.00 Lymphangiogenesis in health and disease**
M. Jeltsch (FI)
- 11.00-11.25 Lymphatic valves and beyond**
T. Petrova (CH)
- 11.25-11.50 Lymphatics and atherosclerosis**
A. Szuba (PL)
- 11.50-12.15 Lymphatics and veins: an intimate relationship**
B.B. Lee (US)
- 12.15-13.15 Lunch break in the Exhibition – Poster Viewing and Moderated Poster session 1**

Moderated poster session 1 Auditoire A. Yersin

- Chair:* TBA
- 12.20-12.25 Congenital syndromic asymmetric overgrowth in pediatrics**
Papendieck C.M.
- 12.25-12.30 The effectiveness of complex decongestive physiotherapy implementations on quality of life and depression in patients with chronic venous insufficiency**
Cinar Ozdemir O.
- 12.30-12.35 The role of interleukin-7 in lymphatic vessel function and its therapeutic potential for the treatment of lymphedema and chronic skin inflammation**
Vranova M.
- 12.35-12.40 CCL21 expression pattern in lymphatic vessels**
Arasa J.
- 12.40-12.45 Axillary Vein Compression Test**
Belgrado J.P.
- 12.45-12.50 Lymphedema patients' self-treatment: psychological aspects**
Arasa J.
- 12.50-13.00 Discussion**

13.15-14.15 Free communications 1 Auditoire A. Tissot

- Chair:* C. Papendieck (AR); M. Cestari (IT)
- 13.15-13.30 Randomized clinical trial comparing bcrl and qol between breast cancer patients treated with short course image guided rt and conventional post surgery**
N. Adriaenssens (BE)
- 13.30-13.45 Lipofilling of the axilla to reduce secondary lymphedema after axillary lymph node dissection**
L. Vandermeeren (BE)
- 13.45-14.00 Liposuction of postmastectomy arm lymphedema decreases the incidence of erysipelas**
H. Brorson (FI)
- 14.00-14.15 Lymphatic complications control following inguinal and axillary radical lymph node dissection: a randomized controlled trial**
M.-L. Matthey-Gié (CH)

13.15-14.15 Free communications 2 Auditoire A. Yersin

- Chair:* TBA
- 13.15-13.30 A new method for measuring deep tissues tonometry in lymphedema**
M. Zaleska (PL)
- 13.30-13.45 Evaluation of the axillary web syndromes (AWS) by lymphoscintigraphis imagings**
O. Leduc (BE)
- 13.45-14.00 Effectiveness of passive movement in the volume of lymphedema and consistency reduction**
P. Domingo (ES)
- 14.00-14.15 Deep infrared imaging to identify venous impairment after breast cancer surgery**
J.P. Belgrado (BE)

14.25-15.25 Moderated poster session 2 Auditoire C. Roux

- Chair:* C. Campisi (IT)
- 14.25-14.30 Replacement of obliterated lymphatic collectors in obstructive lymphedema by silicone tubing implants**
Olszewski W.L.
- 14.30-14.35 Cumulative patency rate of lymphatic venous anastomosis and postoperative changes of compression in treatment of upper limb lymphedema**
Maegawa J.

14.35-14.40	Liposuction of lower limb with pitting lymphedema - Case report Wald M.
14.40-14.45	Quality of life after lymphedema surgery with lymphovenous anastomosis (lva) in supermicrosurgery technique Seidenstuecker K.
14.45-14.50	Ponctions for “seromas” after complete axillary node dissection (calnd) for breast cancer (bc): institutional survey and preliminary analysis Roman M.
14.50-14.55	The chondroepitrochlearis muscle: a rare cause of axillary vein thrombosis and lymphedema Thomet C.
14.55-15.00	Thoracic duct and chylous disorders the key role of the anatomy on the clinical and surgical treatment Amore M.
15.00-15.05	Two year follow-up of breast edema after breast conserving surgery and radiotherapy Johansson K.
15.05-15.10	Lymphatic vessels - remarks concerning of morphology regularity or irregularity. Are they important for function of lymphatics? Oldrich E.
15.10-15.25	<i>Discussion</i>

14.25-15.25	Workshop 1 (English) <i>Auditoire A. Tissot</i>
Chair:	E. Foeldi (DE)
	COMPRESSION IN LYMPHOEDEMA MANAGEMENT
14.25-14.45	Decision making in compression therapy H. Partsch (AT)
14.45-15.05	Compression garment: custom vs over-the-counter C. Lessert (CH)
15.05-15.25	Prescribing and fitting garments for children A. Vollmer (DE)

14.25-15.25	Workshop 2 (French) <i>Auditoire A. Yersin</i>
Chair:	D. Tomson (BE)
	ICG_ FLUOROSCOPIE: ASPECTS PRATIQUES J.-P. Belgrado (BE)

15.25-15.55 *Coffee break in the Exhibition – Poster Viewing*

15.55-17.30	Plenary Session 2 <i>Auditoire C. Roux</i>
Chair:	LYMPHATIC MALFORMATIONS AND GENETICS R. Clemens (CH); S. Michelini (IT)
15.55-16.20	Genetics of Lymphoedema: One symptom, many causes P. Ostergaard (GB)
16.20-17.05	Which assessment for primary lymphoedema? S. Michelini (IT)
17.05-17.30	Combined primary lymphoedema and other vascular malformations B.B. Lee (US)

17.40-18.40	Moderate Poster Session 3 <i>Auditoire C. Roux</i>
Chair:	P. Bourgeois (BE)
17.40-17.45	Anatomical deformation of tissue in lymphedema-fluid channel formation, effect of intermittent pneumatic compression Zaleska M.
17.45-17.50	The effects of three-years pneumatic compression of postinflammatory and post-traumatic edema of lower limbs Zaleska M.
17.50-17.55	A novel clinical test for setting intermittent pneumatic compression parameters based on edema fluid hydromechanics in the lymphedematous calf Olszewski W.L.
17.55-18.00	New developments in therapy of lymphedema. Linforoll and its application Olszewski W.L.
18.00-18.05	Hydromechanics of tissue edema fluid under compression bandages Zaleska M.
18.05-18.10	The right treatment of lymphangitis: from early diagnosis with specific clinical score to a correct short stretch bandage also with new manuka honey dressing Macciò A.
18.10-18.15	Effect of Manual Lymph Drainage and Compression Bandage on Hematoma after Supraspinatus Tendinitis Rupture Bakar Y.
18.15-18.20	Is there an interest to perform twice daily short-stretch multicomponent bandaging during hospital intensive treatment of lower limb lymphedema? Lessert C.
18.20-18.25	Effect of intermittent pneumatic compression on quality of life and edema in patients with chronic venous insufficiency Cinar Ozdemir
18.25-18.40	<i>Discussion</i>

17.40-18.40	Workshop 2 (English)
	Auditoire A. Tissot

<i>Chair:</i>	O. Leduc (BE)
	HOW TO MEASURE LYMPHOEDEMA TREATMENT OUTCOME?
17.40-18.00	Volume assessment S. Wagner
18.00-18.20	Measuring treatment outcome and follow-up. How I do it! H. Brorson
18.20-18.40	Tissue dielectric measurement T. Lahtinen

17.40-18.40	Workshop 2 (French)
	Auditoire A. Yersin

<i>Chair:</i>	J.-F. Delaloye (CH)
	COMMENT MESURER L'EFFICACITÉ DU TRAITEMENT PAR PHYSIOTHÉRAPIE?
17.40-18.00	Mesures volumétriques C. Schuchhardt
18.00-18.20	Qualité de vie I. Forner-Cordero
18.20-18.40	Mesure de pression sous bandage D. Tomson
18.40	<i>ESL Board Assembly (Conference Room S2)</i>

June 5th, Friday	
08.30-10.10	Plenary Session 3
	Auditoire C. Roux

<i>Chair:</i>	D. Staub (CH); B. Amann-Vesti (CH)
08.30-08.55	Which role for lymphoscintigraphy in clinical practice? P. Bourgeois (BE)
08.55-09.20	Lymphatic leakage analysis by CT lymphography P. Bize (CH)
09.20-09.45	Is there a future for ICG-fluoroscopy in clinical practice? J.-P. Belgrado (BE)
09.45-10.10	Is there a future for ultrasound imaging in lymphoedema detection and characterization? S. Mestre Godin (FR)
10.10-10.30	<i>Coffee break in the Exhibition – Poster Viewing</i>

10.30-12.05	Plenary Session 4
	Auditoire C. Roux

<i>Chair:</i>	D. Hayoz (CH); P. Bourgeois (BE)
	IMMUNE CELLS, LYMPHATICS, AND CANCER: FROM BENCH TO BEDSIDE
10.30-10.55	Lymphatics and cellular trafficking C. Halin Winter (CH)
10.55-11.20	Tumor-associated lymphatic vessels and the sentinel lymph node: New insights for potential therapeutic targets M. Swartz (CH & US)
11.20-11.45	Lymphatic microsurgery (LYMPHA) for cancer-related lymphoedema prevention F. Boccardo (IT)
11.45-12.05	Lymphatic mapping prior to sentinel node biopsy M. Matter (CH)

12.15-13.30	Free communications 3
	Auditoire C. Roux

<i>Chair:</i>	S. Vignes (FR); TBA
12.15-12.30	Chylous reflux and primary lymphedema in pediatrics C.M. Papendieck (AR)
12.30-12.45	Clinical manifestations of lipedema from a prospective cohort of patients I. Forner-Cordero (ES)
12.45-13.00	Importance of patient education in erysipelas control following breast cancer related lymphedema Y. Bakar (TR)
13.00-13.15	New method for detection of dormant bacteria in lymphedematous tissues W. Olszewski (PL)
13.15-13.30	Primary prevention after breast cancer treatment primary prevention protocol M. Cestari (IT)

12.15-13.30	Free communications 4
	Auditoire A. Tissot

<i>Chair:</i>	L. Mazzolai (CH); B. Amann-Vesti (CH)
12.15-12.30	Immunology of secondary lymphoedema M. Ohkuma (JP)
12.30-12.45	Unraveling the pathobiology of lymphoedema E. Gousopoulos (CH)
12.45-13.00	Clinical reliability and therapeutical indications of PRO-BNP in lower limbs edema S. Michelini (IT)
13.00-13.15	Stewart-Treves syndrome: the mechanism of the oncogenesis and nature of the vascular neoplasm E. Okada (JP)
13.15-13.30	Near infrared fluorescence imaging of lymphatic vessels after subcutaneous injection of free indocyanine green: what do we see? Preliminary results P. Bourgeois (BE)

12.15-13.30	Workshop 3 (French)
	Auditoire A. Yersin

Modération: C. Schuchhardt (DE)

LA COMPRESSION DANS LE TRAITEMENT DU LYMPHOEDÈME

12.15-12.50 **Bas sur mesure vs standard**

C. Lessert (CH)

12.50-13.30 **Comment mesurer et confectionner des bas pour les enfants?**

A. Vollmer (DE)

	Keynote Lecture
	Auditoire C. Roux

14.15-14.45 **The lymphatic system: no longer secondary to the blood vascular system**

S.G. Rockson (US)

14.45-16.25	Plenary Session 5
	Auditoire C. Roux

Chair: C. Johansson (SE); M. Righini (CH)

PATIENT EDUCATION AND LYMPHOEDEMA IN PARTICULAR SITUATIONS

14.45-15.10 **Effectiveness of patient education**

M. Sneddon (UK)

15.10-15.35 **Interactions between obesity and lymphedema**

S. Vignes (FR)

15.35-16.00 **Lymphoedema in children**

I. Queré (FR)

16.00-16.25 **Management of patients with arm lymphoedema following breast cancer surgery**

M. Foeldi (DE)

16.25-16.55 *Coffee break in the Exhibition – Poster Viewing*

16.55-17.55	Moderate Poster Session 4
	Auditoire C. Roux

Chair: W. Olszewski (PL)

16.55-17.00 **Fluorescence microlymphography: office-based diagnostic potential for detecting lymphoedema**

Keo Hong H.

17.00-17.05 **Pathophysiological considerations about radiocolloid kinetics in lymphoedema of lower extremities**

Villa G.

17.05-17.10 **Interest and indications of spect-ct for the lympho-scintigraphic investigations of the secondary upper limb edemas (ule)**

Bourgeois P.

17.10-17.15 **On the reliability of tonometry: a pilot study of inter-rater consistency and related psychosocial factors underlying the formulation of tonometric judgments**

Michelini S.

17.15-17.20 **Lymphofluoroscopy-guided manual lymphatic drainage – A new evidence based approach**

Belgrado J.P.

17.20-17.25 **Acoustic Structure Quantification (ASQ): a non-invasive tool to determinate lymphedema tissue changes?**

Tassenoy A.

17.25-17.30 **The value of stemmer's sign and lympho-scintigraphic abnormalities in the diagnosis of lipedema**

Forner-Cordero I.

17.30-17.35 **The occlusion pressure of the superficial lymphatic network – A Near-infrared lymphofluoroscopic approach in the upper extremity of healthy volunteers**

Belgrado J.P.

17.35-17.40 **Near-infra-red (nir) fluorescence imaging of lymphatic vessels and nodes after subcutaneous (sc) injection of free indocyanine green (icg) in one animal model: preliminary results**

Bourgeois P.

17.40-17.55 *Discussion*

16.55-17.55	Workshop 4 (English)
	Auditoire A. Tissot

Chair: Forner-Cordero I. (ES)

PATIENT SELF-CARE

16.55-17.15 **Teaching self-care**

M. Foeldi (DE)

17.15-17.35 **Which physical activity for lymphoedema patients?**

M. Sneddon (UK)

17.35-17.55 **Which physical activity following arm lymphoedema?**

K. Johansson (SE)

16.55-17.55	Workshop 4 (French)
	Auditoire A. Yersin

Chair: M. Depairon (CH)

AUTOGESTION DU LYMPHOEDÈME ET ÉDUCATION DU PATIENT

16.55-17.15 **Education thérapeutique**

S. Vignes (FR)

17.15-17.35 **Quelle activité physique?**

S. Wagner (CH)

17.35-17.55 **L'autobandage**

I. Luthi (CH)

19.30-23.00 **GALA DINNER – OLIMPIC MUSEUM**

June 6 th , Thursday	
Free communications 5	
Auditoire C. Roux	

Chair: M. Matter (CH); F. Boccardo (IT)

- 08.30-08.45 **Chyloperitoneum: modern diagnostic aspects and therapeutic options**
S. Dessalvi (IT)
- 08.45-09.00 **The role of plastic, reconstructive and æsthetic surgery in the treatment of advanced lymphedema-while the early bird catches the worm; the late risers still benefit**
Corrado Campisi (IT)
- 09.00-09.15 **Lymph node transfer in combination with a dieap-flap breast reconstruction by breast cancer related lymphedema: promising or wrong approach?**
K. Seidenstuecker (BE)
- 09.15-09.30 **Heading towards an artificial lymphatic vessel to treat lymphedema**
M. Pisano (CH)

Free communications 6	
Auditoire A. Tissot	

Chair: TBA

- 08.30-08.45 **Diagnostic accuracy of fluorescence microlymphography for detecting limb lymphedema**
H.H. Keo (CH)
- 08.45-09.00 **Study on real-time lymph flow in the lymph vessels of the lower limb by intermittent pneumatic compression in healthy volunteers and lymphedema patients**
J. Maegawa (JP)
- 09.00-09.15 **Measurement of lymphedema: pythagoras vs archimedes vs high-tech**
J.-B. Valsamis (BE)
- 09.15-09.30 **Near-infra-red (nir) fluorescence imaging of «sentinel» lymph nodes in cancers after the intra-venous injection (iv) of free indocyanine green (icg)**
P. Bourgeois (BE)

09.30-11.30	Plenary Session 6
Auditoire C. Roux	

Chair: A Leduc (BE); W. Raffoul (CH)

- LYMPHOEDEMA TREATMENT: WHERE DO WE STAND IN 2015?**
- 09.30-09.55 **Compression treatment**
C. Moffatt (UK)
- 09.55-10.20 **When is liposuction useful?**
H. Brorson (SE)
- 10.20-10.45 **Lymphatic microsurgery: challenges and innovation**
F. Boccardo (IT)
- 10.45-11.10 *Coffee break in the Exhibition*
- 11.10-11.30 **Lymphnode transfer**
C. Becker (FR)
- 11.30-11.55 **Growth factor therapy and autologous lymph node transfer**
A. Saarikko (FI)
- 11.55-12.20 **Manual lymphatic drainage: still useful?**
J.-P. Belgrado (BE)
- 12.20-12.30 **ESL Awards:**
PB Lymphological (*P. Bourgeois*)
Caplan (*F. Boccardo*)
Papamiltiades (*F. Boccardo*)
Tosatti (*C. Campisi*)
- 12.30-12.40 **Closing remarks**
L. Mazzolai (CH)
- 12.40-14.00 *General ESL Assembly (Auditoire C. Roux)*

June 4, 2015 - Auditoire C. Roux

PLENARY SESSION 1

LYMPHATICS IN HEALTH AND DISEASE

LYMPHANGIOGENESIS IN HEALTH AND DISEASE

M. JELTSCH

Translational Cancer Biology Program and Wihuri Research Institute, Biomedicum Helsinki, University of Helsinki, Finland

Despite the intensive research on the lymphangiogenic VEGF-C/VEGFR-3 signaling pathway in the last two decades, new and unexpected findings do not cease to be made. Diseases that involve the lymphatic system have helped to uncover mechanisms of its normal functioning and development.

A recent example of new basic knowledge that resulted from the investigation of a human disease is Hennekam lymphangiectasia-lymphedema syndrome (OMIM 235510). It is an autosomal recessive condition, which can co-segregate with mutations in the collagen- and calcium-binding EGF domains 1 (*CCBE1*) or the protocadherin Fat 4 (*FAT4*) gene.

Both *CCBE1* and the lymphangiogenic vascular endothelial growth factor C (VEGF-C) are necessary for the early lymphatic development, namely for the budding and migration of endothelial cells from the cardinal vein (CV) and for the formation of the early lymphatic structures. These processes fail in embryos deficient of either *Ccbe1* or *Vegfc*. In *Vegfc*-deficient embryos pro-spective lymphatic endothelial cells fail to sprout from the CV, whereas in *Ccbe1*-deficient embryos, the sprouting is abnormal and does not result in the formation of discrete lymphatic structures.

The similar phenotypes of *Ccbe*- and *Vegfc*-deficient embryos result from the interaction of *CCBE1* with the VEGF-C growth factor signaling pathway, which is critical in embryonic and adult lymphangiogenesis. VEGF-C is synthesized as an inactive proprotein and needs to be processed by at least two distinct proteases to become fully active. The presence of *CCBE1* promotes VEGF-C by two independent mechanisms. The C-terminal domain of *CCBE1* boosts VEGF-C function via increased ADAMTS3-mediated proteolytic activation of VEGF-C, while the N-terminal domain of *CCBE1* concentrates pro-VEGF-C on endothelial cell-surfaces, where it can be activated in situ by cell-surface associated proteases. Both mechanisms lead to increased VEGFR-3 signaling and increased lymphangiogenesis.

These results show that *CCBE1* is integral to lymphangiogenesis by increasing the levels of active VEGF-C at the endothelial cell surface. Because some forms of lymphedema appear to be treatable by increasing the amount of VEGFR-3 signaling, the first clinical trials designed around a pro-lymphangiogenic concept use VEGF-C. The goal in these trials is to enhance the integration of lymph nodes into the lymphatic vasculature after autologous transfer to treat postmastectomy lymphedema. On the other hand, VEGF-C-induced lymphangiogenesis enhances tumor metastasis and VEGF-C-induced tumor angiogenesis in several mouse models. Blocking VEGF-C might be for these reasons an attractive adjuvant treatment to supplement current cancer treatment regimens that include anti-angiogenic drugs. The right balance between pro- and anti-lymphangiogenic stimuli might therefore differ between individuals and *CCBE1* is an attractive drug target to adjust pro- and anti-lymphangiogenic stimuli by tuning the rate of VEGF-C activation.

LYMPHATIC VALVES AND BEYOND

T. PETROVA
Switzerland

LYMPHATICS AND ATHEROSCLEROSIS

A. SZUBA
Poland

LYMPHATICS AND VEINS: AN INTIMATE RELATIONSHIP

LEE BB, MD, LAREDO J, MD, AND NEVILLE R, MD

Department of Surgery George Washington University, Washington DC, USA

Venous and lymphatic circulation systems are “inseparable” dual outflow systems to transport the used blood out from the tissue. But these two systems function based on totally different venodynamics and lymphodynamics with entirely different rheodynamic characteristics.

“Normal” lymphodynamic is based on self-propelled peristalsis by each unit of “lymphangion” with positive pressure of 50-60mmHg, while venodynamics is purely based on a passive low-pressure system in average pressure of 10mmHg by heart, diaphragm/breathing, and muscle contraction, etc.

However, once this “normal” lymphodynamics based on peristaltic function of lymphangion should be lost by various conditions, the rheological condition of ‘abnormal’ lymphodynamics becomes essentially same as the venodynamics.

Venous and lymphatic systems are such one mutually interdependent system to provide the compensation to each other that the insufficiency or overload to one of two systems, either transient or permanent, allows the other to play an auxiliary role of fluid return through micro- & macro-anastomosis.

But, both systems are “mutually complimentary” ONLY when they are in normal condition/ function. When one of these two systems should fail (e.g. chronic venous hypertension, lymphedema), the homeostasis/balance between two systems is threatened and such mutual interdependence generates a new problem.

Following initially enhanced lymphatic function to compensate for the insufficient venous system, the lymphatics themselves are damaged and a safety valve insufficiency of lymphatic system would result in lymphostasis.

When the venous insufficiency/stasis exceeds this maximum lymphatic compensatory capacity, the imbalance between capillary as well as tissue blood-lymphatic pressure will build up the liquid in the interstitial space together with the concentration of intra-extravascular proteins to lead characteristic fibrosis due to increased interstitial protein concentration.

Hence, a failure of one system gives additional burdening/loading to the other system, and a long term one system failure results in total failure of these ‘inseparable’ dual systems altogether and the insufficiency becomes “phlebolympathic”, generating a new condition of “combined”.

June 4, 2015 - Auditoire C. Roux

PLENARY SESSION 2 LYMPHATIC MALFORMATIONS AND GENETICS

GENETICS OF LYMPHOEDEMA: ONE SYMPTOM, MANY CAUSES

P. OSTERGAARD

St. George's, University of London, UK

We have demonstrated that stringent phenotyping can be helpful in gene identification. Building on 14 years of experience in our Primary Lymphoedema Clinic at St George's Hospital, London, an updated classification of this condition has been proposed. This new tool has been useful in our research department and we have had success in identifying genes for Primary Lymphoedema using this rigorous phenotyping combined with linkage analysis, Sanger sequencing and/or Whole Exome Sequencing. In this talk, this classification tool will be presented with examples of the various genetic causes of Primary Lymphoedema.

GENETICS ASSESSMENT OF PRIMARY LYMPHOEDEMA

MICHELINI S.¹, BRUSON A.², CARDONE M.¹, SIROCCO F.², FIORENTINO A.¹, CECCHIN S.², SAINATO V.¹, BERTELLI M.²

¹ Ospedale San Giovanni Battista - ACISMOM, Rome (IT); ² MAGI'SLAB - Rovereto (IT)

Introduction: Up to date, no one can say that all primary lymphedema are of genetic origin. We know the genetic familial forms (VEGFR and FOXC2) and some cases in which these two genetic mutations are also present in clinical 'sporadic' cases. But this does not mean that other causes, besides mutations genetically passed (so-called Mendelian), may induce alterations in the protein sequencing on the DNA of an embryo for various reasons (such as radiations, drugs – for example thalidomide in phocomelics - and perhaps many other causes or contributing factors).

Materials and methods: In our experience of a total of one thousand one hundred thirty four patients with primary lymphoedema, 7.6 percent presented the disease at the birth, in the 3.8 percent it appeared before the second decade of life and about 90 percent it appeared from the third decade of life.

Again in our casuistry of 220 probands, 3.9 percent of patients with primary lymphoedema submitted a positive family history, 6.0 percent belonged to syndromic lymphoedema and 90 percent appeared as sporadic forms.

Results: Among the enrolled probands with clinical diagnosis of primary lymphoedema, a positive family history was documented in 42 individuals, while regarding the remaining ones we do not have any news. By direct sequencing of exons 17-26 of the gene VEGFR3, including adjacent intronic regions and the only exon of the gene FOXC2, including intronic regions adjacent, have been indentified 12 different not common nucleotide change in 12 patients (nine are new alterations): six nucleotide alterations are located within the FLT4 gene (13% of cases) and the same number (13%) within the FOXC2 gene. These nucleotide changes were absent in 100 healthy subjects. In 8 of these 12 patients it was documented a positive family history. Other mutated genes discovered in probands were: KIF 11, GJC2, GATA2, HGF. The study is going on the families. In two cases we found a genetic mutation never described in literature: one in the codon 286 of gene VPR2 and the other in codon 5 of gene FLT4. The association between the mutation and the phenotype of lymphoedema is not clear and it will be further developed in other members of the same families, analyzing the problem.

Conclusions: This double clinical and genetic assessment allows us to decide the more appropriate management of patient and his/her family and could also provide the possibility of determining transmission risks; enabling application to prenatal diagnosis.

COMBINED PRIMARY LYMPHOEDEMA AND OTHER VASCULAR MALFORMATIONS

LEE BB, MD, LAREDO J, MD, AND NEVILLE R, MD

Department of Surgery George Washington University, Washington DC, USA

Introduction: Primary lymphedema represents the clinical manifestation of defective development of lymph-transporting system affecting lymph vessels and/or lymph nodes. It is therefore, one of the lymphatic malformations (LMs) involved to the "later" stage of lymphangiogenesis while lymphatic vessel trunks are formed.

Hence, the matured lymphatic vessels/nodes are directly involved as various extents of defective condition: hypoplasia, hyperplasia, and aplasia. And they were classified/named to "truncular" LM lesions.

However, when the developmental arrest should occur in the 'earlier' stage before the stage of vessel trunk formation, it maintains the primitive structure of reticular network and remains as a amorphous vascular cluster. They were named to "extratruncular" LM lesions. Traditionally, they were called as "lymphangioma" and more specifically to "cystic hygroma" for the head & neck cases.

Nevertheless, the most unique condition "extratruncular" LM lesions have as an embryonic tissue remnant is the mesenchymal cell characteristics to grow through the rest of life when the condition should meet with adequate stimulation (e.g. menarche, pregnancy, hormone, trauma, and surgery).

For such condition/milieu to cause the defective development in the later stage of lymphangiogenesis to result in "primary" lymphedema, there is always a good risk to have similar defective development in the earlier stage of the lymphangiogenesis to result in "lymphangioma".

Logically, there is same risk of defective development not only in the lymphatic system through two different stages of the lymphangiogenesis but also in the venous, arterial and capillary systems.

Such condition of combined vascular malformations has been newly classified to Hemolymphatic malformation (HLM) consisted of various vascular malformations: venous malformation (VM), arterio-venous malformation (AVM), and/or capillary malformation (CM).

Through gone era of old concept based on name-based eponyms, this unique condition of VM, LM, and CM coexisting simultaneously, was called "Klippel-Trenaunay syndrome (KTS)" while another condition with additional AVM was called "Parkes Weber syndrome (PWS)" to differentiate these two different conditions.

Although the majority of LM lesion exists as an independent form of the vascular malformation, infrequently both truncular and extratruncular LM lesions coexist and also further with other vascular malformations to form a HLM.

Conclusion: Proper identification of two different embryological subtypes is mandated not only for proper management of primary lymphedema as one of the LMs but also for all other congenital vascular malformations (CVMs). Especially when primary lymphedema/truncular LM is identified as one of the many different vascular malformation components of KTS or PWS, proper evaluation of other coexisting CVMs is as important as the LM itself.

June 5, 2015 - Auditoire C. Roux

PLENARY SESSION 3

LYMPHATICS' IMAGING

WHICH ROLE FOR LYMPHOSCINTIGRAPHY IN CLINICAL PRACTICE?

P. BOURGEOIS

Institute Jules Bordet, Brussels, Belgium

LYMPHATIC LEAKAGE ANALYSIS BY CT LYMPHOGRAPHY

P. BIZE

Switzerland

Learning objectives: To know the technique of CT lymphography and alternative imaging modality of the central lymphatic system.
To know the information that CT lymphography can provide and its limitation.
To know the treatment options that interventional radiology has to offer in case of lymph leakage.

Abstract: 20 years ago the percutaneous pedal lymphangiography was the imaging gold standard to study the lymphatics of the lower limbs and abdomen. Today CT lymphangiography where lipiodol is injected in inguinal lymph nodes under US guidance before a performing a thoraco-abdominal CT had become a valuable alternative to the previous invasive technique. Heavily T2 weighted images can also depict lymphatics of the lower body especially in cases of obstruction.

CT lymphography not only allows the location of the leakage in most cases but allows CT guided puncture, catheterization and embolization of the affected lymphatic, offering an interesting alternative to laparoscopic or thoracoscopic ligation.

IS THERE A FUTURE FOR ICG-FLUOROSCOPY IN CLINICAL PRACTICE?

J.-P. BELGRADO

Université Libre de Bruxelles, Lymphology Research Unit, Bruxelles, Belgium

IS THERE A FUTURE FOR ULTRASOUND IMAGING IN LYMPHOEDEMA DETECTION AND CHARACTERIZATION?

S. MESTRE GODIN

France

June 5, 2015 - Auditoire C. Roux

PLENARY SESSION 4

IMMUNE CELLS, LYMPHATICS, AND CANCER: FROM BENCH TO BEDSIDE

LYMPHATICS AND CELLULAR TRAFFICKING

C. HALIN WINTER

Switzerland

TUMOR-ASSOCIATED LYMPHATIC VESSELS AND THE SENTINEL LYMPH NODE: NEW INSIGHTS FOR POTENTIAL THERAPEUTIC TARGETS

M. SWARTZ

Switzerland & USA

LYMPHATIC MICROSURGERY (LYMPHA) FOR CANCER-RELATED LYMPHOEDEMA PREVENTION

BOCCARDO F., CAMPISI C.C., MOLINARI L., SPINACI S., DESSALVI S., CAMPISI C.

Unit of Lymphatic Surgery (Chief: Prof. C. Campisi), Department of Surgery, IRCCS S. Martino – IST National Cancer Institute, University of Genoa, Italy

Introduction: The purpose of this manuscript is to assess the efficacy of direct multiple lymphatic-venous anastomoses (MLVA) in the prevention of peripheral lymphedema following axillary and groin lymph nodal dissection.

Materials and Methods: Authors report their clinical experience in treating patients with operable breast cancer, skin melanoma of the trunk and vulvar cancer requiring axillary and/or nodal dissection by carrying out MLVA between the blue lymphatics (from the arm or the leg) and a vein branch (collateral of the axillary or the great saphenous vein) simultaneously. Short and long term follow-up included circumferential measurements in all cases, lymphangitic attacks and lymphangioscintigraphy.

Results: Blue nodes in relation to lymphatic arm or leg drainage were identified. All blue nodes were resected anyhow and 2-4 main afferent lymphatics from the extremity could be prepared and used for anastomoses. Multiple lymphatic-venous anastomosis allowed to prevent secondary lymphedema. Lymphangioscintigraphy demonstrated the patency of microvascular anastomoses.

Conclusions: Disruption of the blue nodes and closure of arm lymphatics can explain the significantly high risk of lymphedema after axillary and groin dissection. MLVA proved to be a safe procedure for risk patients in order to prevent lymphedema of extremities.

LYMPHATIC MAPPING PRIOR TO SENTINEL NODE BIOPSY

M. MATTER

Switzerland

June 5, 2015 - Auditoire C. Roux

PLENARY SESSION 5 PATIENT EDUCATION AND LYMPHOEDEMA IN PARTICULAR SITUATIONS

EFFECTIVENESS OF PATIENT EDUCATION

M. SNEDDON

United Kingdom

INTERACTIONS BETWEEN OBESITY AND LYMPHEDEMA

S. VIGNES

Department of Lymphology, Centre National de Référence des Maladies Vasculaires Rares (Lymphoedèmes Primaires), Hôpital Cognacq-Jay, Paris, France

Obesity is defined as body mass index (BMI) exceeding 30 kg/m². Interactions between lymphedema and weight were mostly studied in women after breast-cancer treatment and involve several fields. Among physiopathological mechanisms, which remain partially unelucidated, lymph accumulation leads to adipocyte and fibroblast activation, and subsequently to fibrosis and excess adipose tissue. Notably, obesity increases 3.6-fold the risk of developing upper limb lymphedema after breast-cancer therapy. Post-treatment weight variations (gain/loss) are also a risk factor and weight gain may also be considered a risk factor. For women with lymphedema, increasing BMI corresponded to lymphedema volume, i.e., its severity. Lymphedema management is essentially based on complex decongestive physiotherapy. During the first intensive phase, obesity is a factor negatively influencing lymphedema-volume reduction. During the maintenance phase, re-increasing lymphedema volume is associated to BMI independently of compliance (wearing an elastic sleeve, low-stretch bandage). For obese women with breast cancer-related lymphedema, weight loss had a demonstrated positive impact on decreased lymphedema volume. In conclusion, preventing obesity is essential to limiting lymphedema in women with breast cancer. Lymphedema management should also include weight control and weight loss, if necessary, with adapted diet. Further studies are needed to confirm these results for primary and secondary lower limb lymphedema, after pelvic cancer treatment.

Key words: obesity, lymphedema, breast cancer.

LYMPHOEDEMA IN CHILDREN

I. QUERÉ
France

MANAGEMENT OF PATIENTS WITH ARM LYMPHOEDEMA FOLLOWING BREAST CANCER SURGERY

M. FOELDI
Germany

June 6, 2015 - Auditoire C. Roux

PLENARY SESSION 6

LYMPHOEDEMA TREATMENT: WHERE DO WE STAND IN 2015?

COMPRESSION TREATMENT

C. MOFFATT
United Kingdom

WHEN IS LIPOSUCTION USEFUL?

HÅKAN BRORSON, MD, PhD, Associate Professor (Lund University), Professor (EGAMA, Buenos Aires), Senior Consultant Plastic Surgeon, KARIN OHLIN, OT, BARBRO SVENSSON, PT, LT, Lymphedema Center, Department of Clinical Sciences, Lund University, Plastic and Reconstructive Surgery, Skåne University Hospital, SE-205 02 Malmö - Email: hakan.brorson@med.lu.se, Fax: +46-706-46 38 38

Lymphedema leads – already within the first year – to deposition of subcutaneous adipose tissue. Liposuction for non-pitting chronic large lymphedemas is useful when patients have been optimally managed with conservative treatment in order to transform a pitting edema to a non-pitting edema. If the excess volume – now comprising of excess adipose tissue – is still bothering liposuction is an excellent option leading to complete reduction. Just as after conservative treatment compression garments are needed postoperatively. Microsurgical reconstructions, although attractive as a physiological concept, cannot provide complete reduction in chronic large non-pitting lymphedemas because they do not eliminate the newly formed subcutaneous adipose tissue collections. The long-term outcomes of liposuction of arm and leg lymphedema are presented.

Twenty years' experience of complete reduction of arm lymphedema following breast cancer

Introduction: Patients with chronic non-pitting lymphedema do not respond to conservative treatment probably because diminished lymph flow and inflammation result in the formation of excess subcutaneous adipose tissue. Previous surgical treatments utilizing either total excision with skin grafting or reduction plasty seldom achieved acceptable cosmetic and functional results.

Materials and Methods: 142 women with non-pitting edema, a mean age of 64 (range, 39-89) years and a mean duration of arm swelling of 9 (range, 1-38) years underwent liposuction. Mean age at breast cancer operation, mean interval between breast cancer operation and lymphedema start, and duration of lymphedema were 52 years (range, 33-86), 3 years (range, 0-32), and 9 years (range, 1-38) respectively. Aspirate and arm volumes were recorded (Figure 1a, b).

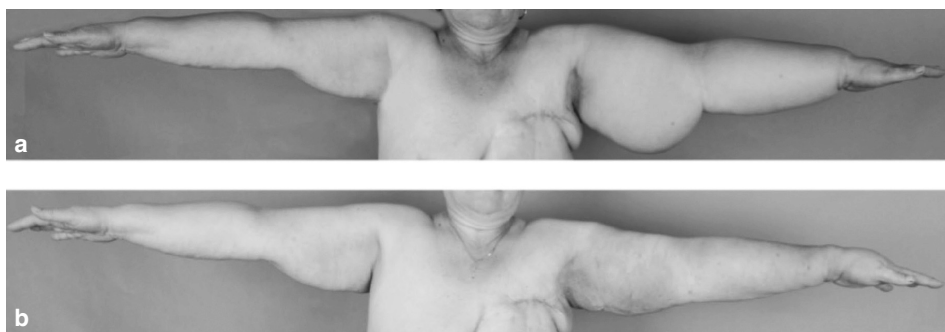


Fig. 1 - A 57-years-old woman with a non-pitting secondary leg lymphedema of 4 235 ml since 5 years following breast cancer treatment. Complete reduction 6 months after liposuction (below).

(to be continued)

Results: Aspirate mean volume was 1819 ml (range, 650-3850) with an adipose tissue concentration of 94 % (range, 58-100). Preoperative mean excess volume was 1566 ml (range, 545-3915). Postoperative mean reduction was 103 % (range, 50-194) at 3 months and more than 100% during 20 years' follow-up, i.e. the lymphedematous arm was somewhat smaller than the healthy arm. The preoperative mean ratio between the volumes of the edematous and healthy arms was 1.5, rapidly declining to 1.0 at 3 months, and less than 1 after one year (Figure 2).

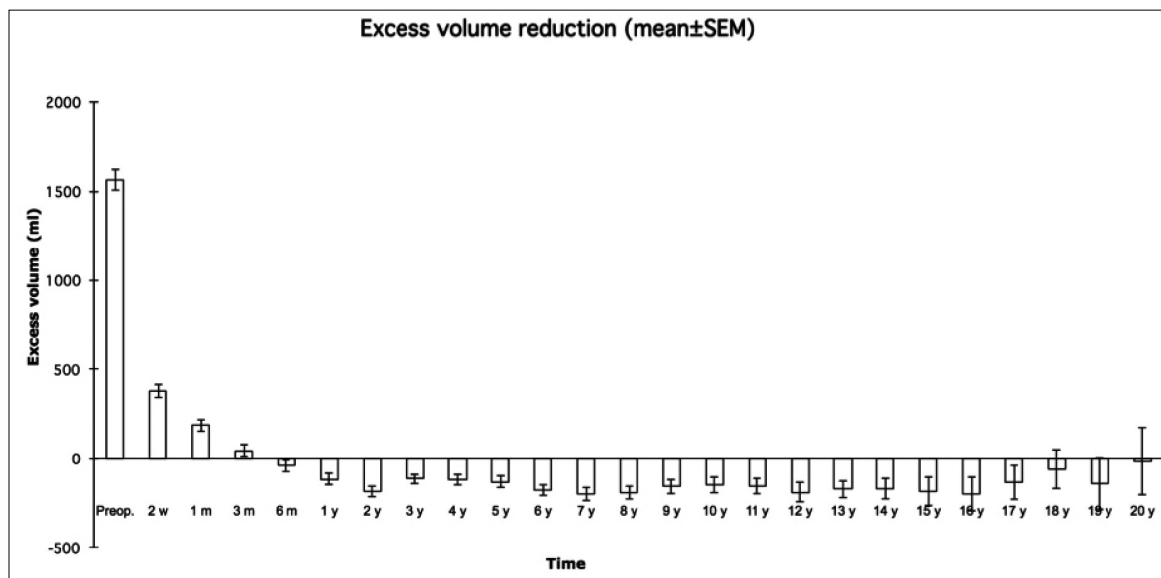


Fig. 2 - Mean pre- and post-operative excess volume reduction.

Conclusion: These long-term results demonstrate that liposuction is an effective method for treatment of chronic, non-pitting arm lymphedema in patients who have failed conservative treatment. Because of adipose tissue hypertrophy, it is the only known method that completely reduces excess volume at all stages of arm lymphedema. The removal of hypertrophied adipose tissue, induced by inflammation and slow or absent lymph flow is a prerequisite to complete reduction. The newly reduced volume is maintained through constant (24-hour) use of compression garments postoperatively.

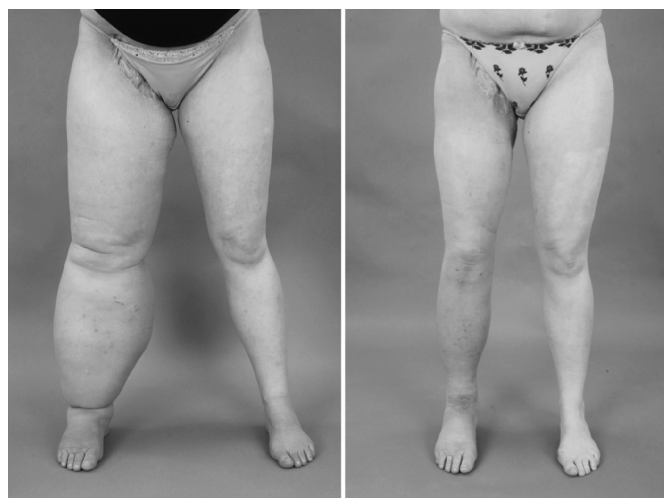Complete reduction of lymphedema induced adipose tissue hypertrophy in elephantiasis of the leg – a prospective study with a ten-year follow-up

Introduction: Patients with long-standing pronounced non-pitting lymphedema do not respond to conservative treatment or microsurgical procedures because slow or absent lymph flow, as well as chronic inflammation, cause the formation of excess subcutaneous adipose tissue, which cannot be removed by these methods. The swelling of chronic non-pitting arm lymphedema following breast cancer, can be completely reduced by liposuction and has not recurred during more than nineteen years' follow-up. Encouraged by this experience, we decided to test the effectiveness of liposuction on leg lymphedema.

Materials and Methods: 56 patients with an age of 52 years (range, 17-76) and a duration of leg swelling of 14 years (range, 2-50) underwent liposuction due to non-pitting, chronic lymphedema. There were 29 primary (PL), and 27 secondary lymphedemas (SL) following cancer therapy. Age at cancer treatment and interval between cancer treatment and lymphedema start were 43 years (range, 20-65), and 3 years (range, 0-26) respectively. Age at onset of PL was 32 years (range, 4-63). All patients had received conservative treatment before surgery without further reduction. All were wearing compression garments before surgery. Aspirate and leg volumes were recorded.

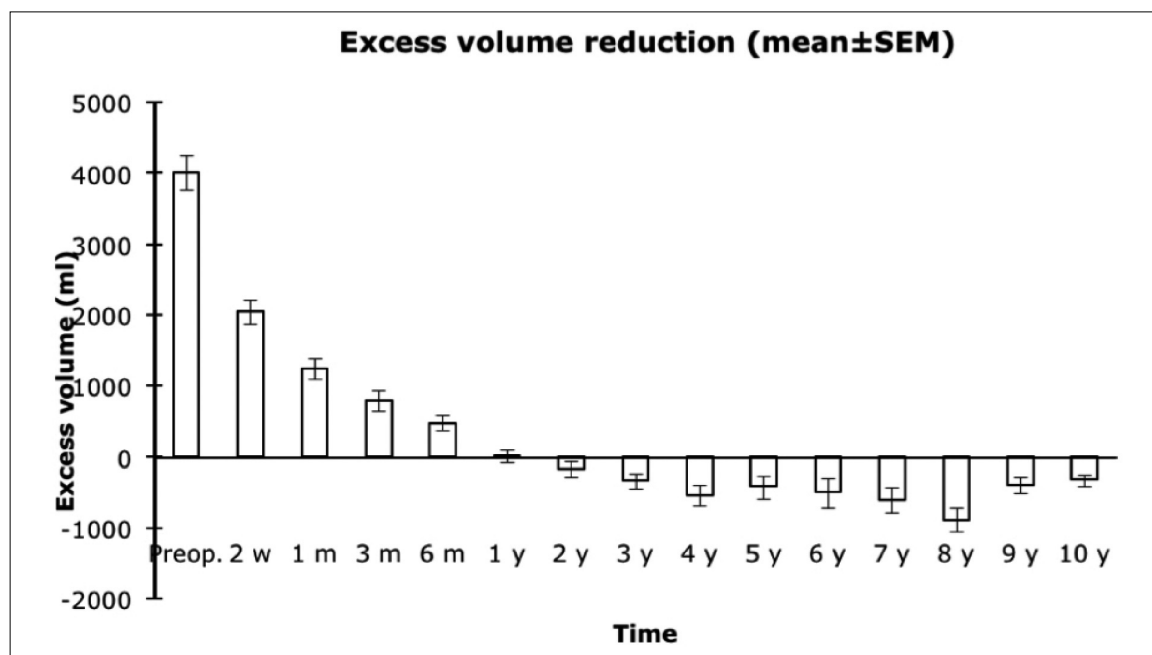
Results: Aspirate volume was 3872 ml (range, 1210-8475) with an adipose tissue concentration of 94% (range, 61-100). Preoperative excess volume was 3935 ml (range, 1200-8475). Postoperative mean reduction was 83% (range, 22-135) at 3 months and 104% (range, 75-163) at 1 year, and more than 100% during 10 years' follow-up when it was 115% (range, 112-119), i.e. the lymphedematous leg was somewhat smaller than the healthy one (Figure 1 and 2).

Fig. 1 - A 32-years-old woman with a non-pitting secondary leg lymphedema of 7 070 ml since 12 years following treatment of a synovial sarcoma in the right groin (left). Postoperative results 6 months after liposuction (right).



(to be continued)

Fig. 2 - Mean pre- and post-operative volume reduction.



The preoperative mean ratio between the volumes of the edematous and healthy legs was 1.4, rapidly declining to 1.0 at 1 year and less than 1 after one year.

Conclusion: Liposuction is an effective method for treatment of chronic, non-pitting leg lymphedema in patients who have failed conservative treatment. It is the only known method that completely reduces excess volume at all stages of lymphedema. The removal of hypertrophied adipose tissue is a prerequisite to complete reduction. The reduced volume is maintained through constant use of compression garments.

LYMPHATIC MICROSURGERY: CHALLENGES AND INNOVATION

BOCCARDO F, CAMPISI CC, MOLINARI L, SPINACI S, DESSALVI S, CAMPISI C

Unit of Lymphatic Surgery-Department of Surgery-IRCCS S. Martino – IST National Cancer Institute-University of Genoa, Italy

Introduction: This study aimed to report new clinical approaches to the treatment of lymphatic disorders by microsurgical techniques based on histological and immunohistochemical findings. The authors' wide clinical experience in the treatment of patients with peripheral lymphedema by microsurgical techniques is reported.

Materials and Methods: Microsurgical methods included derivative multiple lymphatic-venous anastomoses injecting the BPV dye in different areas according to lymphedema stage and based on lymphoscintigraphic findings. In all patients, lymphatic and lymph nodal tissues were sent for histological assessment, together with specimen of the interstitial matrix. Diagnostic investigations consisted in venous duplex scan and lymphoscintigraphy. Results were assessed clinically by volumetry performed preoperatively and postoperatively at 3 to 6 months and at 1, 3, and 5 years.

Results: The outcome obtained in treating lymphedemas at different stages was analyzed for volume reduction, stability of results with time, reduction of dermatolymphangioadenitis attacks, necessity of wearing elastic supports, and use of conservative measures postoperatively.

Conclusions: Microsurgical multiple lymphatic-venous derivative techniques allow bringing about positive results in the treatment of peripheral lymphedema, above all in early stages when tissular changes are slight and allow almost a complete restore of lymphatic drainage.

LYMPHNODE TRANSFER

CORINNE BECKER

France

The free lymph node transfers seem to be an effective treatment to replace the nodes removed for oncologic reasons, in the upper or lower extremity.

Congenital lymphedema due to a hypoplastic lymphatic system, are responding to the autologous lymphnodes transplantation. Why?

The reason is: The lymphnodes are pumping the liquid, they also contain lymph growing hormones which promote the growth of the new lymphatic vessels.

Moreover, they serve as bacteria filters so the patients are able to fight chronic infections

This technique consists in a free fascial fatty flap containing some lymph nodes.

The evaluation is performed by lymphoMRI, which can show the deep and superficial network with high sensibility.

The indications of ALNT for iatrogenic cases are:

- absence of pathways visible at the lymphoMRI
- pain, palsy
- breast reconstruction wished
- chronic infections

For the congenital cases, this technique helps the hypoplastic cases, improving the number of nodes and lymphatic vessels.

The results are shown, comparing the clinic and the lymphoMRI.

Combinations of different techniques are to be considered, but it always must be in a logical approach. A multidisciplinary evaluation is the key.

GROWTH FACTOR THERAPY AND AUTOLOGOUS LYMPH NODE TRANSFER

A. SAARIKKO

Finland

MANUAL LYMPHATIC DRAINAGE: STILL USEFUL?

J.-P. BELGRADO

Université Libre de Bruxelles, Lymphology Research Unit, Bruxelles, Belgium

FREE COMMUNICATIONS 1

RANDOMIZED CLINICAL TRIAL COMPARING BCRL AND QOL BETWEEN BREAST CANCER PATIENTS TREATED WITH SHORT COURSE IMAGE GUIDED RT AND CONVENTIONAL POST SURGERY RT

ADRIAENSSENS N.³, LAMOTE J.¹, VAN PARIJS H.², MIEDEMA G.², VOORDECKERS M.², ERSMESSEN H.², DE RIDDER M.², STORME G.², LIEVENS P.³, PAS R.³, MEERHOUT C.³, DE GRÈVE J.⁴, FONTAINE C.⁴, VINH-HUNG V.²

¹ Universitair Ziekenhuis Brussel, Breast Cancer Center, Brussels (BE); ² Universitair Ziekenhuis Brussel, Department of Radiation Oncology, Brussels (BE);

³ Vrije Universiteit Brussel, Physical Therapy Department, Brussels (BE); ⁴ Universitair Ziekenhuis Brussel, Breast Cancer Center, Brussels (BE)

Introduction: Breast cancer related lymphedema (BCRL) is a well-known complication of breast cancer surgery and radiotherapy (RT) that influences health-related quality of life (HRQOL). The consequences of choosing one RT technology over another for the onset of BCRL are not clearly defined. In the present study, early breast cancer patients are randomized to compare the incidence of BCRL of the arm and the influence on HRQOL between conventional RT and short-course, image-guided RT (IGRT) treatments.

Materials and Methods: Early breast cancer patients were randomized between post surgery IGRT over 3 weeks and conventional RT over 5 to 7 weeks, as part of the TomoBreast trial (ClinicalTrials.gov registration NCT00459628). BCRL and HRQOL were assessed prior to, between 1 and 3 months and every year up to 3 years following RT. BCRL was measured by tape measure in a standardized protocol. Outcome measures were absolute volume of the operated-radiated side (ORS), relative interlimb difference (RID) and subjective arm symptoms. HRQOL was measured using the EORTC (European Organisation for Research and Treatment of Cancer) QLQ-C30 & BR23 questionnaires. Statistical analyses will be discussed during the presentation.

Results: Results of 120 evaluable patients found that < 55% reported subjective arm symptoms at 3 years follow-up, compared to > 80% at baseline measure. However, there was no significant difference in BCRL incidence between the treatment groups. Absolute volume of the ORS changed significantly ($p = .011$) over time, with a peak volume at 1 year follow-up. RID increased significantly ($p = .004$) over time. There was no significant difference in absolute volume of ORS and RID between the treatment groups. No significant difference was found in HRQOL between the treatment groups, except for the dimension 'global health status' ($p = .022$). The conventional therapy group scored significantly better than the IGRT group. Prior to treatment, there was no correlation between RID and the different dimensions of the EORTC QLQ-C30 & BR23. At each post RT measurement, 'arm symptoms' were positively correlated with RID (respectively $p = .001, .004, .003, .000$). At 1 year post RT, patients with a higher RID suffered from more financial difficulties ($p = .042$), more systemic side effects ($p = .038$) and a lower body image ($p = .008$). The financial difficulties were also related with RID at 2 years post RT ($p = .005$). A high RID at 3 years follow-up was correlated with lower physical functioning ($p = .013$).

Conclusions: Up to 3 years following RT, short-course IGRT neither caused increased incidence of BCRL, nor decreased HRQOL compared to conventional RT. Although confirmation requires longer follow-up, these results support the use of a short-course RT schedule.

LIPOFILLING OF THE AXILLA TO REDUCE SECONDARY LYMPHEDEMA AFTER AXILLARY LYMPH NODE DISSECTION

VANDERMEEREN L.¹, BELGRADO J.-P.², VANKERCKHOVE S.¹, VALSAMIS J.-B.², MORAINÉ J.-J.², HERTENS D.¹, CARLY B.¹, LIEBENS F.¹

¹ C.H.U. St-Pierre, Bruxelles (BE); ² Université Libre de Bruxelles (BE)

Introduction: Complete axillary lymph node dissection (cALND) remains a high risk factor to trigger delayed secondary lymphedema. Specialists still investigate the precise reasons why only a limited number of patients develop a breast cancer related lymphedema (BCRL) after cALND. Clearly, ALND is a mandatory but not always a sufficient condition to trigger a lymphedema.

The BCRL physiopathology is complex and multifactorial; venous and microcirculatory impairment also needs to be considered. During surgery, adipose tissue surrounding the axillary vein is partially or completely removed and the axillary sheath can also be damaged. As previously pointed out by our team, this anatomical disruption could affect the local hemodynamic condition, with as a consequence an increased microvascular filtration at the distal part of the affected limb. Thanks to a set of clinical signs and an original imaging technique, developed in our clinic, we are able to identify those patients with axillary hemodynamic impairment associated with secondary lymphedema. We propose an original and simple surgical approach that could partially restore this hemodynamic impairment.

Material and Methods: Breast cancer patients with longer existing secondary lymphedema and with positive clinical signs for hemodynamic changes in the affected limb, were surgically treated with lipofilling of the axilla. All patients were enrolled in the study protocol (EudraCT n° 2015- 001565-37) with alternating rest, intensive and regular, but standardized, physiotherapy. Water displacement and perimetry techniques were used to measure edematous and normal limb, before the operation and after completion of the study protocol of 44 days. Subjective symptoms as numbness, heavy arm, pain, tension of the skin, were also evaluated. Approval of the patient's oncologists and ethical committee was obtained for every patient.

Results: 34 patients underwent the surgical intervention. Edema volume reduced significantly in the majority of patients. This reduction was already observed directly after surgery and before starting physiotherapy. Subjective symptoms like heavy arm, numbness, and functional impairment of the upper limb in daily activities started to decrease directly after the operation and continued to decrease after the end of the study protocol. Most of the patients decided not to wear the compression garments anymore, because there was no more change in volume of the arm with or without their use, after the operation. After one year of follow up, we do not record any complications. Details of our findings will be presented at time of presentation.

Conclusion: Lipofilling of the axilla seems to be a simple, fast, cost-effective and efficient surgical approach, and could be introduced as a part of the treatment of secondary upper limb lymphedema after cALND in patients with axillary hemodynamic impairment.

LIPOSUCTION OF POSTMASTECTOMY ARM LYMPHEDEMA DECREASES THE INCIDENCE OF ERYSIPELAS

BRORSON H.², LEE D.¹, PILLER N.¹, HOFFNER M.²

¹ Lymphoedema Research Unit, Department of Surgery, School of Medicine, Flinders University, Adelaide (AU); ² Lymphedema Center, Department of Clinical Sciences, Lund University, Plastic and Reconstructive Surgery, Skåne University Hospital, Malmö (SE)

Introduction: The objective of this study was to assess erysipelas incidence before and after liposuction, a treatment for patients suffering from post-mastectomy lymphedema.

Methods and Results: A prospective cohort study of 130 patients at Skåne University Hospital in Malmö, Sweden with postmastectomy arm lymphedema, who had poor outcomes from prior conservative treatment and clinical signs of subcutaneous adipose tissue hypertrophy underwent liposuction between 1993-2012. Pre- and postoperative bouts of erysipelas were available for all of them. Mean duration of lymphedema prior to liposuction was 8.8 years (range 1-38, standard deviation (SD) 7.0 years). Mean age at liposuction was 63 years (range 39-89, SD 10 years). Total pre liposuction observation years were 1147, and total post-liposuction observation years were 983. Erysipelas incidence dropped from 0.47 attacks/year (range 0-5.0, SD 0.8 attacks/year) to 0.06 attacks/year (range 0-3.0, SD 0.3 attacks/year) after liposuction, a reduction of 87%. Also, compared to 76 patients who experienced at least 1 erysipelas episode preoperatively, only 19 patients experienced erysipelas postoperatively. Of the 54 patients who did not have erysipelas preoperatively, 6 patients had erysipelas postoperatively. The total number of erysipelas attacks observed decreased from 534 to 60 bouts after liposuction.

Conclusion: Liposuction significantly reduced the incidence of erysipelas in patients with post mastectomy arm lymphedema who prior to the intervention suffered one or more attacks.

LYMPHATIC COMPLICATIONS CONTROL FOLLOWING INGUINAL AND AXILLARY RADICAL LYMPH NODE DISSECTION: A RANDOMIZED CONTROLLED TRIAL

MATTHEY-GIÉ M.-L., GIÉ O., DERETTI S., DEMARTINES N., MATTER M.

CHUV, Lausanne, Switzerland

Background: Many attempts to prevent lymphatic complications following radical lymph node dissection (RLND) have included modifications in surgical techniques by the use of ultrasonic scalpels or injection of lymphostatic agent. Previous randomized studies, enrolling heterogeneous groups of patients, tried to confirm the efficacy of such techniques. The aim of this present study was to evaluate the efficacy of the Harmonic scalpel for RLND.

Methods: Between 2009 and 2013 in a tertiary academic centre, patients undergoing inguinal or axillary RLND or completion lymph node dissection after positive sentinel lymph node biopsy (SLNB) for melanoma or sarcoma, were randomized in a controlled trial comparing two surgical dissection techniques. In group HS dissection was conducted with Harmonic Scalpel and in group control (C) by ligation and monopolar electrocautery. For axillary dissection a standardized level III lymphadenectomy was routinely performed. A complete inguinal lymphadenectomy including Cloquet's node was performed in the groin. At the end of the procedure, one closed Redon suction drain was systematically placed in the armpit and in the groin respectively. Our primary endpoint was to compare the time until drain removal in both groups. The secondary endpoint was to evaluate the rate of complications (infection, fistula, lymphocele formation, wound dehiscence, lymphedema) in both groups.

Results: 80 patients were enrolled in this trial. 40 patients were randomly assigned in group HS and C respectively. No significant difference was observed in term of duration of drainage (H: 30.91±19.6 vs. C: 31.9 ±17.56, p=0.83). A significant increased rate of lymphoedema (defined as an increased circumference of the operated limb of more than 10%) was identified in group H (H: 50% vs. C: 20.5%, p=0.04). No other difference was recorded for postoperative complication as surgical site infection (H: 5% vs. C: 7.5%; p=0.68); lymphatic fistula (H: 5% vs. C: 2.5%; p=0.62); lymphocele (H: 32.5% vs. C: 22.5%; p=0.33) and hematoma (H: 5% vs. C: 2.5%; p=0.62).

Conclusion: The use of harmonic scalpel failed to offer a significant reduction for length of drainage and operative complication, even an increased rate of lymphoedema was observed. Thus, "traditional" surgical management can be used safely in RLND.

FREE COMMUNICATIONS 2

A NEW METHOD FOR MEASURING DEEP TISSUES TONOMETRY IN LYMPHEDEMA

ZALESKA M.¹, OLSZEWSKI W. L.¹, KACZMAREK M.²

¹ Central Clinical Hospital, Medical Research Center, Warsaw (PL); ² Kazimierz Wielki University, Bydgoszcz (PL)

Introduction: Edematous tissue has viscoelastic properties of a sponge. Measuring elasticity using tonometers may provide useful data not only for setting intermittent pneumatic compression at levels allowing initiation of edema fluid flow but also assessment of therapeutic compression results. The so far used tonometers with indentation of 3 mm measure elasticity of skin but not of the subcutaneous tissue, where the bulk of edema fluid is located. Moreover, no information is obtained how high pressure is generated during tonometry in the tissue. We designed a tonometer with a 10mm long, plunger reaching subcutis, so that the force necessary for moving deep located fluid could be measured and an intra-tissue pressure sensor to assess the effect of external force on fluid pressure.

Aim: To measure simultaneously tissue tonicity and tissue edema fluid pressure underneath the tonometer. The obtained data would provide information how high compression (bandage, stockings, intermittent pneumatic compression) pressures should be applied to move edema fluid.

Material and methods: Forty patients with lymphedema of lower limbs stage II-IV were studied. Tonometer plunger 10 mm long, pressing area 1sq.cm, time of pressing to reach 10 mm deep in 5 sec was used. Force was read off on the scale. Pressure sensor was placed in the subcutaneous tissue under the tonometer. Measurements were taken above ankle, mid-calf, below and above knee and mid-thigh. Applied force was plotted against tissue fluid pressure.

Results: Tonometer force of 500g/sq.cm generated edema fluid pressures around 30mmHg. Those of 1000g/sq.cm 50 mmHg. However, in cases with hard skin force of 2500 g/sq.cm produced only 40-70 mmHg. This means in order to obtain the minimum 30 mmHg to move fluid in the tissue higher external forces should be applied: tonometry up to 1.0 – calf compression pressure 50 to 60 mmHg, 1.1 to 2.0 - 60 to 90 mmHg, above 2.1 - 90-120 mmHg. Elasticity of lower limbs tissue was lower in the calf with more hard skin than in the thigh.

Conclusions: Deep tonometry is indispensable for: 1. setting pneumatic device at effective level to move tissue fluid, 2. evaluating effect of IPC by pre- and post treatment measurements (increase of elasticity), 3. evaluating the postoperative effects of lympho-venous shunts (increase of elasticity).

EVALUATION OF THE AXILLARY WEB SYNDROMES (AWS) BY LYMPHOSCINTIGRAPHIS IMAGINGS

LEDUC O.^{1,3}, LEMOINE M.², GOBILLARD A.², HARDY M.², MAIRE S.¹, HIGUET M.¹, DEWILDE J.², BERNARD F.², VAES H.², BADII N.², ADRIAENSSENS N.⁴, LEDUC A.¹, BOURGEOIS P.³

¹ Lympho-phlebology Unit, Department of occupational and environmental physiology, Haute Ecole P. H. Spaak, Brussels (BE); ² Departement of Physical Therapy, Institut Jules Bordet, Université Libre de Bruxelles (BE); ³ Department of Nuclear Medicine and Clinic of Lymphology, Institut Jules Bordet, Université Libre de Bruxelles (BE); ⁴ Department of Physical therapy Vrije universiteit Brussel and Oncology department UZ Brussel (BE)

Introduction: The Axillary Web Syndrome (AWS) follows surgery for breast neoplasia and consists in the appearance of one or more frequently two or three cords of subcutaneous tissue. Strings originate from the axilla, spread to the antero-medial surface of the arm down to the elbow and then move into the antero-medial aspect of the forearm and sometimes into the root of the thumb. The purpose of this study was to analyse these cords by lymphoscintigraphy before (and after) physical treatment.

Material and methods: The two upper limbs of 21 women with clinically (either obvious, or suspected) unilateralized AWS were investigated using one simplified lymphoscintigraphic protocol as developed by PB.

Results: Lymphoscintigraphy was analyzed as normal in a single case. Another presented only points of colloidal attachment on the lymphatic vessels with a normal function when compared to the normal limb. In all other patients, a decreased lymphatic function was observed. Among these 19 patients, 7 showed, either localized, or extensive lymphatic colloidal “stasis” (pattern A). In six patients, one complete stop on the lymphatic pathway was found (sometimes with first signs of developing collaterals) (pattern B) and in six additional cases, lymph stasis with localized colloidal attachment on the lymphatic pathway with obvious collateralisation(s) (pattern C) (and in two cases dermal backflow).

Conclusion: Our lymphoscintigraphic evaluations of these situations suggest that the AWS begins with one “inflammation” of the lymphatic vessel (pattern A), evolves toward lymphatic thrombosis pattern B) with the final development of lymphatic collaterals (pattern C).

EFFECTIVENESS OF PASSIVE MOVEMENT IN THE VOLUME OF LYMPHEDEMA AND CONSISTENCY REDUCTION

DOMINGO P.¹, FERNANDEZ S.², RIO A.³, ANTON S.⁴, DEL LMO I.⁵

¹ Centro Vodder de Fisioterapia, fisioterapia, Madrid (ES); ² Centro Vodder de Fisioterapia, fisioterapia Madrid (ES); ³ Universidad Europea de Madrid, fisioterapia (ES); ⁴ Hospital Universitario "La Paz". Rehabilitación, Madrid, (ES); ⁵ Universidad Rey Juan Carlos, fisioterapia, Madrid, (ES)

Key words: Lymphedema, passive motion, hyaluronic acid.

Introduction: Hyaluronic acid (HA) macromolecule is related to water retention, interstitium changes and lymphatic system. It is proved that passive movement increases the permeability of the thoracic duct and activates the nitric oxide pathway. It could possibly act as fibroblasts activator and decreases the HA lymphedema (LE).

Objectives: To assess the passive motion as a new tool to optimise the treatment of lymphedema (LE).

Methods: Seven patients with lower limb LE, 4 primary and 3 secondary was evaluated with Therapy A and B. To assess the severity of lymphedema, Grade 1 or Mild (150-400 ml total volume difference), Grade 2 or Moderate (400-700 ml) and Grade 3 or Severe (> 750 ml) were used. The tissue consistency was classified as follows: soft, malleable, slightly malleable, hard and very hard. Perimetry was performed and the volume was calculated by the cylinder's mathematical formula.

A first shock treatment was performed using manual lymphatic drainage (MLD), compression bandages and exercise during an average of 7, 2 days (Therapy A). At this stage patients suffered from severe LE (6 cases) and mild (1); with a consistency of very hard (3), hard (2), slightly malleable (1) and soft (1).

The same patients were enrolled and underwent a new shock treatment. This consisted of adding to Therapy A, a passive ankle dorsiflexion motion of 25 cycles per minute –Therapy B- (Apparatus designed by Dr. Godoy). All patients presented a severe LE (Grade 3) with hard (5), slightly malleable (1) and soft (1) consistency.

Results: In the first intensive treatment, volume was reduced from an average of 491.3 cm³, representing 29.2%, reducing to a mild LE (1), moderate (1) severe (5). The consistency of edema was modified to hard (3), slightly malleable (1), malleable (2) and soft (1). In the second treatment, the mean reduction of edema was 52.6% and 1.055,5 cm³. The consistency before treatment was hard (5), slightly malleable (1) and soft (1). After treatment it became to malleable (4), soft (3).

The volume reduction was 24.5%, due to adding passive motion to Therapy A for the treatment of lymphedema. The consistency of the edema also improved significantly in the second treatment.

Conclusions: Passive motion benefits the reduction of lymphedema and modifies the tissue consistency.

DEEP INFRARED IMAGING TO IDENTIFY VENOUS IMPAIREMENT AFTER BREAST CANCER SURGERY

BELGRADO J.-P.¹, VANDERMEEREN L.², VANKERCKHOVE S.², VALSAMIS J.-B.¹, MORAINÉ J.-J.¹, HERTENS D.², CARLY B.², LIEBENS F.²

¹ Université libre de Bruxelles - Lymphology Research Unit, Bruxelles (BE); ² C.H.U. St-Pierre - Lymphology clinic of Brussels (BE)

Introduction: Breast cancer related lymphedema (BCRL) is commonly attributed to the axillary lymph node dissection (ALND), with as consequence the reduction of lymph flow transport capacity. Scar adhesions, adjuvant therapy, radiation and chemotherapy are widely accepted by the scientific community as aggravating factors for the risk of developing BCRL.

Other parameters seems to contribute also to BCRL. One of these parameters is the change in hemodynamics of the axillary vein after ALND or sentinel node procedure. Clinical observation of BCRL-patients leads us to distinguish two groups: patients with deep pitting edema at the dorsum of the hand and forearm, and patients without. When a patient with a deep pitting edema is in orthostatic position with upper limb in adduction, hand skin looks rapidly hyperaemic, due to a vasodilation of the capillary bed. This vascular situation results from two phenomena: a less efficient venulo-arteriolar response, and the removal of the fatty tissue containing the lymph nodes during ALND together with opening of the axillary sheath. These architectural changes in the axilla lead to an impaired emptying of the axillary vein in upright position with upper limb pending. The orthostatic intermittent venous stenosis induces then collateralisation, by 3 main substitution pathways described in literature. In order to highlight these collateralisation pathways, we developed an original, simple, cheap and easy procedure, based on a deep infrared imaging (DIRI) device.

Material and Methods: The study is based on two groups of women. The control group consists of healthy women without breast pathology. The second group are all breast cancer patients, pre- and post-reconstruction, with and without BCRL. In all patients we performed visible light and DIRI of the complete thorax, including neck, shoulders and upper arms. Images were mixed and screened by 3 independent and blind operators. The operators screened for difference in temperature, existence and asymmetry of collateralisation, and anatomical areas of collateralisation.

Results: A total of 100 women were recruited, 50 in each group. The DIRI coupled with our reading grid seems to be specific and sensitive enough to identify BCRL patients with asymmetric collateralisation of the axillary vein.

Conclusion: DIRI and its reading grid seems to be a fast, cheap and useful tool in daily clinical practice to evaluate the hemodynamic changes of the axillary vein in breast cancer patients. This evaluation gives us more insight in the (future) development and eventual treatment of BCRL.

FREE COMMUNICATIONS 3

CHYLOUS REFLUX AND PRIMARY LYMPHEDEMA IN PEDIATRICS

PAPENDIECK C.M., BARBOSA L.

Angiopediatria Foundation, Buenos Aires (AR)

Introduction: Edema resulting from a dysfunction of the lymphatic system, that is because hyperplasia or hypoplasia, segmental agenesis and or 14 different possible dysplasias of the lymphatic system, is a reason of primary lymphedema. These dysfunctions are the result of dysembriogenesis, hamartomatosis and at last, vascular anomalies. One of the causes may be a chylous reflux. Chyle is formed exclusively at the mucosal level of the small gut. Its flow, in pediatrics, is difficult to study with clear images, between the intestinal level and the Pecquet Cystern. Even more when it is associated with a simultaneous free collection of chyle. This condition of the chyle lymph hemi-circuit is a complex issue in pediatrics, it is orphan, but more frequent than expected. We analyze 9 pediatric patients with combined vascular malformations, primary lymphedema and chyloperitoneum and or other collections.

Material: Considered where 9 pediatric patients, age range 2-6 years, with Waldmann's disease, Klippel Trenaunay syndrome, CLOVES Syndrome, Proteus Syndrome, Gorham Stout and Haferkamp Syndrome and Primary Lymphedema alone. In all of them, we chose an inguinal lymph node surgical approach in the context of their treatment with vascular rehabilitation and diet. The identification of a transvascular and or transnodal chylous reflux justified a therapeutical lympho venous anastomosis. An eventual exudative enteropathy loses protein at the mucosal level of the small gut. Or it does not absorb them. This means a positive fecal alpha 1 anti trypsin test (Van de Kamer) hypo proteinemia and in general malnutrition to a important or lesser degree, depending of the extension of the lesion. If there is no chyle formation, no chylous reflux is possible. If chyle is formed and coexists with chyloperitoneum or other collections, it means that there is chylous reflux, backflow or chylous leak. Backflow means that the chyle returns to the place of its formation. Chylo peritoneum or its equivalent in other cavities, in pediatrics, is traumatic, or the result of a rupture of a lympho vascular malformation. Reflux of chyle on retroperitoneal systemic lymph vessels, is a diverted flow of chyle on vessels with a incompetent valvular system, due to hypertension or malformation, and equally through lymph nodes. Interpreting a trans lympho nodal diverted flow is complex. These mechanisms may causes primary lymphedema, with the significance of a primary blockage of the system, or simply due to diverted flow of chyle through systemic lymphatic vessels on the affected limb. To explain the inverted flux of chyle through a lymph node, is a task. If this occurs before the Pecquet Cystern, the reflux is of pure chyle; if the Cystern is blocked, the backflow is with mixed lymph, chyle and systemic lymph. In both cases, a surgical approach is necessary, in the context of complex vascular rehabilitation and specific Diet. The use of valves (eg Degni, Denver, Le Veen and others) is not possible, because its diameter and it is a transient solution. A specific Diet, cannot be held for a long time, as it would lead to malnutrition, but it immediately restrain the chyle formation...

Conclusion: Chyle reflux or chyle collections because malformations of the lymphatic system is a infrequent disorder in pediatrics. Possible in syndromes with vascular malformations, combined or not. This disorder is a reason to indicate surgery. Among them, resection of the compromised area of the small intestine, and or an inguinal-only lymphovenous shunt in the context of a specific treatment for primary lymphedema, like complex vascular rehabilitation and for a short but necessary time, diet.

CLINICAL MANIFESTATIONS OF LIPEDEMA FROM A PROSPECTIVE COHORT OF PATIENTS

I. FORNER-CORDERO

Spain

Lipedema is a misdiagnosed and poorly investigated disorder with only few publications in this field.

Aim: To describe the prevalence of signs and symptoms of the patients with lipedema to set diagnostic criteria.

Methods: Prospective cohort study of patients with lipedema. Female patients were included if they present with bilateral lower limb (LL) enlargement and at least 3 symptoms of lipedema: spontaneous or provoked pain, easy bruising, family history of lipedema, absence of LL injuries, absence of Stemmer sign, symmetrical LL involvement, no swollen feet; and consent to participate.

Results: We included 93 patients. The median age was 50.7 years (range: 17.8-80.7), the mean age at the onset of symptoms was 21.9 years (+13.5), related more frequently to puberty in 46.2%. The time elapsed until diagnosis was 25.8 years (+15.8).

Body mass Index (BMI) was 31.1 (95%CI: 29.6-32.5); it was normal or underweight in 20.7%. All the patients had bilateral and symmetrical involvement; 86% disproportion with upper part of the body; 90.3% spare feet; 92.5% pain; 88.2% bruising; 82.8% absence of Stemmer sign; 83.9% had vascular spiders; 91.4% were worse at night; pitting was positive in 15.1%. Coldness sensation was reported by 36.8% of the patients. Most of the patients reported a positive family history of lipedema (82.8%).

The most frequent type of lipedema was Type 3 (from hip-to-ankles) 62.4%. The stages of lipedema were well distributed between stages I to III (I: 34.8%; II: 33.7; III: 26.1%). Concerning pain, 37.5% was neuropathic and 55.7% nociceptive somatic; in 51.2% it was mild and in 47.6% moderate. Subjective symptoms were recorded in an Analogic Visual Scale. Pain: 6.0 (95%CI: 5.4-6.7); heaviness: 6.6 (95%CI: 6.1-7.1); numbness: 3.2 (95%CI: 2.5-3.8). The disproportion between upper and lower part of the body decreased with the age and BMI: the waist-to-hip index increased with age (coefficient $\beta=0.03$; $p<0.0001$) and BMI (coefficient $\beta=0.03$; $p=0.007$).

Conclusion: Most important manifestations of lipedema were bilateral involvement of LL, pain, spare feet, bruising, and disproportion between upper and lower part of the body. These features could be used as clinical diagnostic criteria of lipedema.

IMPORTANCE OF PATIENT EDUCATION IN ERYSIPELAS CONTROL FOLLOWING BREAST CANCER RELATED LYMPHEDEMA

YESIM BAKAR, PT, PhD, Assoc. Prof.

Turkey

Introduction: Erysipelas is a common infection of the superficial layer of the skin, and is defined as an acute onset of local signs of inflammation associated with pain, swelling and also manifests with systemic symptoms such as fever, chills and malaise in patients with breast cancer-related lymphedema (BCRL).

Materials & Methods: This study evaluated whether education in combination with an educational booklet can reduce the risk of erysipelas in patients with BCRL. We analyzed 119 women with unilateral BCRL. The patients were divided into three groups: Group 1 (n=40), who received neither education nor education booklet; Group 2 (n=39), who received an education; and Group 3 (n=40), who received an education and educational booklet. The educational booklet give information about the lymphatic system, the symptoms and signs of lymphedema, and suggestions for preventing lymphedema, and avoiding infection or trauma of the upper limb.

Results: All patients were invited after 1 year for assesment. During the follow-up, 34 patients (28.6%) developed an erysipelas. The rates of erysipelas occurrence were 42.5% in Group 1 (n=17), 28.2% in Group 2 (n=11), and 15% in Group 3 (n=6) p=0.010.

Conclusions: The occurrence rate of erysipelas in BCRL patients was very high. The combination of education and educational booklet may reduce the risk of erysipelas. We conclude that patient education must begins directly after surgery to avoid lymphedema and erysipelas in patients after breast cancer.

NEW METHOD FOR DETECTION OF DORMANT BACTERIA IN LYMPHEDEMATOUS TISSUES

OLSZEWSKI W. L., ZALESKA M., DURLIK M., STELMACH E.

Central Clinical Hospital, Medical Research Center, Warsaw, Poland

Background: Lymphedema is complicated by recurrent dermato-lymphangio-adenitis attacks in around 50% of cases. To identify the causative bacteria classic bacteriological cultures are carried out from material placed in differential media. This type of culture allows to detect fast proliferating microbes but not those remaining dormant. Lacking is tissue natural environment where bacteria are nourished by host tissue products. Culture of tissue fragments on blood containing plates for days or weeks may mimic the in vivo conditions.

Aim: To culture tissue fragments on bacteriological blood plates and follow bacteria migration from tissue, formation and competition between colonies, appearance of new strains in long-lasting cultures, and sensitivity to antibiotics supplementing medium.

Methods: Skin, subcutaneous tissue, muscle, vein and arterial fragments harvested during debulking operations from 10 patients with lower limb lymphedema were placed on Hemoline plates and observed daily for 3 weeks. Bacterial strains migrating from specimens were identified. They were in situ treated with antibiotics to check antibiotic sensitivity.

Results: Daily observations of culture plates showed formation of bacterial colonies attached to specimens, growing radially (*S. epidermidis*), encroaching upon other of different color (*S. aureus*), some forming circular "waves" (*Proteus*), spreading rapidly (*Pseudomonas*), some overgrown by *Candida*. Most strains formed colonies as late as 21 days. For comparison routine cultures revealed presence of one or two strains, whereas tissue culture on plates three to five and often fungi.

Conclusions: On –blood-plate bacteriological culture of tissue specimens gives more insight into rapidly growing and dormant microorganisms and efficiency of applied antibiotics.

PRIMARY PREVENTION AFTER BREAST CANCER TREATMENT. PRIMARY PREVENTION PROTOCOL

M. CESTARI, S. AMATI, F. APPETECCHI, L. CURTI, C. DE REBOTTI

O.U. Territorial Rehabilitation Domus Gratiae Center - NHS Umbria2 - Terni, Italy

Introduction: The authors have decided to focus the attention on patients who underwent oncological breast surgery, without clinical evidence of oedema, and have planned a preventive protocol, in experimental phase, which highlights the importance of primary prevention in order to avoid lymphoedema onset.

Materials and Methods: The preventive protocol is organized in 3 steps:

1. Oncologists of DH-NHS Umbria2-Terni and DH-S. Maria Hospital-Terni send patients to O.U. Territorial Rehabilitation Centre-NHS Umbria2-Terni for evaluation.
2. A lymphologist and a physiotherapist evaluate patients: a centimetrical measurement of compared arms, a clinical examination, a lymphoscintigraphy request and a shoulder functionality evaluation.
3. Patients are divided into 4 groups after the start up of a rehabilitative project:
 - Informative Group: includes a lymphologist, a physiotherapist and all patients; the end-point is the information on behavioural rules and listening to the patients' problems.
 - Individual Lymphological Early Treatment: includes patients with lymphoscintigraphy slower radiotracer flow and the treatment of problems related to surgery.
 - Individual Rehabilitation Treatment: includes patients with limited shoulder functionality who undergo specific treatment after physiatrical assessment.
 - Physical Activity Group: includes patients without or with mild limited shoulder functionality (gymnastics, breathing exercises, relaxation technique, music-therapy, listening to their problems).

All patients evaluated are included in a follow-up.

This preventive protocol was applied in 83 patients: Informative Group all patients, Individual Lymphological Early Treatment 20 patients (then included in a Physical Activity Group), Individual Rehabilitation Treatment 8 patients (then included in a Physical Activity Group) and Physical Activity Group 55 patients (included at once).

Results: The preventive protocol highlights the awareness of patients about the possibility of preventing lymphoedema onset (only 1 patient experienced lymphoedema onset after exertion), the complete recovery of shoulder functionality, when present, and the usefulness of Physical Activity Group in order to achieve a physical and psychological well-being.

Conclusions: The preventive protocol, in experimental phase, highlights the importance of primary prevention as well as the role of a multidisciplinary team. All patients showed appreciation for the organized Groups and for the early and holistic approach of the team.

FREE COMMUNICATIONS 4

IMMUNOLOGICAL EXAMINATIONS OF THE SECONDARY LYMPHEDEMA

MORIYA OHKUMA, TAKAYOSHI KANDA*

Department of Dermatology, Sakai hospital, Kinki University, School of Medicine, Osaka, Japan, *Department of Gynecology&Obstetrics, National Osaka Medical Center South

It has been said a bacterial complication occurs only in the lymphedematous skin because the involved skin has an impaired immunity. To answer the question this examinations are performed.

Methods: Various immunological examinations are performed in randomly selected ones out of 589 secondary lymphedema patients. PPD skin tests are done after selecting the patients observed before 1997 when 97% of adults were test positive. Both PPD test and PHA are compared with senile volunteers and with the ones with malignant neoplasma in the past history. PPD is also compared with young controls.

Results: Peripheral monocyte count, C3, C4 and CH50 are high in some patients. Results of PPD tests of the lymphedematous skin are not statistically different from those of the uninvolved extremity ($p > 0.05$).

They are weaker than in young and senile controls. Results of PHA are similar with weaker reactions in the lymphedema than in the aged and in the patients with malignant neoplasma in the past. Both PHA ($p > 0.2$) and PPD skin test ($p > 0.3$) are not different in two groups, the one with and the other without past history of bacterial complications.

Discussions: Increased monocyte count and complements suggest the lymphedematous skin is always invaded by small amount of bacteria with innate immunological reactions. Bacterial complications occur only in the lymphedematous skin not because its immunity is impaired but because the edematous skin has a weaker barrier due to a swollen, moist & warm skin caused by adhered digits receiving desquamating microtrauma easily.

Conclusions: Innate immunological reactions are activated in the lymphedema. Although lymphedematous skin is not specially impaired in immunology as compared with the uninvolved skin, lymphedema patients have decreased delayed immunity than senile controls.

UNRAVELING THE PATHOBIOLOGY OF LYMPHEDEMA

E. GOUSOPOULOS, K. LEU, S. PROULX, M. UECKER, S. KARAMAN, M. DETMAR

Institute of Pharmaceutical Sciences, ETH Zurich, Vladimir Prelog Weg 1-5/10, CH-8093, Zurich, Switzerland Email: e.gousopoulos@pharma.ethz.ch

Introduction: Lymphedema is a major health problem that occurs in up to 30% of breast cancer patients after surgical lymph node excision. Lymphedema is associated with arm swelling, fibrosis, increased risk of infection and impaired wound healing. At present, there are no curative therapies for secondary, post-surgical lymphedema, and even symptomatic therapies have little beneficial effect. Thus, there is an urgent need to better understand the mechanisms of lymphatic drainage and to develop new therapeutic strategies to promote lymphatic vessel regeneration and function after surgery.

Materials and Methods: A mouse-tail lymphedema model has been used removing a circumferential band of skin 2cm below the tail base and ablating the collecting lymphatic vessels. Fluid stasis induced lymphedema that was established within 2 weeks and maintained for a minimum of 6 weeks. Next-generation-sequencing of lymphedema tissue, (immuno)histological analysis, flow cytometry analysis and in vivo imaging have been used to investigate the pathophysiology of lymphedema development and progression.

Results: Our data obtained depict the complexity of the disease and identified the interplay between inflammation and lymphatic vasculature in the pathogenesis of lymphedema. Prevailing inflammation and thus infiltration of specific types of T cells and leukocytes appear to play a critical role in the establishment of lymphedema. Lymphangiogenesis by remodelling with dilation and proliferation of lymphatic vessels during early lymphedema establishment as well as both systemic and local increase of lymphangiogenic factors indicate an active participation of the lymphatic vessels in the disease progression.

Conclusions: Our data constitute a roadmap of lymphedema development indicating an important yet undefined role of specific immune cell subset infiltrates as well as distinct chemokines and cytokines. Further studies should offer mechanistic insights into their involvement in lymphedema and potential use as targets of therapeutic interventions.

CLINICAL RELIABILITY AND THERAPEUTICAL INDICATIONS OF PRO-BNP IN LOWER LIMBS EDEMA

MICHELINI SANDRO, CARDONE MARCO, FIORENTINO ALESSANDRO, CAPPELLINO FRANCESCO, SAINATO VINCENZO,
PERINELLI DONATELLA, MICHELINI SERENA

San Giovanni battista Hospital, Rome, Italy

Introduction: Edema of the lower limbs have multiple origins. In heart failure is frequently found, especially in elderly subjects (but also in young people in particular clinical conditions) edema bilateral and symmetrical of the lower limbs. The inability of an adequate response to the 'pre-load' by the heart, often is added, in these cases, to a further difficulty of peripheral lymphatic transport. The physical treatment, in these conditions, can trigger acute crisis of 'heart failure' if the intensity of the same is not 'calibrated' on the heart compliance.

Until recently, in this sense, an important predictive significance was attributed to cardiac ejection fraction (calculated during examination echocolor Doppler); actually the real indicative factor of the cardiac compliance is the PRO-BNP, the value of which is indicative both from the functional point of view of the heart (with consequent indications for treatment with diuretic drugs and other drugs) and for the directions of physical treatment.

Materials and Methods: EF and PRO-BNP was tested in a group of 38 patients with bilateral edema of the lower limbs, of mixed genesis (17 females and 21 males, aged between 13 and 79 years, mean age 68 years).

Results: We found abnormalities in EF values in 15.5% in comparison to the considered normal values. The PRO-BNP values, on the contrary, appeared altered in 84.2% of the subjects examined. During the physical treatment of EF values remained essentially unchanged while the PRO-BNP rose up during the first sessions of about 45% (12-115%) to return to normal values at the end of treatment in 79% of subjects with baseline alterations.

Conclusions: The study shows the importance of the recognition of the PRO-BNP value in diagnostic and in the monitoring of the physical treatment in patients with bilateral lower extremity edema due to central and peripheral vascular problems.

STEWART-TREVES SYNDROME: THE MECHANISM OF THE ONCOGENESIS AND NATURE OF THE VASCULAR NEOPLASM

OKADA E.

Takaoka City Municipal Hospital, Toyama Prefecture, Japan

Introduction: Stewart-Treves syndrome (STS) is a rare, but a life-threatening complication of lymphedema, consisting of vascular malignancies and long-standing chronic lymphedema. The first case of angiosarcoma arising secondary to lymphedema was reported by Lowenstein in 1906, and Stewart and Treves reported collective 6 cases of angiosarcoma in postmastectomy lymphedema in 1948.

Materials and Methods: Review of the literatures related to STS, and immunohistochemical study of the tumor tissue obtained from a case of STS (60 years old Japanese male) who suffered from primary lymphedema of the lower extremities.

Results and Discussion: Regarding the tumor cells of the vascular malignancy observed in the case of STS, some of the tumor cells were CD34(+)/podoplanin(-) and others revealed CD34(-)/podoplanin(+). The vascular malignancies of STS have been called angiosarcoma, lymphangiosarcoma, or hemangiosarcoma depending on the literatures. Since, there are both types of tumor cells showing phenotypes for hemangiosarcoma and lymphangiosarcoma, the term angiosarcoma is thought to be appropriate to call the malignancy.

Regarding the process of the oncogenesis taking place in the syndrome, the local immunodeficiency caused by lymphedema has been regarded as the sole oncogenic factor. However, immune deficiency is thought to be a promoting factor for the oncogenesis, not an initiating. We reported that there is an increase in contents of lipid peroxide in the tissue of lymphedema. An increase in lipid peroxide is the evidence for generation of oxygen radicals. DNA-injury caused by oxygen radicals may play an initiating role in the process of the oncogenesis.

Conclusions: The vascular malignancy in STS should be called angiosarcoma. Oncogenesis of the angiosarcoma in STS is thought to be initiated by the oxygen radicals and promoted by the local immunodeficiency.

NEAR-INFRA-RED (NIR) FLUORESCENCE IMAGING OF LYMPHATIC VESSELS AFTER SUBCUTANEOUS (SC) INJECTION OF FREE INDOCYANINE GREEN (ICG): WHAT DO WE SEE? PRELIMINARY RESULTS

PIERRE BOURGEOIS¹, ROMAIN BARBIEUX², GUIDO GIACALONE³, PHILIPPE MERSCH⁴, OLIVIER LEDUC², SOPHIE VANKERCKHOVE¹, GHANEM GHANEM⁴ (Group R&D Clinical Applications of Fluorescence Imagings)

¹ Department of Nuclear Medicine and Clinic-Unit of Lymphology,

⁴ Laboratoire d'Oncologie et Chirurgie Expérimentale,

Institut Jules Bordet, Université Libre de Bruxelles, Brussels, Belgium

² Lympho-phlebology Unit, Department of Occupational and Environmental Physiology, Haute Ecole P. H. Spaak, Brussels Belgium,

³ University of Hasselt, Belgium

Introduction: Stewart-Treves syndrome (STS) is a rare, but a life-threatening complication of lymphedema, consisting of vascular malignancies and long-standing chronic lymphedema. The first case of angiosarcoma arising secondary to lymphedema was reported by Lowenstein in 1906, and Stewart and Treves reported collective 6 cases of angiosarcoma in postmastectomy lymphedema in 1948.

Materials and Methods: Review of the literatures related to STS, and immunohistochemical study of the tumor tissue obtained from a case of STS (60 years old Japanese male) who suffered from primary lymphedema of the lower extremities.

Results and Discussion: Regarding the tumor cells of the vascular malignancy observed in the case of STS, some of the tumor cells were CD34(+)/podoplanin(–) and others revealed CD34(–)/podoplanin(+). The vascular malignancies of STS have been called angiosarcoma, lymphangiosarcoma, or hemangiosarcoma depending on the literatures. Since, there are both types of tumor cells showing phenotypes for hemangiosarcoma and lymphangiosarcoma, the term angiosarcoma is thought to be appropriate to call the malignancy.

Regarding the process of the oncogenesis taking place in the syndrome, the local immunodeficiency caused by lymphedema has been regarded as the sole oncogenic factor. However, immune deficiency is thought to be a promoting factor for the oncogenesis, not an initiating. We reported that there is an increase in contents of lipid peroxide in the tissue of lymphedema. An increase in lipid peroxide is the evidence for generation of oxygen radicals. DNA-injury caused by oxygen radicals may play an initiating role in the process of the oncogenesis

Conclusions: The vascular malignancy in STS should be called angiosarcoma. Oncogenesis of the angiosarcoma in STS is thought to be initiated by the oxygen radicals and promoted by the local immunodeficiency.

FREE COMMUNICATIONS 5

CHYLOPERITONEUM: MODERN DIAGNOSTIC ASPECTS AND THERAPEUTIC OPTIONS

S. DESSALVI¹, L. MOLINARI¹, S. SPINACI¹, C.C. CAMPISI¹, F. BOCCARDO¹, M. FERRARI², C. CAMPISI¹

¹ Department of Surgery – Unit of Lymphatic Surgery (Chief: Prof. C. Campisi); ² Trasfusione Center.

IRCCS S. Martino – IST, National Cancer Institute – University of Genoa, Italy Email: saradessalvi@hotmail.it

Introduction: With the term Chyloperitoneum (or Chylous Ascites) we mean the presence of chylous within the peritoneal cavity. We distinguish idiopathic (or primary) and secondary forms. Among the secondary forms, the most frequent causes in adults are represented by iatrogenic lesions of the main afferents of the Cisterna Chyli, and malignant tumors. Other possible causes of secondary Chyloperitoneum are the abdominal trauma (open or closed), liver cirrhosis, tuberculosis, pancreatitis (acute and chronic) and filariasis. Chyloperitoneum is most often associated to other clinical features such as chylothorax, chyluria, protein Losing Enteropathy, etc.

Methods: Diagnostic tests include specific pre-operative Lymphoscintigraphy of the lower limbs, and sometimes even the upper limbs (“Whole Body Lymphoscintigraphy”), Lymphangio-MRI and Lymphangiography but, above all, the Lymphangio-CT.

Standard lymphangiography (LAG) uses liposoluble ultrafluid contrast (Lipiodol Ultrafluid) injected after isolation and cannulation of the lymphatics of the dorsum of the foot with microsurgical technique. If coupled with a CT scan (Lymphangio-CT, LAG-CT), LAG allows a more accurate assessment of disease extension, as well as the site of the obstacle and source of chylous leakage.

The main indications to the use of LAG-CT are represented by pre-operative assessment of patients affected by primary, post-traumatic and post-operative chylostatic disorders. The isolation of the lymphatic collector is performed using operative microscope magnification. Once the contrast is injected entirely, the patient undergo multi slice CT examination. LAG-CT brings about precise informations about the site of chylous dysplasia and/or fistulas, since it supplies precise relations between lymphatic-lymph nodal structures and skeletal apparatus.

Results: In the literature it is reported that lymphangiography can have also sclerosing effects on lymphatics, obtaining the closure of lymphatic fistulas in patients with chylous ascites. LAG-CT represents presently the only diagnostic investigation that can supply precise topographic information about the site, cause and extension of chylous pathology and allow to plan proper therapeutic procedures.

Discussion and conclusions: There are several treatment options that can be taken for the treatment of Chyloperitoneum, although their effectiveness is very variable, in function of etiopathogenesis and extent of the disease. Recently, we treated and solved the clinical case of a refractory secondary chyloperitoneum with the use of fibrin glue injection at the site of the chylous leakage. An accurate diagnostic study that includes, in addition to Lymphography, also a specific surgical approach Laparoscopic/Open surgery and Microsurgery, has been shown to be effective in the treatment of Chyloperitoneum refractory to medical treatment and paracentesis.

THE ROLE OF PLASTIC; RECONSTRUCTIVE AND AESTHETIC SURGERY IN THE TREATMENT OF ADVANCED LYMPHEDEMA-WHILE THE EARLY BIRD CATCHES THE WORM; THE LATE RISER STILL BENEFITS

CAMPISI C., BOCCARDO F.

Plastic, Reconstructive and Aesthetic Surgery & Lymphatic Surgery and Microsurgery (Director Prof. C. Campisi), IRCCS S. Martino University Hospital – IST, Genoa, Italy

Introduction: In lymphedema, excess adipose tissue occurs with progression of the disease because of chronic lymph stasis, and impedes lymphatic flow. Recently, liposuction has been utilized as a less-invasive procedure to remove this excess tissue. Given the existing poor lymph drainage in patients with lymphatic diseases, extra caution needs to be taken to avoid damaging the lymphatic vessels during liposuction. We have developed a new technique Fibro-Lipo-Lympho-Aspiration (FLLA) with Lymph Vessel Sparing Procedure to improve the chronic swelling of patients with advanced lymphedema. FLLA makes the lymphatic pathways are visible in the treated limb thanks to the application of PDE imaging and/or BPV dye. This visibility allows the surgeon to avoid these lymphatic channels whilst removing the maximum amount of excess tissue.

Method: Ninety patients with primary or secondary lymphedema that had already been treated by derivative/reconstructive lymphatic microsurgery under the CLyFT treatment protocol in Genoa, Italy were included in this retrospective study. All patients had achieved significant volume loss after microsurgery but all had residual fibrotic/adipose tissue that was resistant to conservative treatments. Using microlymphography techniques to highlight the lymphatic pathways, the excess adipose tissue was carefully aspirated with the FLLA procedure.

Results: The length of the 90 procedures was relatively constant; with an average of 70 minutes for the upper limb (45’ min-90’ max, SD of 14.43) and 105 minutes for the lower limb (75’ min-120’ max, SD of 10.07). Regarding the quantity of the aspirated material, for the upper limb the average was 0.72 L (range of 0.2 L-1.4 L, SD of 0.38L) and the lower limb was 2.36 L (range of 0.9 L-4 L, SD of 0.98L). No episodes of post-operative infection occurred within the six months of follow up for patients treated for upper limb or lower limb chronic lymphedema. This was a significant reduction in frequency from the pre-operative status in both the upper and lower limbs (W=0, P=0.001, n=19; and W=0, P=0.001, n=13, respectively).

Conclusion: The FLLA procedure is efficient. It is possible to complete an entire leg within 90 minutes. Recovery time is short and cosmetic results are immediate. More importantly, the removal of excess tissue is completed without further damage to lymphatic vessels. When used after microsurgery, FLLA offers the possibility of removing almost all obstacles to lymphatic flow.

LYMPH NODE TRANSFER IN COMBINATION WITH A DIEAP-FLAP BREAST RECONSTRUCTION BY BREAST CANCER RELATED LYMPHEDEMA: PROMISING OR WRONG APPROACH?

SEIDENSTUECKER K., ZELTZER A., HAMDI M.

Dpt of Plastic Surgery, University Hospital Brussels, Belgium

Introduction: Recent articles report that surgery can effectively treat secondary lymphedema. The mechanisms of lymph node transfer have been discordant between different publications but this procedure showed promising results. Intrinsic lymphovenous connections have been previously shown to exist in the transferred flap. But if you transfer the nodes together with the abdominal wall in case of DIEAP + VLNT – don't you transfer nodes with the belonging draining region? Why should the nodes start changing the draining direction and should drain the arm after being transferred to the axillary region?

Material and Methods: Since 2007 the senior author performs vascularized lymph node transfer (VLNT) in combination with autologous breast reconstruction with DIEAP (Deep inferior epigastric artery perforator) flap. In the long time follow up we regarded in some cases that the thoracic wall including the breast region had less swelling and the patient improve regarding the mobility of the arm. But the circumferences of the arm remained nearly the same. We are now going to reevaluate our DIEAP + VLNT group by performing lymphodynamic evaluation using ICG indocyanine green to study the migration direction of the transferred nodes.

Results: On spec that the transferred nodes didn't drain the affected limb we change our operative approach and separate the two in one procedure. Also in need of an autologous breast reconstruction we perform two operations: the breast reconstruction with the DIEAP flap and the node transfer as a vascularized groin flap, harvest most common on the superficial circumflex iliac artery perforator (SCIAP) flap.

Conclusions: The vascularized lymph node transfer is a value option for the operative treatment of lymphedema. By breast cancer related lymphedema the combination of a node transfer and an autologous breast reconstruction with a DIEAP flaps appeared to be an elegant solution but our clinical follow up let us review our approach and modified it into a two stage separate operation.

HEADING TOWARDS AN ARTIFICIAL LYMPHATIC VESSEL TO TREAT LYMPHEDEMA

M. PISANO^{1*}, V. TRIACCA^{1*}, L. MAZZOLAI³, M.A. SWARTZ^{1,4}

¹ *Institute of Bioengineering, EPFL, Lausanne, Switzerland*

² *Radio-oncology Service, CHUV, Lausanne, Switzerland*

³ *Angiology Service, CHUV, Lausanne, Switzerland*

⁴ *Institute for Molecular Engineering, University of Chicago, IL, USA.*

* *Authors contributed equally to this work*

Introduction: Despite recent advances in pharmacological research and microsurgery, lymphedema remains an incurable disease that deeply affects patient's quality of life. There is an urgent need for innovative approaches to restore continuous lymph flow drainage in affected tissues, as lymphatic vessels do in healthy people. To this end, we are using engineering tools to develop an implantable device draining interstitial fluid from the subcutis and continuously transporting it to the venous circulation. This would re-establish a homeostatic fluid equilibrium in affected limb, thus functioning as an artificial lymphatic vessel. Here we compare the biocompatibility of various materials, and present a new design for a micropump-based prototype to be evaluated in acute and chronic edema models.

Materials and Methods: For biocompatibility studies, medical grade silicone tubes (Novimed AG, Dietikon, CH) were implanted subcutaneously in the back of Wistar rats for 1 month. Tubes were either uncoated or coated with 2-methacryloyloxyethyl phosphorylcholine (MPC) or with C-Parylene (Specialty Coating Systems, Indiana, USA). The acute edema model was obtained by subcutaneously injecting a solution of 1.5% glycine in saline in the back of Wistar rats. A catheter connected either to an external pump or to an implantable one, was subcutaneously inserted and amount of fluid retrieved by the pump was measured. The chronic lymphedema model was obtained following the protocol by Yang et al. (PRSGO, 2014), based on the removal of inguinal and popliteal lymph nodes, cauterization of collecting vessels and irradiation in the inguinal area.

Results: As a proof-of-concept, we verified that it is possible to drain fluids from the subcutaneous space using porous silicone tubings, and an external pump applying negative pressure in an acute edema model. Foreign body reaction to the coated silicon tubing is being currently evaluated in rats. Our prototype design for a permanent draining implant consists in a system of micropumps and catheters implanted in the subcutis. The catheters, having multiple access pores on their lateral surfaces, are inserted at the level of the edematous area in the affected limb, and are integrated with a set of micropumps connected in series, which will drain the edematous fluid to a vein through a final impermeable output catheter.

Conclusions: Here we propose a new approach to treat lymphedema, applying engineering principles to restore lymph drainage from the edema to the venous circulation, thus opening the way to the development of an artificial lymphatic vessel.

FREE COMMUNICATIONS 6

DIAGNOSTIC ACCURACY OF FLUORESCENCE MICROLYPHOGRAPHY FOR DETECTING LIMB LYMPHEDEMA

HONG H. KEO¹, MARC HUSMANN², ERNST GROECHENIG¹, TORSTEN WILLENBERG³, SILVIA B. GRETENER⁴

¹ Division of Angiology, Kantonsspital Aarau AG, Aarau, Switzerland

² Clinic for Angiology, University Hospital and University of Zurich, Switzerland

³ Berner VenenZentrum, Bern, Switzerland and Swiss Cardiovascular Center, Division of Angiology, Inselspital, University Hospital and University of Bern, Switzerland

⁴ Angiology Oberaargau, Langenthal, Switzerland

Objectives: Fluorescence microlymphography (FML) is a minimally invasive technique for visualization of the cutaneous lymphatic network. The aim of the study was to assess the accuracy and safety of FML in patients with unilateral lymphedema.

Design: Crosssectional study

Material and Methods: Patients with unilateral leg swelling were assessed and compared with the unaffected contralateral limb. FML was performed in all index legs and the contralateral leg. FML was performed by injecting 0.1 ml fluorescein isothiocyanate (FITC)-labeled dextran intradermally in both limbs at the same level and most prominent swelling of the affect limb was the anatomical reference. The spread of the dye in the lymphatic capillaries of the skin was measured in all dimensions by epiluminator intravital microscopy and the maximum dye spread value ten minutes after injection was used for statistical analysis. The contralateral leg served as control. Test accuracy and receiver operator characteristic (ROC) analysis was performed to assess threshold values that best predict lymphedema.

Results: Between March 2008 and February 2014 a total of 70 patients with unilateral chronic leg swelling were clinically diagnosed with lymphedema. Median age was 45 (IQR 27- 56) years. Of those 46 (65.7%) were female and 71.4% had primary and 28.6% had secondary lymphedema. Sensitivity, specificity, positive and negative likelihood ratio and positive and negative predictive value were 94.3%, 78.6%, 4.40, 0.07, 81.5% and 93.2% for the 12 mm cutoff level and 91.4%, 85.7%, 6.40, 0.10, 86.5% and 90.9% for the 14 mm cutoff level, respectively. The area under the ROC curve was 0.89 (95% CI: 0.83, 0.95). No major adverse events were observed.

Conclusion: FML is an almost atraumatic and safe technique for detecting lymphedema in patients with leg swelling. In our series the best accuracy was observed at a cut-off level of ≥ 14 mm maximum spread.

STUDY ON REAL-TIME LYMPH FLOW IN THE LYMPH VESSELS OF THE LOWER LIMB BY INTERMITTENT PNEUMATIC COMPRESSION IN HEALTHY VOLUNTEERS AND LYMPHEDEMA PATIENTS

MAEGAWA J.¹, MATSUBARA S.¹, MIKAMI T.¹, TOSAKI A.²

¹ Yokohama City University Hospital, Yokohama, Japan

² Higashikanagawa acupuncture clinic, Yokohama, Japan

Background: It has been still unknown how lymph flows by intermittent pneumatic compression (IPC). Aims of this study were to reveal real-time lymph-flow and lymph-flow patters in the superficial lymphatics of the leg by ICG fluorescence lymphography during IPC in the healthy volunteers and lymphedema patients.

Materials: Nine healthy volunteers and six patients with lower limb lymphedema participated in this study. After subcutaneous injection of Indocyanine Green lymph-flow in the leg was observed by PDE system (Hamamatsu Photonics, Japan) and a transparent garment with 6 chambers connected to a pneumatic pump, Physical Medomer (Medor Inc., Japan) was then put on the leg. Each chamber inflates with a maximum pressure of 90 mmHg for the volunteers and 90 and 45 mmHg for the patients in sequence or at the same time and deflates according to some orders we set. During the inflation and deflation the lymph-flow in the mid lower leg was recorded through the PDE system and brightness of the recorded images was calculated by software.

Results: Real-time lymph-flow could be observed through the transparent garment during IPC by ICG fluorescence lymphography. The brightness in the images in the mid lower leg changed more quickly in the deflation period we set than in the inflation period, which means the lymph flowed faster in the deflation period than the inflation.

Discussions: IPC accelerates lymph-flow in the superficial lymphatic vessels of the leg in the healthy volunteers with faster flow in the deflation period than inflation. Timing of deflation seems to be important to obtain effective lymph-flow in IPC. Lymph flows similarly by inflation with both 90 and 45 mmHg in lymphedema patients, which suggests low pressures of IPC is sufficient to promote lymph flow in some lymphedema patients.

MEASUREMENT OF LYMPHEDEMA: PYTHAGORAS VS ARCHIMEDES VS HIGH-TECH

VALSAMIS J.-B.¹, PERRAULT S.¹, VANKERCKHOVE S.², VANDERMEEREN L.², MORAINÉ J.-J.¹, BELGRADO J.-P.¹

¹ BEAMS Department, Ecole Polytechnique de Bruxelles, Belgium

² C.H.U. St-Pierre - Lymphology clinic of Brussels, Belgium

Introduction: Measurement of lymphedema still remains a challenge. It must combine quality of measurement, rapidity, ease of use and minimum intra- and interoperator variation. The device and the method have to be accurate and sensitive enough to detect tiny variations for 2 main reasons: follow the edema in the time and follow patients at risk to develop secondary lymphedema, in order to detect as early as possible the occurrence of the edema. In the present study, we compared 3 methods of edema measurements: tape perometry, the Archimedes method and the 3D-imaging.

Material and Methods: The study has been performed on the upper limb. The limb has been graduated every 4cm from the pisiform bone (the reference) along 32cm, defining 5 areas: the hand, and the 4 regions of 8cm. The tape perometry consists in measurement of perimeters on each graduation and the figure 8 method for the hand. The Archimedes method consists in immersing the limb of the patient from the hand to the 32cm of the limb by step of 8cm. The immersed part of the volume can be measured as the reaction of the Archimedes force which is applied on a weight. The 3D-imaging consists in acquiring a 3D model of the arm and in evaluating the volume by software. The study involved the measurement of both side upper limbs of 8 patients, giving a sample size of 16. Two operators performed the measurements. Each operator performed twice the measurements except for the 3D-imaging.

Results: We have evaluated and compared the quality of the measurements of the three techniques according to mathematical and practical aspect as well. The results have highlighted the difference between the intra-operator errors, inter-operator errors and the bias induced by the techniques. The different techniques present specific advantages/weaknesses. The perometry method is very easy, low cost and presents a good trueness and a very low intra-operator error on the areas taken separately (parts of 8cm). However the bias is important. The Archimedes method is also easy and can be automated with a dedicated software including data in the patient files. It shows a very low inter-operator error on the cumulative areas (part 0-32cm). The 3D-imaging is very expensive and time consuming but produces a good trueness of the measurement.

Conclusion: This study has confirmed the problematic of the quality of measuring volumes in lymphedema through different aspects such as reliability, efficiency, use in routine, time consumption, cost... It shows that our simple method revisiting Archimedes principle is well suited to improve the measurement quality. It may therefore be an alternative to the water displacement method. A simple lecture on a weight determines the volume on a chosen number of limb segments.

Acknowledgment: We would like to thank Florian Federer, Quality/Metrology Manager at EMS, for his help about the 3D-imaging system.

NEAR-INFRA-RED (NIR) FLUORESCENCE IMAGING OF « SENTINEL » LYMPH NODES IN CANCERS AFTER THE INTRA-VEIN INJECTION (IV) OF FREE INDOCYANINE GREEN (ICG)

PIERRE BOURGEOIS¹, ANTOINE DIGONNET², ISABELLE VEYS², GABRIEL LIBERALE², SOPHIE VANKERCKHOVE¹, MARIE CHINTINNE³, MARIA GOMEZ GALDON³, NICOLAS DE SAINT-AUBAIN³, DENIS LARSIMONT³, BISSAN AHMED¹, FILIP DE NEUBOURG², DANIELLE NOTERMAN², GUY ANDRY² AND JEAN-MARIE-NOGARET² (Group R&D Clinical Applications of Fluorescence Imagings)

¹ Department of Nuclear Medicine and Clinic-Unit of Lymphology,

² Service of Surgery,

³ Department of Anatomic-Pathology,

Institut Jules Bordet, Université Libre de Bruxelles

Introduction: The «Sentinel Lymph Node» (SLN) concept is usually based on the demonstration of specific LN (so defined as at risk to harbour cancerous metastases) after the peri-tumoural injection of vital dyes and/or radio-pharmaceutical and/or fluorescent molecules. The aim of our presentation is to report our observations obtained in patients with various cancers after the IV injection of free ICG,

Material and methods: 0.25 mg of free ICG per kg were IV injected just after their anesthesia in patients (15 with breast cancer, 10 with Head and Neck cancer and 3 with colo-rectal cancer), in the framework of various research protocols and with their informed consent (CE2075, CE2088, CE2178 and CE2290: Eudract 2013-0001000-41, 2013-000653-42, 2013-004498-29, 2014-003512-37). The lymph nodes found during these patients' surgeries were evaluated for their fluorescence using a dedicated NIR imaging device (Photodynamic Eye, PDE; Hamamatsu Photonics, Hamamatsu, Japan) and their fluorescence correlated with their anatomic-pathological status.

Results: In all the patients with Breast Cancer, fluorescent LN were found in their axillary piece of dissection and in the four pN+ patients, metastases were observed in fluorescent LN. Among the patients with nodal relapses of Head and Neck cancer, these pathological LN were also seen fluorescent and in these patients who underwent cervical LN dissection (cN-), fluorescent LN were also systematically found and metastases also seen preferentially in the most fluorescent ones. Among the patients who were investigated for NIR evaluation of peritoneal carcinomatosis of colo-rectal origin, one had three pathologic LN on pre-operative work-up and these pathologic LN were more fluorescent than the pN- ones. In two other patients with no pre-operatively suspected LN, one epigastric hyper-fluorescent LN was discovered per-operatively in each case and the LN so found was pN+ in one case.

Conclusion: Our observations that LN are found fluorescent after the IV injection of free ICG, either in case of suspected nodal relapse, or in the framework of "standard" nodal dissection, and, that in the case of the last ones, metastases were preferentially found in these fluorescent LN, have important clinical implications. NIR fluorescence imaging of the LN after such IV injection of free ICG may define in another way the "sentinel" LN at risk to harbour metastases, per-operatively and/or in the Department of Anatomic-Pathology. Actually, we are so investigating prospectively the contributions of such imagings to detect per-operatively these fluorescent "sentinel" and/or pathologic LN.

MODERATED POSTER SESSION 1

MEASUREMENT OF LYMPHEDEMA: PYTHAGORAS VS ARCHIMEDES VS HIGH-TECH

PAPENDIECK C.M., BARBOSA L.

Angiopediatria Foundation, Buenos Aires, Argentine

Introduction: Congenital Syndromic Asymmetric Overgrowth is a frequent semiological finding in pediatrics. Many times, it is complex to interpret and in some cases it is a mere discrete semiological sign. To a certain degree, patients are orphan in clinical and therapeutic aspects, with asymmetric growth of some part of the body, with or without vascular anomalies and or not, lipomatous overgrowth. They are analyzed and grouped according to their etio-physiopathology, clinical signs and significance in pediatrics.

Material: Pediatric patients with this condition, can be grouped in:

1. Congenital asymmetric overgrowth, eg. Wiedemann Beckwith S. and others
2. Congenital asymmetric overgrowth because vascular anomalies, eg. Klippel Trenaunay S., and others
3. Congenital lipomatous overgrowth with vascular anomalies eg. Proteus S., CLOVES S, Primary Lymphedema and others.
4. Congenital lipomatous overgrowth without vascular anomalies...

Conclusion: The patho- physiological, etiology and semiological aspects of pediatric patients with congenital syndromic overgrowth are analyzed.

THE EFFECTIVENESS OF COMPLEX DECONGESTIVE PHYSIOTHERAPY IMPLEMENTATIONS ON QUALITY OF LIFE AND DEPRESSION IN PATIENTS WITH CHRONIC VENOUS INSUFFICIENCY

ÖZLEM ÇINAR ÖZDEMİR PT. PhD. Assist Prof., YEŞİM BAKAR PT. PhD. Assoc. Prof.

Abant İzzet Baysal University, School of Physical Therapy and Rehabilitation, Bolu, Turkey

Introduction: The aim of the study was to evaluate the effect of complex decongestive physiotherapy implementations on quality of life and depression in patients with chronic venous insufficiency.

Materials & Methods: 14 individuals, mean age 56.43 ± 11.68 , included in the study with phase 2 chronic venous insufficiency. Edema quantities were measured by Leg Q Meter using limb circumference, and pain assessment was done with "Visual Analogue Scale". General quality of life was measured by "Nottingham Health Profile", disease specific quality of life was determined by using "Venous Insufficiency Epidemiological and Economic Study-Quality of Life/Symptoms" and depression state assessment was done by using "Beck Depression Scale". Individuals were applied the complex decongestive physiotherapy program (CDP) consisting of manual lymphatic drainage, skin care, compression bandage and exercise. Participants taken in treatment 5 days per week along 4 weeks. At the end of the 4th week, protection phase was started and fabrication under knee compression stocking were given each individuals. Individuals were assessed pre-treatment, post-treatment and 4 weeks later after treatment.

Results: There was seen significant difference of all measurements on Pre-treatment-(Pre-t) Post-Treatment(Post-t) and Pre-t-Protection values when comparison of circumference measurements. ($p < 0.05$). By the same way, there was seen significant difference in comparison of pain, quality of life and depression level Pre-t-Post-t and Pre-t-Protection values. ($p < 0.05$)

Discussion: Results have revealed the CDP is quite effective method about decreasing edema and quality of life increasing related decreasing edema. It is suggested that individuals with chronic venous insufficiency needed to being aware about using compression socks and consulting physiotherapy for decreasing status related venous symptoms due to results long term stocking using effected quality of life.

THE ROLE OF INTERLEUKIN-7 IN LYMPHATIC VESSEL FUNCTION AND ITS THERAPEUTIC POTENTIAL FOR THE TREATMENT OF LYMPHEDEMA AND CHRONIC SKIN INFLAMMATION

MARIA IOLYEVA¹, MARTINA VRANOVA¹, DAVID AEBISCHER¹, STEFANIE MEIER¹, DANIELA IMPELLIZZIERI², ONUR BOYMAN², STEVEN T. PROULX¹ AND CORNELIA HALIN¹

¹ Institute of Pharmaceutical Sciences, ETH Zurich, Vladimir-Prelog Weg 1-5/10, 8093 Zurich, Switzerland

Email: martina.vranova@pharma.ethz.ch

² Laboratory of Applied Immunobiology, University of Zurich, Gloriastrasse 30, 8006 Zurich, Switzerland

Interleukin-7 (IL-7) is a cytokine known for its role in T and B cell homeostasis, as well as in lymph node organogenesis. Our lab has recently identified a novel role for IL-7 in lymphatic vessel biology. Lymphatic endothelial cells (LECs) were shown to produce IL-7 and to express the IL-7 receptor chains, namely the interleukin-7 receptor alpha (IL-7R α) and the common receptor gamma chain (CD132). IL-7 was able to activate human lymphatic endothelial cells *in vitro* and to induce lymphangiogenesis *in vivo*. Furthermore, the lymphatic network and function were greatly affected in IL-7R α -/- and IL-7 transgenic mice. Functional drainage assays revealed that genetic overexpression of IL-7 or exogenous application of recombinant IL-7/anti-IL-7 complexes to WT mice markedly improved the drainage of a lymphatic specific dye from dermal lymphatics. Moreover, the use of bone marrow chimeras indicated that the drainage enhancing effect of IL-7 was dependent on IL-7 receptor expression in stromal cells rather than bone marrow derived cells. Intravital imaging experiments revealed that the pumping rate of the collecting lymphatics remained unchanged in the IL-7R α -/- mice compared to WT mice, whereas increased leakage of dye from the lymphatic capillaries was observed. We are currently investigating the mechanism by which IL-7 enhances drainage by performing intravital contractility studies and ex vivo analyses of the lymphatic capillaries and collectors in IL-7R α -/- mice. Furthermore, we are exploring whether the drainage enhancing effect of IL-7 can be used to treat diseases characterized by lymphatic drainage dysfunction, such as lymphedema and chronic skin inflammation. To this end we have created a murine IL-7-Fc fusion protein to extend the half-life of IL-7 in mice, making it suitable for therapy experiments.

CCL21 EXPRESSION PATTERN IN LYMPHATIC VESSELS

ERICA RUSSO, JORGE ARASA, CORNELIA HALIN

ETH Zurich, Institute of Pharmaceutical Sciences, HCI G490, Vladimir-Prelog-Weg 1-5/10, CH-8093 Zurich, Switzerland Email: jorge.arasa@pharma.ethz.ch

Adaptive immune responses are essential for conferring protection against infections and for promoting immune tolerance. They are initiated by the migration of leukocytes, particularly dendritic cells (DCs), through afferent lymphatic vessels (LVs) to draining lymph nodes (dLNs). Nevertheless, to date, DC migration into and within LVs remains poorly understood. In this sense, it has recently been described that DCs actively crawl within lymphatic capillaries and only passively transported once they reach the downstream-located segments of collecting LVs. The DCs migration into the LVs is mainly mediated by CCL21, a chemokine constitutively expressed by the lymphatic endothelium; however, CCL21 expression pattern along the LVs is still under discussion.

The aim of this work is to further investigate the expression of CCL21 in the capillaries and collectors of murine ear skin. For this purpose, we have established a new 5-color FACS staining approach that allows us to isolate lymphatic endothelial cells from the collectors (colLECs: CD45-, CD31+, podoplanin+, lyve1-) and capillaries (capLECs: CD45-, CD31+, podoplanin+, lyve1+). Thereby, we have found significant differences in the protein expression pattern, as well as in the mRNA expression of CCL21 between capillaries and collectors LVs. Furthermore, these results have been confirmed by whole mounts immunofluorescence where we detected a strong predominant expression of CCL21 in podoplanin+LYVE1+ capillaries.

Overall, our findings shed light on the expression pattern of this chemokine along the LVs and is prompting to further understand DCs migration across the LVs.

AXILLARY VEIN COMPRESSION TEST

BELGRADO J.-P.¹, VANDERMEEREN L.², VANKERCKHOVE S.², VALSAMIS J.-B.¹, MORAINÉ J.-J.¹, LIEBENS F.²

¹ Université Libre de Bruxelles - Lymphology Research Unit, Bruxelles, Belgium

² C.H.U. St-Pierre - Lymphology clinic of Brussels, Belgium

Introduction: Total adenectomy of the axilla has not only consequences on the lymph flow, but also on other biomechanical functions: modifications of the axillary vein's hemodynamic can be involved in the pathophysiology of secondary breast cancer lymphedema.

The gold standard examination, echodoppler, is time consuming and needs a specific protocol to confirm the orthostatic intermittent stenosis of the vein.

We have developed a fast and specific provocation test in order to highlight a possible participation of the vein in the genesis of edema.

Method: 42 patients affected by unilateral secondary breast cancer lymphedema stage I or IIa have underwent our provocation test. During the execution of the test, the examiner is behind the patient; the concerned upper limb is held passively in antepulsion of 90° (reference position); the color of the dorsum of the hand is memorized; then, the arm is placed by the examiner vertically along the trunk, adding manually a sagittal and medial compression on the root of the limb during 15 seconds. If the hand really reddens, the test is positive.

In order to study the test, we started with a qualitative and a semi-quantitative observation. For the qualitative part, we asked an innocent bystander to appraise the change of the hand's color during the test on both arms. For the semi-quantitative part, we took a picture of the hand in standardized conditions at both steps (reference position and vertical position).

With the help of software ImageJ we filtered RGB colors maintaining only the red pixels. Then the histogram of step 1 and 2 were compared.

Results: The axillary vein provocation test is easy to apply by a single examiner in the clinic routine; it takes only 30 seconds. The correlation between the qualitative and semi-quantitative test is effective ($r=0,92$, $p<0,001$)

Provoking a "prolonged" compression of the axillary vein, in pathological conditions aggravates the intermittent phenomenon that is expressed by an increase of the skin's redness because of an increased pressure in the distal microcirculation.

Conclusion: All patients were submitted to our axillary vein compression test. Patients with positive test present an impairment of the axillary vein's hemodynamic, inducing rapid hand's redness. This study confirmed good correlation between the visual qualitative method and a semi-quantitative method to assess hand's redness. In conclusion, we propose here a simple and rapid axillary vein compression test to screen patients with impairment of the axillary vein's hemodynamic, which may be validated directly by visual observation.

LYMPHEDEMA PATIENTS' SELF-TREATMENTS: PSYCHOSOCIAL ASPECTS

BENDOVA M.¹, SKRIVANOVA K.², BENDA K.³

¹ Dept. of Gynaecology and Obstetrics / University Hospital Brno, Czech Republic

² Institute of Psychology and Psychosomatics Medical faculty/ Masaryk university, Brno, Czech Republic

³ Dept. of Radiology/ University Hospital, Brno, Czech Republic

Lymphedema management is based on complex decongestive therapy (CDT) and complementary therapeutical procedures as surgery, pharmacotherapy, psychotherapy and self treatment. Pts' self-treatment includes: skin care, self-lymphdrainage, self-bandaging, self-applied pneumatic compression, elevation of the limbs, supporting physical and breathing exercises, appropriate recreational and sport activities, arrangements in life régime and self-measurements. Our study is based on experience from in general 648 pts. suffering from chronic lymphedema, treated in ARCUS onco- lymphocentre who underwent CDT according individual planning, including educational seminars (self-treatment, life régime, nourishment, supportive physical exercises). To all pts. self-treatment was recommended after clear enough instructions. Collected knowledge evoked consequential cognitions concerning psychological factors influencing pts' self-treatment. They are:

a/ Basic psychological factors determining effective self-treatment:

- appropriate pts' information about lymphedema pathophysiology and essential treatment procedures (CDT),
- individual self-treatment planning according to pt's age, physical and psychical limitations, manual ability, necessity of somebody else's help etc.),
- awareness of regular checking and control of pt's compliance, physical state and psychic condition.

b/ Psychological impact on active self-treatment and to CDT effectiveness:

- strength of pt's compliance and active participation in CDT,
- strength of pt's awareness of personal responsibility for treatment outcome,
- strength of pt's activity, self-assurance, self-confidence and prevention of possible psychic disorders (discomfort, disappointment, depression, anxiety, care-ignorance etc),
- benefit of feasibility at home (everywhere).

Conclusion: Self-treatment represents unavoidable part of CDT. Knowledge of influencing psychological factors improves effectiveness of this procedure.

This study was supported by grant P 407/12/O6O2 of the Grant Agency of the Czech Republic

MODERATED POSTER SESSION 2

REPLACEMENT OF OBLITERATED LYMPHATIC COLLECTORS IN OBSTRUCTIVE LYMPHEDEMA BY SILICONE TUBING IMPLANTS

OLSZEWSKI W. L., ZALESKA M.

Central Clinical Hospital, Medical Research Center, Warsaw, Poland

Background: The lymphatic structure of tissue is composed of the intercellular space and lymphatic vessels. The intercellular space is a network of billions of confluent microspaces. Tissue fluid flows from these spaces to the lymphatics. Obliteration of lymphatics, clinically recognized as lymphedema, brings about stasis of fluid with dilatation of the intercellular space. In course of time, large spaces or pseudo-channels are formed. Flow of fluid is hampered by hydraulic resistance of tissue and lack of propelling force. The question arises whether decongestion of edematous tissue can be accomplished by implantation of artificial channels and application of external compression.

Aim: To study the effect of silicone tubing implants replacing obliterated collecting lymphatics followed by external compression on edema fluid flow to the non-swollen regions.

Material and methods: Study included 25 patients with lymphedema of lower limbs stage III and IV. Twenty patients developed edema after hysterectomy and radiotherapy, 5 had infectious skin incidences in the past. Lymphoscintigraphy showed lack of flow of tracer from foot to the groin. Three medical grade hydrophobic silicone tubing o.d.3.2, i.d. 1.8 mm, perforated every 2 cm, were implanted subcutaneously from mid-calf to hypogastrium. Elastic stockings grade II and two weeks of intermittent pneumatic compression were then applied.

Results: After 2 years the mean decrease in circumference in mid-calf was from 1.5 to 5 cm. No expulsion of implant was observed. In 2 cases inflammatory episodes at the hypogastric end of implant, controlled by amoxicillin, were observed. On lymphoscintigraphy tracer was seen in the tubings or around them. On ultrasonography accumulation of fluid around tubings could be shown. In some cases no flow of tracer was observed although there was its evident absorption.

Conclusions: Silicone tubing implants in lymphedematous is a low-invasive effective method for decompression of obstructive lymphedema.

CUMULATIVE PATENCY RATE OF LYMPHATIC VENOUS ANASTOMOSIS AND POSTOPERATIVE CHANGES OF COMPRESSION IN TREATMENT OF UPPER LIMB LYMPHEDEMA

MAEGAWA J.¹, MATSUBARA S.¹, MIKAMI T.¹, TOSAKI A.²

¹ Yokohama City University Hospital, Yokohama, Japan

² Higashikanagawa acupuncture clinic, Yokohama, Japan

Introduction: There are few reports on lymphatic-microsurgery in upper limb lymphedema. We report mid- and long term results in patency of lymphaticovenous side-to-end anastomosis (LVSEA) by real-time lymphangiography and effects to reduce contents of postoperative compression in breast cancer-related lymphedema.

Aim: The aim of this study is to evaluate volume changes of the affected limbs and contents of CDP and patency of the anastomoses.

Methods: Between 2009 and 2012 29 limbs of 29 patients with pre- and postoperative CDP by one institute and LVSEA by one surgeon were evaluated. All of them had breast cancer-related lymphedema. Volumes were calculated based on circumferential measurements at several points of the upper limb pre- and postoperatively. Moving average method was used for comparison of the volume at each period (100days). Patency of 119 anastomoses in the 29 patients was evaluated by real-time ICG fluorescence lymphangiography after surgery with follow-up ranging from 5 to 51 months. We also asked the patients how they put or not compressive garments on the affected limb after surgery.

Results: The mean volume of the affected limb was 1232ml at the initial visit, 1173ml during 1 to 100 days before surgery, and 1146ml during 1 to 100 days after surgery. There were statistical difference between the volumes at initial visit and the mean of a 100-days period before surgery (effect of CDP) and between the mean volumes of a 100-days period before and after surgery (effect of LVSEA). Out of 119 anastomoses 61(51%; 61/119) were detectable. Out of 61 detectable sites 26(43%; 26/61) were patent. Cumulative patency rate decreased gradually over the period of about 4 years. Regarding the compressive garments, 14 patients became freed from putting the garments and contents of CDP were reduced in 11 after surgery.

Discussion: Although volume reduction by our surgical procedures was not much (average 86ml) like in the lower extremity, about a half of the patients became freed from compression garments, which improved QOL of the patients so much. The patency rate of LVSEA in the upper limb lymphedema was similar to that in the lower limb lymphedema in first one year but kept to be relatively high after one year later.

Conclusions: LVSEA is effective to reduce both volume of the affected limb and contents of CDP in the breast cancer related patients.

LIPOSUCTION OF LOWER LIMB WITH PITTING LYMPHEDEMA - CASE REPORT

WALD M.

Department of Surgery, Prague, Czech Republic

Introduction: Conservative treatment is not successful in some patients with lower limb lymphedema despite all efforts and significant fluid retention persists in the epifascial area particularly in the lower leg and around the ankle and foot – pitting lymphedema – contributing to the increased volume of the lower limb.

Materials & Methods: A case of a 70 year old woman with primary lymphedema of both lower limbs with progressive impairment of swelling of both legs and pronounced increase of volume in the area of lower leg, around the ankles and in the area of feet in the last 14 years is presented. There are early signs of fibrosis on the skin and subcutaneously. Because the long-term conservative treatment failed and patient's quality of life was significantly limited due to the volume and the heaviness of the lower limbs, liposuction was performed on the right lower limb even though it was a pitting lymphedema. Totally 5.500 ml was sucked up with adipose tissue: fluid ratio = 1:3. The postoperative course was uneventful.

Conclusion: Three months postoperatively, the volume of the surgically treated limb was 4.638 ml less than before the surgery (19.010 ml versus 14.372 ml). The epifascial soft tissues show markedly less fibrotic remodelling and the trophic skin condition improved. Theoretical presumptions of the soft tissues improvement in terms of both, their volume and quality are discussed in the lecture.

QUALITY OF LIFE AFTER LYMPHEDEMA SURGERY WITH LYMPHOVENOUS ANASTOMOSIS (LVA) IN SUPERMICROSURGERY TECHNIQUE

SEIDENSTUECKER K.¹, MUNDER B.², ANDREE C.², ZELTZER A.¹, HAMDI M.¹

¹ *University Hospital Brussel, Department of Plastic Surgery, Brussels, Belgium*

² *Department of Plastic Surgery, Hospital Duesseldorf, Germany*

Introduction: Previous authors showed that lymphedema impacts the Health related Quality of life in many dimensions. This study regards the improvement of the quality of life from patient suffering from lymphedema after the operative treatment with lymphatic venous anastomosis (LVA).

Material and Methods: From 2011 to the end of 2013 we have operated on 15 lymphedema patients. Of these, 2 involved the lower limbs and the rest were in the upper limb. Most of the patients had developed lymphedema as a result of axillary dissection for treatment of breast cancer. Various procedures have been attempted for draining lymph fluid into other lymphatic basins or into venous circulation. We performed lymphatic -venous anastomosis (LVA) in supermicrosurgery technique on the affected limb. To compound error in measurements to different dates with or without additional lymphatic manual compression therapy, we decided to evaluate the quality of life with a standardised questionnaire.

This questionnaire has two parts – first regarding the time before the lymphatic surgery and the second for the time after. It looks at three aspects of quality of life: physical health and constitution, mental health and social adverse effects and lastly adverse effects caused by the conservative therapy.

Results: In the first part related to the physical adverse effects before the operation was the average numbers 55% related to 100% best possible quality of life. After the operation the quality of life raised to 71%. So the relative improvement of the quality of life was 29%. Regarding the mental health and social adverse accounted 27% relative improvement from pre- to postoperative. Finally the adverse effects caused by the conservative therapy about compression garments and the frequency of manual lymphatic drainage the patients stated preoperative only 11% related to 100% possible quality of life. The 11% raised to 46% postoperative. The relative improvement is here more than 300%.

Conclusions: Lymphatic venous anastomosis is a promising procedure that increase the quality of life. Particularly it influence the adverse effects caused by the conservative therapy.

PONCTIONS FOR “SEROMAS” AFTER COMPLETE AXILLARY NODE DISSECTION (CALND) FOR BREAST CANCER (BC): INSTITUTIONAL SURVEY AND PRELIMINARY ANALYSIS

MIRELA ROMAN^{3,2}, JEAN-FRANÇOIS FILS⁴, PIERRE BOURGEOIS^{1,2}, AND JEAN-MARIE NOGARET³

³ Department of Mammo-Pelvic Surgery, ¹ Department of Nuclear Medicine, ² Clinic-Unit of Lymphology, Institut Jules Bordet, Université Libre de Bruxelles and ⁴ Ars Statistica, Belgium

Introduction: “Seromas” represent a frequent complication after CALND for BC. Their patho-physio-genesis remains the matter of discussions, of lymphatic origin (then also called “lymphocela”) and/or “simply” related to inflammatory exsudates, with various predictive factors being proposed. Such seromas may indeed require repeated and long lasting ponctions which can also be complicated by infections, events affecting all the patients’ quality of life. The aim of the work was to analyze the institutional situation and to try to define patients at risk for such events.

Material and methods: From 02/2012 to 09/2014, the medical reports of 223 women who had undergone CALND either after mastectomy (M: n=127), or after tumorectomy (T: n=96) for BC and who were followed in our Institute were reviewed in order to obtain the following informations: the number of ponctions (Np) performed, their volumes (V) (summed to obtain VpT and the mean V per ponction or VpMp), the dates of the first and the latest ones (Dp: to obtain one “volume per day” or VpMd), their age, their BMI, the presence or not of HTA, the date and kind of surgery (M/T), the number of axillary LN removed (nLN), the associated treatments, the V of liquids drained (after operation and before hospital discharge: Total or VdT and “per day” or VdMd), the occurrence or not of one infection at the level of the breast and/or arm.

Results: Only 18.7% of the patients after T and 9.45% after M had no ponction for seroma after hospital discharge. Patients who had M + CALND had significantly higher Np (median = 4 but up to 21), VpT (median = 1000 ml but up to 9045 ml), VpMp (median = 233 ml but up to 705), VpMd (median = 32.4 ml but up to 162), VdT (median = 390 ml but up to 1460), VdMd (88.9 ml but up to 212) and longer Dp (median = 26 days but up to 449) than patients who had T + CALND (corresponding medians equal to 2, 300 ml, 120 ml, 17.9 ml, 227 ml, 60.4 ml and 11.5 days). Statistical “Latent Profile” analysis allowed to define “clusters” of patients in the whole population with three groups (23.4% of the cases) showing a high Np and/or a high VpT and/or a long Dp. In this whole series, these situations were related in univariate analysis to the nLN, the VdT, the VdMd and to the realisation of one M. In multivariate analysis, only M and nLN remained statistically significant but with one AUC of only 0.7219, With regard to the problem of the infection, their risk increased statistically with Np.

Conclusions: This institutional survey highlights the problem represented by these post-operative “seromas” and their related ponctions. Our preliminary analysis allowed us to define “outliers”, e.a; patients with abnormally high Np and/or high VpT and/or long Dp. Work is in progress to try to find “immediate” post-op “predictors” identifying these cases in order to manage them differently.

THE CHONDROEPITROCHLEARIS MUSCLE: A RARE CAUSE OF AXILLARY VEIN THROMBOSIS AND LYMPHEDEMA

THOMET C.¹, BELGRADO J.-P.², VANKERCKHOVE S.¹, GRIJSELS S.³, DE SMET S.⁴, VANDERMEEREN L.⁴

¹ C.H.U. St-Pierre - Plastic Surgery Dpt, Brussels, Belgium; ² Université Libre de Bruxelles - Lymphology Research Unit, Bruxelles, Belgium

³ C.H.U. St-Pierre - Lymphology Clinic of Brussels, Belgium; ⁴ C.H.U. St-Pierre - Plastic Surgery Dpt, Brussels, Belgium

Key words: chondroepitrochlearis muscle – lymphedema – axillary vein – thrombosis – axillary vein compression

Introduction: The chondroepitrochlearis muscle is a rare anomaly of the pectoral muscle crossing over the neurovascular bundle in the axilla. Often associated with other supernumerary muscles like the arch of Langer, it has been reported in the past with restriction of abduction of the arm, cosmetic defects and compression of the ulnar nerve. This article describes the first known vascular complication due to a chondroepitrochlearis muscle, causing thrombosis and intermittent compression of the axillary vein. This resulted in pain, upper limb lymphedema and impaired movements. The diagnosis was suspected on history and by palpation and confirmed by dynamic ultrasonography. Surgery was performed to divide the muscle slip with help of lymphofluoroscopy to prevent harming the lymphatic structures.

Material and methods: A 41 years old woman consulted at the Lymphology Clinic of Brussels with chronic swelling of the right upper limb, associated with cold hand, itching, pain on exertion, and shoulder abduction restriction. She was diagnosed at birth with an angioma of the upper limb and treated with cryotherapy during infancy. A full workup 3 years before in another hospital with duplex ultrasound, CT and MRI ruled out a congenital vascular malformation and confirmed a chronic axillary vein thrombosis for which she was treated for one year with anticoagulants. A phlebography showed no residual thrombus after treatment. Patient was advised to wear a class I compression garment and work out. Her symptoms only worsened since then. Physical findings showed swelling of the right upper limb with a circumference difference of 1.5 centimeters between both wrists. She also presented telangiectasia all over her limb. On closer palpation of her axilla, an abnormal structure was found on the lateral border of her pectoral muscle, crossing the axilla in the direction of the humerus suspecting the diagnosis of a chondroepitrochlearis muscle. The diagnosis was confirmed by a dynamic ultrasound and duplex showing the compression of the axillary vein during shoulder adduction and protraction. Lymphofluoroscopy showed a normal and functional superficial lymphatic network. Surgery was planned under fluoroscopy control in order to prevent harming the lymphatic structures. A 2 centimeters incision was performed over the abnormal muscle and showed a tendinous slip of the epitrochlearis muscle above the axillary vein. The slip was divided to release the compression.

Results: Swelling and other symptoms decreased significantly immediately after surgery. After all, a mild consistent edema subsisted, which was treated combining exercises under multicomponents bandages and fluoroscopy-guided manual lymph drainage method.

Conclusions: In this symptomatic clinical situation, with intermittent axillary vein compression due to chondroepitrochlearis muscle, a surgical resection of the bundle supplemented by decongestive therapy was an effective treatment. Currently the edema and other symptoms are completely resolved.

THORACIC DUCT AND CHYLOUS DISORDERS

THE KEY ROLE OF THE ANATOMY ON THE CLINICAL AND SURGICAL TREATMENT

AMORE MIGUEL^{1,2}, GRANJA SANTIAGO¹, BERNARDEZ RICARDO¹, ENRIQUEZ ROMINA¹, DE FAZIO BELEN¹

¹ Normal Anatomy Department, Buenos Aires University, Argentina

² Phlebology and Lymphology Department, Central Military Hospital Buenos Aires, Argentina

Objectives: To carry out a detailed anatomical description of origin, pathway and termination of the thoracic duct, remarking the importance on the pathophysiology of the chylous disorders, translating these findings into the clinical and surgical treatment.

Methods: In this study, 20 cadavers (n=20) were injected. 8 adults and 12 fetuses.

The injection had been performed by a infusión pump directly on the thoracic duct at the inter azigoaortic recess, with a special solution developed by our group at the Buenos Aires University. Dissection had been carried out after appropriate fixation of the specimens in 40% formaldehyde for 10 days, and then immersed in a 100-volume hydrogen peroxide solution for 24 hours. At the end of the anatomical research we evaluated by a retrospective study the clinical presentation and the surgical treatment of 10 patients with chylous disorders at the Central Military Hospital.

Results: We evaluated the thoracic duct with special emphasis on the anatomical variations of the origin, the presence of the cisterna chyli, gastrointestinal trunk and others. The high incidence of the plexus formation at different levels and duplication. We extrapolated these concepts to the varied clinical presentation and the surgical treatment.

TWO YEAR FOLLOW-UP OF BREAST EDEMA AFTER BREAST CONSERVING SURGERY AND RADIOTHERAPY

JOHANSSON K.¹, HAJI SEYED EBRAHIM DARKEH M.², LATHINEN T.³, BJÖRK-ERIKSSON T.⁴, AXELSSON R.²

¹ Institution of Health Sciences, Lund University, Lund, Sweden

² Department of Clinical Science, Intervention and Technology, KI, Stockholm, Sweden

³ Cancer Center, Kuopio University Hospital, Kuopio, Finland

⁴ Department of Oncology, Sahlgrenska University Hospital, Gothenburg, Sweden

Introduction: Measurement of local tissue water with tissue dielectric constant (TDC) can improve detection of early edema in patients after breast cancer treatment. The purpose of the present study was to examine development of breast edema and subjective sensations during a 2-year follow-up in breast cancer patients treated with breast conserving surgery and radiotherapy (RT).

Materials and Method: From previous data including 200 breast cancer treated patients (surgery+ RT) it could be identified 65 patients that in common participated in all 10 measurement time-points (before start of RT, three time-points during RT, 2 and 4 weeks after RT and then 3, 6, 12 and 24 months after RT). Definition of breast edema was determined as a TDC ratio ≥ 1.40 between the treated and healthy breast. The experiences of tension, heaviness and pain of the affected breast were each determined on a 100 mm horizontal visual analogue scale (VAS) by the patients. The endpoints were "no discomfort" (0 mm) and "worst imaginable" (100 mm). Each patient was asked to score her subjective sensations at each time-point. Data were analyzed by SPSS using descriptive statistics, Friedman ANOVA test, chi-square test and Wilcoxon matched pairs test.

Results: The mean TDC ratios at the end of the third week of radiotherapy and at 3 and 6 months post-RT were all critical (i.e. over 1.40). Significant differences were found between the mean TDC ratios before the start of RT and the other time-points (p-values between 10⁻⁶ and 0.02), and between three/six months post-RT and the other time-points (p-values between 10⁻⁶ and 0.001), and between two year post-RT and the other measurement-times (p-values between 0.01 and 0.02). The largest proportions of patients with critical TDC ratios were found at three and six month post-RT (63%) and the smallest proportions at two years post-RT (28%). On the subject edema in the breast or in the arm/axilla in patients with axillary dissection or sentinel node biopsy, no statistically significant differences were found between the groups at any of the 10 different measurement time-points. The ANOVA test showed significant differences between measurement occasions regarding the mean tension, heaviness and pain VAS scores (p < 0.01 in each of VAS scores).

Conclusions: Cancer treatment related edema in the breast is very frequent at three to six months after radiation treatment but decreases at one to two years. The subjective sensations of tension, heaviness and pain are each the highest at the third week of the radiotherapy and the lowest two years after the treatment.

**LYMPHATIC VESSELS - REMARKS CONCERNING OF MORPHOLOGY REGULARITY OR IRREGULARITY.
ARE THEY IMPORTANT FOR FUNCTION OF LYMPHATICS?**

OLDRICH ELISKA

Department of Anatomy, First faculty of Medicine Prague, Charles University Czech Rep.

We present short overview of some main irregular morphology features or specialities of lymphatics.

Material and methods: Samples of lymphatics were taken from normal human being and patients with lymphedema, from cadavers and animals-dogs. Samples processed by translucency methods with methyl salicylate, histology and electronmicroscopy methods and compared with clinical lymphangiography and lymph flow morphology changes and irregularities were found in these cases:

A/Macroscopy appeareance of lymphatics

B/Microscopy

1/Initial lymphatics:

a/ pattern of lymphatics in young people and conversaly in old age -atrophy

b/ closed and open junctions, types of interendothelial contacts in normal conditions and different illness

c/ vesicular systém endothelial cells contra interendothelial junctions

d/ actinmyosin complex in endothelial cells

2/lymphatic collectors

irregular structures of the wall of lymphatic collectors

myoendothelial junctions

lymphovenous anastomoses

different shape of lymphatic valves and lymphangions

Results: With structural irregularity of lymphatic wall, the lymphatics differ from arteries and veins which in contrast to lymphatics are more regular. In one tributary region two lymphatics of the same diameter that drain the region are not same from morphology point of view. These features can influence the physiology-lymph flow.

MODERATED POSTER SESSION 3

ANATOMICAL DEFORMATION OF TISSUE IN LYMPHEDEMA - FLUID CHANNEL FORMATION, EFFECT OF INTERMITTENT PNEUMATIC COMPRESSION

ZALESKA M.¹, OLSZEWSKI W. L.¹, KACZMAREK M.²

¹ Central Clinical Hospital, Medical Research Center, Warsaw, Poland

² Kazimierz Wielki University, Bydgoszcz, Poland

Objectives: We observed formation of tissue channels in advanced obstructive lymphedema increasing in density during high pressure intermittent pneumatic (IPC) therapy.

Methods: Twenty patients with lymphedema stage II/III of lower limbs were investigated. Tissue morphology was evaluated before and after 1 year of intermittent pneumatic compression. Parameters of compression were: inflation pressure 120-100mmHg, sequentially from chamber 1 to 8, inflation time of each chamber 50'', daily for 1 h. Lymphoscintigraphy with Nanocoll was performed before, after 6 and 12 months of treatment. Skin and subcutaneous tissue biopsies were taken before and after treatment. Specimens were injected with Paris Blue in chloroform and made translucent to visualize spaces filled with mobile tissue fluid.

Results: Lymphoscintigraphic imaging. Multiple wide irregular spaces filled with tracer could be seen in the subcutis on the internal aspect of thigh and along large blood vessels running to the groin. There were no such structures around the hip, in hypogastrium and buttocks. Immunohistochemistry of biopsies revealed presence in subcutis and around veins open spaces negative on staining with LYVE1. These spaces were then stained with Paris Blue and presented irregular interconnected spaces. Their density was measured using computer planimetry (Microimage, Olympus). After 1 year of IPC the total area occupied by depicted channels was found slightly increased in calves but evidently more in thighs.

Conclusions: Increase in stagnant tissue fluid in lymphedematous subcutis is followed by formation of irregular tissue channels. Their density increases after IPC. These channels substitute obliterated lymphatic collectors. Flow in these channels requires active external compression.

THE EFFECTS OF THREE-YEARS PNEUMATIC COMPRESSION OF POSTINFLAMMATORY AND POSTTRAUMATIC EDEMA OF LOWER LIMBS

ZALESKA M., OLSZEWSKI W. L.

Central Clinical Hospital, Medical Research Center, Warsaw, Poland

Background: Chronic edema of lower limbs after trauma, venous ulcers and recurrent dermatitis is a serious disabling complication affecting millions around the world. The cause of edema are chronic inflammation and venous and lymph stasis. The only solution for therapy of these large cohorts of patients is mechanization of treatment using mechanical devices for intermittent pneumatic compression (IPC).

Aim: To investigate how effective is a 3 years continuous daily high pressure, long inflation time IPC therapy in decreasing limb circumference/volume, tissue elasticity, histological changes and incidental complications.

Methods: Twenty randomly selected patients with unilateral lower limb post inflammatory and posttraumatic edema stage II to IV were treated daily for a period of 3 years with a pneumatic device, 8 chamber sleeve, sequential inflation of chambers to 100-120 mmHg for 50 sec (total 400sec) and no distal deflation, and 50 sec sleeve deflation time. The changes in limb circumference and tissue tonicity were measured at monthly intervals.

Results: Treatment revealed durable decrease of limb circumference and increased elasticity. Improvement was most expressed in the calf above the ankle and mid-calf. Limb circumference was decreased or at least stabilized, elasticity of tissue was increased and maintained. No complications as thigh ring or chronic genital edema were observed.

Conclusions: IPC takes over the transport function of stagnant tissue fluid from the insufficient veins and obliterated lymphatics by squeezing edema fluid to regions with normal drainage. Long term, high pressure IPC, long inflation timing therapy can be safely be recommended to patients with lower limb edema.

A NOVEL CLINICAL TEST FOR SETTING INTERMITTENT PNEUMATIC COMPRESSION PARAMETERS BASED ON EDEMA FLUID HYDROMECHANICS IN THE LYMPHEDEMATOUS CALF

OLSZEWSKI W. L., ZALESKA M.

Central Clinical Hospital, Medical Research Center, Warsaw, Poland

Introduction: Increasing number of patients with lymphedema of limbs requires development of new simple methods with easy access. To obtain satisfactory results knowledge of hydromechanic events under the applied hand or device became necessary. The Linforoll device is the first ever construction for manual edema fluid drainage allowing standardization of applied force depending on local anatomy of soft tissues and their tonicity, timing of applied force, unidirectional fluid movement, detecting sites of increased tissue hydraulic resistance and painful inflammatory foci.

Aim: 1. To compare Linforoll applied force (pressure) with skin interface and subcutaneous edema fluid pressures, observe proximal movement of fluid (strain gauge plethysmography), increase of tissue elasticity (using deep tonometer), and movement of edema fluid on lymphoscintigraphy. 2. Establish indications for Linforoll application.

Methods: Twenty-five patients with lymphedema of lower limbs stage II-III were included. Eight patients underwent implantation of silicone "new lymphatics" Linforoll massage was applied for 45 min to 8 lower limb areas.

Results: Manual massage showed unpredictable pressure values ranging between 50 and 120 mmHg. Using Linforoll we could regulate pressure in range of 50 to 80mmHg. Higher force could be applied in hard tissues. Painful areas could be detected indicating inflammatory foci requiring additional antibiotic therapy. Fluid movement in proximal direction recorded on plethysmography showed values of 2-4 ml/25 rollings/area. A significant increase in elasticity was observed in all cases. Rolling moved fluid along the implanted tubings.

Conclusions: The novelty of the device is:

1. Regulation of the applied force depending on hydromechanic conditions of the massaged tissues,
2. Standardization of massage method based on evidence and not therapist's hand,
3. Evident increase in tissue elasticity proving less fluid,
4. Application, beside of routine massaging, as a driving force for fluid along implanted tubings and possibly lympho-venous shunts.

NEW DEVELOPMENTS IN THERAPY OF LYMPHEDEMA – LINFOROLL AND ITS APPLICATION

OLSZEWSKI W. L., ZALESKA M.

Central Clinical Hospital, Medical Research Center, Warsaw, Poland

Background: Long term observations confirm durable effects and lack of complications of the intermittent pneumatic compression (IPC) therapy. So far no test has been designed providing data necessary for setting pressure and time of IPC device to obtain maximum decrease in limb volume.

Aim: To design a test providing data on decrease of circumference under inflated chamber depending on compression time and pressure.

Methods: One chamber was placed above ankle joints and inflated to 120 mmHg to occlude tissue fluid backflow during inflation of the proximally located test chamber. The latter was inflated sequentially to 50, 80, 100 and 120mmHg, for one and three minutes each. Calf circumference changes were recorded continuously using plethysmographic strain gauges placed under and proximally to inflated chamber.

Results: Four different types of recorded circumference change curves were observed. The first was decrease under and increase proximally to inflated chamber, another showed decrease under inflated chamber and little change proximally, the third small decrease under chamber but increase proximally and the fourth no change under and proximally. Depending on steepness of obtained curves pressures and timing of IPC device were set to values bringing about edema fluid mobilization.

Conclusions: Two-chamber inflation-deflation test provides data on circumference changes during calf IPC, time necessary to obtain maximum decrease of circumference and insight into tissue elasticity. These data are useful for setting compression devices at levels bringing about decrease in limb swelling and may be of prognostic value with respect to efficacy of long-term use of IPC.

HYDROMECHANICS OF TISSUE EDEMA FLUID UNDER COMPRESSION BANDAGES

ZALESKA M., OLSZEWSKI W. L.

Central Clinical Hospital, Medical Research Center, Warsaw, Poland

Background: Bandaging is an integral part of complex decongestive therapy of lymphedema. The conditions effective bandaging should meet are: generating tissue fluid (TF) pressures high enough to mobilize and propel fluid and maintain the on-limb elasticity of bandage material for hours, both at rest and during muscle contractions. How high is the TF pressure at the site of application of bandages remains unknown. Moreover, it is unknown how much fluid moves proximally after applying bandage compression.

Aim: To measure simultaneously the subcutaneous TF and bandage-skin interface pressure, as well as TF flow after application of bandages, with increasing compression force.

Methods: Twenty patients with lymphedema of lower limb stage II were investigated. Bandage-skin interface and TF pressures were measured after application of one and two layers of elastic or short-stretch bandages. TF flow was measured during bandaging with plethysmography.

Results: TF pressures generated by bandaging were lower than those at the bandage-skin interface. The difference ranged from 10 mmHg in soft to 30 mmHg in cases with hard skin. Two layer bandaging maintained stable TF pressures. Muscle contractions generated TF amplitude only up to 10 mmHg. There was a continuous drop of TF pressure due to evacuation of TF, more evident under short-stretch bandage. Flow volume depended on the TF pressure level, being lower in limbs with hard skin.

Conclusions: To obtain effective TF pressures generating flow, external pressures by bandaging should be set at the bandage-skin interface of around 60 or more mmHg.

THE RIGHT TREATMENT OF LYMPHANGITIS: FROM EARLY DIAGNOSIS WITH SPECIFIC CLINICAL SCORE TO A CORRECT SHORT STRETCH BANDAGE ALSO WITH NEW MANUKA HONEY DRESSING

ALBERTO MACCIÒ¹, FRANCESCO BOCCARDO², GIOVANNA CAVALLERO, SALVATORE GERMANO, CORRADINO CAMPISI²

¹ Italian Lymphological Center, ICC member, Italy

² IRCCS University Hospital San Martino - IST National Institute of Cancer Research, Genoa, Italy

The septic complication of chronic lymphostasis also known as lymphangitis is very frequent in daily practice of Clinical Lymphologist. With the Stewart-Treves Syndrome (Lymphangiosarcoma), the infection in patients with diseases connected to insufficiency of lymphatic circulation represents the principal life-threatening problems in our therapeutic approach.

In this paper, we will show you our specific experience about the early diagnosis and the proper treatment of the lymphangitis.

As we know, the primary and secondary prevention of microbial infection is a first and fundamental step in reducing the recurrences of the septic complication in chronic lymphostasis like decreasing the risk factors. In any case, the number of these relapses is increasing today in the same way as the prevalence of lymphatic diseases in the world.

We have estimated almost 1% of the patients who are accepted in the emergency room showing signs and symptoms related to the potential infection with primary involvement of lymphatic circulation.

For these cases we use the Lymphangitis score to recognize very early the high risk of infection overall in chronic lymphedema patients. From our experience, after evaluating more than 300 non traumatic acute diseases we have seen a very high sensibility (> 99%) of this test versus a good specificity value (94%).

Once the complication is suspected the therapy should have two principal approaches. First is the prescription of systemic antibiotics, broad spectrum or guided by clinical signs. The second approach is using the appropriate short stretch bandages of the limb with zinc oxide or new manuka honey dressings to reduce the edema and improve the peripheral lymph flow. In our presentation, we will show you both procedures which include the protocol for choosing an antibiotic and the correct pressure when applying the bandages.

Estimating correctly the lymphangitis complication and the early treatments to be taken are the most important things to help the patients with chronic lymphatic diseases.

EFFECT OF MANUAL LYMPH DRAINAGE AND COMPRESSION BANDAGE ON HEMATOMA AFTER SUPRASPINATUS TENDINITIS RUPTURE

YESIM BAKAR, PT, PhD, Associate Prof., ELIF ZORGÖR, PT

Abant İzzet Baysal University, School of Physical Therapy and Rehabilitation, Bolu, Turkey

Introduction: Hematoma is an accumulation of blood in the tissues due to bleeding. It's occur when blood vessels rupture, after tissue injury or by other damage. We report a case with a big hematoma in the right arm after a supraspinatus tendinitis rupture.

Materials & Methods & Results: Our case was 62 years old. After a supraspinatus rupture, an injection for inhibition was performed on the supraspinatus muscle. But 3 days after this application, he becomes a hematoma on his right upper extremity (upper arm, elbow, arm, hand). He has extremely pain and pitting edema. We apply with very light pressure manual lymphatic drainage and began from the axillary lymphatic nodes. Because of his pain, we could only drainage until the elbow. After 3 days, we could drainage up to the hand. The first 5 days we apply the compression bandaging with a very light pressure until elbow. After the first 5 days, we apply the badage up to the shoulder. The hematoma was reduced completely in the arm. But the edema was reduced after the 12th day. The patient doesn't have pain and edema after manual lymphatic drainage and mild compressions bandage.

Conclusions: Lymphatic drainage and compressions bandages are an effective treatment method in posttraumatic-postoperative hematoma.

IS THERE AN INTEREST TO PERFORM TWICE DAILY SHORT-STRETCH MULTICOMPONENT BANDAGING DURING HOSPITAL INTENSIVE TREATMENT OF LOWER LIMB LYMPHEDEMA?

LESSERT C., LUTHI I., TOMSON D., MAZZOLAI L., DEPAIRON M.

Division of Angiology, Lausanne University Hospital, Lausanne, Switzerland

Introduction: Pressure exerted by short-stretch multicomponent bandages (MCB) on the limbs progressively decreases with edema resorption. The aim of this study is to assess whether intensive LO hospital treatment should include twice daily MCB using PicoPress transducers to analyze pressure evolution in skin bandage interface.

Methods: Consecutive patients with chronic primary or secondary lower limb lymphedema (LO) were hospitalized for intensive treatment. Treatment consisted in twice daily (10 a.m. and 2 p.m.) skin care, manual lymphatic drainage (MLD), and short-stretch MCB until the thigh. MLD and MCB were alternatively performed by the same two experienced physiotherapists in all patients. Following MLD, all patients underwent MCB consisting in a first layer of cotton tubular protection, followed by wadding bandages, foam bandages (0,2 cm thickness at the foot and calf level, 0,4 cm at the thigh), and a final short-stretch bandage (Rosidal K®). Pressure exerted by the MCB was measured using the PicoPress instrument (Microlab®, Italy) soon after bandaging positioning (basal values) and 4 hours thereafter just prior to second daily MLD and application of a new bandage. PicoPress transducers were placed in the skin-bandage interface at the ankle and thigh levels. Pressure detected by the transducer was measured by a microprocessor digital gauge and visualized by means of an alphanumeric display. Patients were instructed to conduct "usual" life with no restriction in terms of mobility. PicoPress values were expressed in mmHg and results presented as difference between values obtained after 4 hours of compression and basal levels. Pressure was measured both in the lying and standing position. Statistical analysis was performed using the paired student t-test.

Results: 14 patients (50% women, mean age 59±3.7 years) were included in the study. Twelve patients presented with chronic secondary LO since an average of 188±45 months. A mean of 12±1 treatment sessions were performed. Average ankle and thigh pressure difference after 4 hours of MCB was as follows:

	Ankle (Δ mmHg)	Thigh (Δ mmHg)
Lying position	-13±2*	-11±2*
Standing position	-12±3*	-9±2*

Conclusions: Data presented herein show that pressure exerted by MCB significantly decreases within few hours from application. This suggests that intensive LO treatment should include twice daily MCB in order to achieve constant pressure and likely enhance final treatment results.

EFFECT OF INTERMITTENT PNEUMATIC COMPRESSION ON QUALITY OF LIFE AND EDEMA IN PATIENTS WITH CHRONIC VENOUS INSUFFICIENCY

ÖZLEM ÇINAR ÖZDEMİR PT. PhD. Assist. Prof., YEŞİM BAKAR PT. PhD. Assoc. Prof.
Abant İzzet Baysal University, School of Physical Therapy and Rehabilitation, Bolu, Turkey

Introduction: The aim of the study was to investigate the effect of intermittent pneumatic compression on quality of life and edema in people with chronic venous insufficiency

Materials & Methods: This study involved 28 individuals stage 2 chronic venous insufficiency. Individuals were divided into two groups and the first group (n=14) was included in consisting of intermittent pneumatic compression (IPC), skin care, compression stockings and exercise, the second group (n=14) was included in a program consisting of compression stockings, skin care and exercise. The mean age of the subjects in the study at the IPK group was 51.86 ± 9.63 year and in the stocking group was 53.29 ± 14.45 year. Edema quantities were measured by Leg Q Meter using limb circumference, and pain assessment was done with "Visual Analogue Scale". General quality of life was measured by "Nottingham Health Profile"(NHP), disease specific quality of life was determined by using "Venous Insufficiency Epidemiological and Economic Study-Quality of Life/Symptoms" and depression state assessment was done by using "Beck Depression Scale". Participants taken in treatment 5 days per week along 4 weeks. Individuals were assessed pre-treatment, post-treatment and 4 weeks later after treatment(control measurement).

Results: There was found significant difference about circumference measurements of CC (Thigh), CE (Knee), CG (Groin) pre- and post-treatment time by the comparison of compression stocking and IPC groups ($p < 0.05$). Also there was found significant difference in pretreatment-control circumference measurements of CF (Thigh) ($p < 0.05$). By the comparison of stocking and IPC groups' NHP values, there was found significant difference in pre-treatment and post-treatment time ($p < 0.05$). When analyzed average changes between pre-treatment time and post-treatment time in groups, maximum change occurred in IPC group.

Discussion: Chronic venous insufficiency is a chronic disease which effects badly patient's quality of life by starting edema clinical view. We think that using compression stocking and apply IPC treatment approach from early phase of disease will decrease the symptoms and contribute increasing the quality of life.

MODERATED POSTER SESSION 4

FLUORESCENCE MICROLYMPHOGRAPHY: OFFICE-BASED DIAGNOSTIC POTENTIAL FOR DETECTING LYMPHOEDEMA

HONG H. KEO, MD, MS¹; SILVIA B. GRETENER, MD²

¹ Kantonsspital Aarau Ag, Medizinische Universitätsklinik, Abteilung für Angiologie, Aarau, Switzerland

² Angiologie Oberaargau, Langenthal, Switzerland

Introduction: Lymphoedema is a chronic, progressive and common but often unrecognized condition. The clinical diagnosis of lymphatic disease in the early stage remains a challenge.

Decades ago direct contrast lymphangiography has been used to investigate lymphatic disorders by direct cannulation of lymph vessels. However, it has been largely abandoned because of the technical complexity of the procedure, the challenge to repeat the test and the unacceptable complications. Conventional MRI and CT scan can be used to evaluate the presence and severity of oedema, but differentiation of lymphedema from oedema associated with other internal medical diseases is not possible. Lymphoscintigraphy, which has been reported to be 100% specific and 92% sensitive for detecting lymphedema has been challenged in recent publication. Ideally, an office-based test without exposure to ionizing radiation is needed to rule out or confirm lymphatic disease prior to sophisticated and expensive alternative testing.

Material & Methods: Literature review

Results: Fluorescence microlymphography (FML) is a useful office-based test in evaluating lymphedema and has been introduced in the early eighties by Bollinger and colleagues. This test has been used in Switzerland for more than 30 years and is reimbursed by health insurance. Current research confirms its important diagnostic role. The principle is based on the fact that large molecules in the interstitial space are primarily drained into and via the lymphatic system. In order to detect the fluid and the lymphatic system fluorescent tracer attached to a macromolecule injected into the interstitial space of the skin was proposed. The sensitivity and specificity of this test has recently been reported to be 91.4% and 85.7%, respectively.

Conclusion: In this review, we provide a comprehensive summary of FML as a practical office-based diagnostic tool for detecting lymphoedema in uncertain cases.

PATHOPHYSIOLOGICAL CONSIDERATIONS ABOUT RADIOCOLLOID KINETICS IN LYMPHOEDEMA OF LOWER EXTREMITIES

VILLA G., BOCCARDO F., MOLINARI L., DESSALVI S., CAMPISI C.

IRCCS S. Martino – IST National Cancer Institute, University of Genoa, Italy

Introduction: Lymphoedema of the lower extremities is a relatively common chronic and incurable disease. Early diagnosis and treatment is essential in preventing the progression of the disease and its complications. Lymphoscintigraphy is the preferred and noninvasive diagnostic modality of lymphoedema. However, there are problems concerning the reliability of the interpretation of this procedure. Qualitative interpretation of the images alone is very observer dependent. Quantitative lymphoscintigraphy, where the lymph transport capacity is being estimated, offers an objective measure for lymphatic function and has been shown to have higher sensitivity and specificity. Kleinhans developed a transport index in which time for transport to regional lymph nodes, appearance of lymph vessels and nodes and distribution pattern were scored. Another objective measure of dynamic lymphatic function is the determination of the rate of movement of the tracer from the extracellular matrix through the lymph capillaries. Understanding of physiological mechanisms of the lymphatic kinetics is very relevant in order to obtain quantitative parameters.

Materials and methods: Twentyfour subjects suffering from monolateral or bilateral lymphedema of lower extremities underwent lymphoscintigraphy. It was performed in different days by injecting 37 MBq of technetium 99m-nanocolloid subcutaneously into the first interdigital space of the feet and subfascially in the plants, in order to explore superficial and deep lymphatic circuits. Total body images were recorded after 1 and 24 hours from the injections. Uptake in inguinal nodes and sites of injection were calculated and corrected for radioisotopic decay.

Results: After epifascial injection (superficial circulation), in affected and healthy extremities inguinal nodes/sites of injection uptake ratio increased respectively from 3.1% and 6.2% at 1 hour to 45.2% and 57.8% after 24 hours. Mean decay corrected counts from injection site reduce by 50% in 24 hours and in inguinal nodes increase by 700%. After subfascial injection (deep circulation), affected and healthy extremities inguinal nodes/sites of injection uptake ratio were respectively 16.4% and 31% at 1 hour.

Conclusions: Inguinal nodes/injection site uptake ratio is significantly higher in healthy than in affected extremities, as expected. Our results demonstrate a washout from the injection site correlated to a very considerably increases of radioactivity in the draining nodes. The washout from the depot is significantly faster when subfascial injection was performed, indicating an high-speed flow through the deep channel of the limb. We underline that the arrival from the injection site into the nodes compensates for the radioactive decay up to 24 hours. This finding could be of great interest for the radioguided surgery, in order to assess the best timing of the tracer injection.

INTEREST AND INDICATIONS OF SPECT-CT FOR THE LYMPHO-SCINTIGRAPHIC INVESTIGATIONS OF THE SECONDARY UPPER LIMB EDEMAS (ULE)

BOURGEOIS P.

Institute Jules Bordet, Brussels, Belgium

Introduction: The SPECT-CT approach has proven its interest in the management-definition of the SLN in various cancers but also of the lower limb edemas. To our knowledge, the interest and indications of SPECT-CT for the ULE have however not been analyzed. This is the aim of the present report.

Material and methods: From 2011 to now, 55 SPECT-CT were performed (in addition to the classical “planar” three phase of our protocol of lymphoscintigraphic investigations) in 53 patients with ULE (n=46) and/or “lymphocela” (n=4) and/or lymphorrea (n=5) and/or mammary edema (n=3) and/or “seroma” (n=4) (and in one case with Gorham’s disease). Planar imagings were analyzed and compared to the informations given by the SPECT-CT and the author tried to identify and define the situations for which SPECT-CT represented one additional value and why.

Results: In Gorham’s disease, SPECT-CT showed the osseous lesion in relation with lymphatic abnormalities. In patients with foci of activity at the level of the arm on planar imagings, SPECT-CT defined more precisely the depth of the LN and these more precise localisations can be usefull for the physical therapists. However, such localisations raised no diagnostic problem. SPECT-CT appeared more interesting when LN foci of activity were seen in the apex of the axilla and/or in retro- and/or supra-clavicular areas sometimes with lymphatic vessel(s) seen “superficial” on planar imagings. In 11 patients, these LN could indeed be demonstrated to be not in the axilla but very superficial and in fact related to one superficial collateralisation lymphatic pathways (described By Caplan and Mascagni), what represent one important information for the physical therapists. In three additional cases, other kinds of lymphatic collateralisation (not obvious on planar imagings) could also be demonstrated in the same area. Finally, SPECT-CT was also usefull in three patients for whose axillary foci of activity were confirmed to be related to one true lymphocela and not to LN.

Conclusions: Compared to planar imagings, SPECT-CT appears in our analysis of this series useful in at least 30% of the patients, especially in case of suspected lymphorrea-lymphocela and/or when planar imagings show foci of activity in the apex of the axilla and/or in retro- and/or supra-clavicular areas.

ON THE RELIABILITY OF TONOMETRY: A PILOT STUDY OF INTER-RATER CONSISTENCY AND RELATED PSYCHOSOCIAL FACTORS UNDERLYING THE FORMULATION OF TONOMETRIC JUDGMENTS

MICHELINI S.¹, CALDIROLA R.², MICHELOTTI L.¹, RICCI M.³, CESTARI M.⁴, CARDONE M.¹, PANTALEO G.⁵

¹ San Giovanni Battista Hospital - ACISMOM, Rome, Italy

² San Leopoldo Hospital, Merate, Lecco, Italy

³ Azienda Ospedaliera Universitaria - Ospedali Riuniti di Ancona, Italy

⁴ Riabilitazione Territoriale ASL4, Terni, Italy

⁵ Università Vita-Salute di Milano, Italy

Introduction: Tonometric judgments are critical in the diagnosis and treatment of lymphedema. Yet, while some studies (e.g. Lye *et al.*, 2006) claimed the reliability of particular mechanical tonometric instruments, in summarizing the main findings of their systematic review Oremus *et al.* (2010) recently concluded that “there is too little evidence to draw conclusions about the reliability of [diagnostic] tests such as *tonometry*.” (p. 4, emphasis added).

Materials and Methods: To fill this gap—a tangible lack of knowledge of great import both for the literature and even more for good clinical practice—we instructed a team of trained raters to independently supply distinct sets of tonometric judgments with respect to (a) patients with diagnosis of lymphedema (the *clinical sample*), and (b) their healthy counterparts (the *comparison sample*). Each judgment was supplemented by the assessment of two additional distinctive features lying at the core of any judgmental process—the degree of *difficulty* and the degree of *certainity* reported by the judge in formulating tonometric judgments.

Results and Conclusions: We will illustrate and report on the preliminary stage of this developing research endeavor, and possibly also suggest some initial conclusions on the basis of our earliest results.

Keywords: tonometric judgments, tonometry, inter-rater reliability, judgmental processes.

LYMPHOFLUOROSCOPY-GUIDED MANUAL LYMPHATIC DRAINAGE – A NEW EVIDENCE BASED APPROACH

BELGRADO J.-P.¹, VANDERMEEREN L.², VANKERCKHOVE S.², VALSAMIS J.-B.¹, GIACALONE G.³, SINÈGRE A.¹, MORAINÉ J.-J.¹

¹ Université Libre de Bruxelles - Lymphology Research Unit, Bruxelles, Belgium

² C.H.U. St-Pierre - Lymphology Clinic of Brussels, Belgium

³ University of Hasselt - Lymphatic Surgery, Hasselt, Belgium

Background: According to international guidelines, lymphedema must be treated by complete decongestive therapy (CDT), including Manual Lymphatic Drainage (MLD), Multicomponent Bandaging (MCB), sleeves and skin care. The application of this complete set of ingredients is consensually recognized by the “lymphologist” community to be efficient to reduce lymphedema. Meta-analysis on the efficiency of MLD conclude that the current evidence from RCTs does not support the use of MLD to prevent or reduce lymphedema.

Method of manual lymphatic drainage were historically conceptualized and based on indirect and multivariate data but not yet on easy visualization of the living human superficial lymph flow. It is currently possible thanks to near infrared fluoroscopy (NIRF).

In this study NIRF was used to evaluate lymph flow mean velocity in healthy subject in rest conditions, and applying an optimized MLD manoeuvre developed under NIRF feedback.

Method: The protocol used for this exploratory study was approved by the Ethical Committee (OM_026 CE2013/96) and by the Federal Agency for Medicines and Health Products (EudraCT n° 2013-001360-36).

On the forearm of healthy volunteers we delimited a rectangular landmark with a fluorescent pen. After unilateral intradermal injection of 0,2mg ICG in the first interdigital space, videos of lymph flow were acquired during rest period as baseline, and during MLD manoeuvres. Video sequences were blindly analyzed using IC-CALC 2.0 software. At a known distance, two regions of interest (ROI's) were delimited in which variation of fluorescence intensity was evaluated during lymph transfer. Time needed for a bolus of lymph to transfer between the two ROI's allowed us to estimate mean lymph velocity.

Results: 14 healthy volunteers, mean age of 52 years \pm 10 years, were consecutively recruited.

The mean lymph velocity in rest condition was evaluated at 0,0056 m/s \pm 0,0018 m/s and reached 0,0243 m/s \pm 0,0148 m/s during optimized MLD manoeuvres.

Fluoroscopy feedback allowed us to characterize optimal forces to be applied in order to improve manual lymph drainage efficacy.

Two consecutive and repeated steps are needed:

“fill in” movement (4X) to transfer fluids from the interstitium to the lymphatic network, and

“flush” movement (2X) to propel lymph along the collectors. This is a component of the “fill and flush” method.

Conclusion: Lymphofluoroscopy seems to be an efficient and easy tool to study MLD technique on the superficial lymphatic network. The “fill and flush” method designed thanks to fluoroscopy feedback allowed transferring fluids from the interstitium to the lymphatic vessels and increasing fivefold lymph propagation into the collectors.

ACOUSTIC STRUCTURE QUANTIFICATION (ASQ): A NON-INVASIVE TOOL TO DETERMINATE LYMPHEDEMA TISSUE CHANGES?

TASSENOY A.¹, VANDERHASSELT T.², ADRIAENSSENS N.¹, LIEVENS P.¹

¹ Department of Rehabilitation Research, Free University of Brussels, Laarbeeklaan 103, 1090 Brussels, Belgium

² Department of Radiology, UZBrussels, Brussels, Belgium

Background: The aim of this study was to determine the validity and reliability of the ASQ scoring method on an echographic image and to investigate whether ASQ values could be linked to different stages of lymphedema as observed by the patient's own perception, the volume difference with the healthy arm and tissue changes observed on ultrasound images.

Methods and results: It is an observational survey with a cross-sectional design. 9 healthy subjects and 31 breast cancer patients, with different stages of lymph edema, were enrolled in the study. After completing a questionnaire concerning personal, demographic and medical data, arm volume of both arms were determined using an opto-electric perometer. Four ultrasound images were made on different standardized locations of both arms. The ASQ scoring method of raw ultrasound images showed a high inter- and intra-observer reliability, with intraclass correlation coefficients ranging from .894 to .995 in the patient group (from .883 to .998 in the control group). The correlation of the ASQ-scoring on raw data images with echogenicity analysis on standard ultrasound images delivered a Spearman's r between $r_s = .785$ and $r_s = .969$. Based on observed tissue changes, ASQ could make the distinction between acute “fluid like” changes and chronic “fibrotic” tissue changes. Patients with a volume difference of $>10\%$, had significant higher ASQ-values, than patients with less edema. No statistical difference in ASQ-value could be made based on patient's own perception.

Conclusions: ASQ-scoring of ultrasound images of lymphedema can be a useful tool in staging lymphedema.

THE VALUE OF STEMMER'S SIGN AND LYMPHOSCINTIGRAPHIC ABNORMALITIES IN THE DIAGNOSIS OF LIPEDEMA

ISABEL FORNER-CORDERO¹, JOSE MUÑOZ-LANGA², MARÍA PÉREZ-POMARES¹, ANA BELÉN PONCE-GARRIDO¹, LOLA MORILLA-BELLIDO¹

¹ Lymphedema Unit, Hospital Universitari i Politècnic La Fe, Associate professor, University of Valencia, Valencia, Spain

² Oncology Unit, Hospital Peset, Valencia, Spain

Background: Lipedema is a frequently misdiagnosed disorder in women. Lipedema is characterized by bilateral enlargement of the lower limbs due to abnormal depositions of subcutaneous fat, associated with bruising and pain. Diagnostic criteria are not established yet.

Material and methods: Prospective cohort study in patients with clinical criteria of lipedema.

Aim: To describe most frequent clinical features, radiological, laboratory and hormonal values in order to set diagnostic criteria.

Results: From September 2012 to December 2014, 93 patients were included in the study.

All the patients had bilateral and symmetrical involvement; 86% disproportion with upper part of the body; 90.3% spare feet; 92.5% pain; 88.2% bruising; 82.8% absence of Stemmer sign.

The most frequent type of lipedema was Type 3, from hip-to-ankles (62.4%). The stages of lipedema were well distributed between stages I to III (I: 34.8%; II: 33.7; III: 26.1%).

Lymphoscintigraphic abnormalities were present in 40% of the patients, most of them were mild (87.5%). Patients below 40-years-old suffer more frequently from type III of lipedema (88.9%) ($p=0.001$). Severity of lipedema increased with the age of the patient ($p<0.0001$).

Stemmer's Sign is positive in older patients ($p=0.79$), in more advanced stages of lipedema ($p=0.003$), and in patients with higher body mass index ($p=0.046$).

Patients with earlier stages of lipedema present with less lymphoscintigraphic abnormalities (27.8% in stage I) than patients with advanced stages (80% in stage IV) ($p=0.058$).

Conclusions: Although Stemmer sign and lymphoscintigraphic abnormalities are typically associated to the diagnosis of lymphedema, and have been used traditionally to differentiate both syndromes, they are present also in lipedema patients. So, their absence is not pathognomonic of lipedema.

Diagnosis has still to be made in a clinical basis.

The higher frequency of Stemmer sign and lymphoscintigraphic abnormalities in older patients and in more severe stages of lipedema suggest a lymphatic involvement with time.

THE OCCLUSION PRESSURE OF THE SUPERFICIAL LYMPHATIC NETWORK - A NEAR-INFRARED LYMPHOFLUOROSCOPIC APPROACH IN THE UPPER EXTREMITY OF HEALTHY VOLUNTEERS

BELGRADO J.-P.¹, VANDERMEEREN L.², VANKERCKHOVE S.², VALSAMIS J.-B.¹, MALLOIZEL-DELAUNAY J.³, MORAINÉ J.-J.¹, LIEBENS F.²

¹ Université Libre de Bruxelles - Lymphology Research Unit, Bruxelles, Belgium

² C.H.U. St-Pierre - Lymphology Clinic of Brussels, Belgium

³ University Hospital Rangueil, Dpt. of Vascular Medicine, Toulouse, France

Introduction: Lymphatic network as a part of the cardiovascular system is generally overlooked. Most of filtered fluids reintegrate circulation maintaining the interstitial fluid balance thanks to the lymphatic system. Lymphatic occlusion pressure could be a valuable parameter to characterize the transport capacity of lymphatic vessels. It could complete clinical reasoning in the physiopathology of edema. Former measurement techniques of lymphatic pressure in healthy humans were invasive and complex, leaving knowledge incomplete.

Near-Infrared Fluoroscopy, a minimal invasive imaging technique, allows observing superficial lymphatic flow in real time. Using a transparent sphygmomanometer cuff, we tried to determine the range of normal pressure of the superficial lymphatic vessels.

Methods: Near-infrared fluoroscopy was performed on the upper limb in 32 healthy volunteers. Lymph flow was observed through a transparent cuff, inflated by steps of 10mmHg. Optimized manual lymphatic drainage was executed during experiment to fill the observed lymphatic collectors, making sure they were stocked with lymph. Lymphatic pressure was established when lymph flow stopped.

Results: Superficial lymphatic occlusion pressure range between 80-140 mm Hg, mean 88.75 (SD 14.76). Outcomes do not highlight significant differences between age group, genders and lateralization.

Conclusions: Near infrared fluoroscopy, combined with a transparent sphygmomanometer cuff and optimized manual lymphatic drainage, is an efficient tool to determine the lymphatic occlusion pressure of the superficial lymphatic collectors. This "new" parameter could be integrated into the clinical discussion of impairment of the vascular system and more particularly in the interstitial fluid balance.

Our study pointed out that the occlusion pressure of healthy superficial lymphatic collectors in the upper limb seems to be much higher than previously described.

NEAR-INFRA-RED (NIR) FLUORESCENCE IMAGING OF LYMPHATIC VESSELS AND NODES AFTER SUBCUTANEOUS (SC) INJECTION OF FREE INDOCYANINE GREEN (ICG) IN ONE ANIMAL MODEL: PRELIMINARY RESULTS

PIERRE BOURGEOIS¹, ROMAIN BARBIEUX², SOPHIE VANKERCKHOVE¹, OLIVIER LEDUC²

For the Group R&D Clinical Applications of Fluorescence Imagings

¹ Department of Nuclear Medicine and Clinic-Unit of Lymphology, Institut Jules Bordet, Université Libre de Bruxelles, Belgium

² Lympho-phlebology Unit, Department of occupational and environmental physiology, Haute Ecole P.H. Spaak, Brussels Belgium

Introduction: NIR fluorescence imagings of the lymphatic vessels (LV) and/or of the lymph nodes (LN) after the SC injection of free ICG are now largely proposed to show the Sentinel Lymph Nodes in human patients with various cancers and/or to study the lymphatic system in human patients with edema. However, there are few data in the literature about the kinetics of these fluorescences in the LV and LN. The aim of the presentation is to report the results of the analysis of the fluorescence imagings (in the LN and in the LV) obtained in one animal model from 2 hours up to 7 days after SC injection of free ICG in the hind limbs.

Material and methods: Five groups of 5 mice were injected to be analyzed after 1h, 4h, 24h, 72h and 7 days. In order to perform the injections, mice were anesthetized with ketamine 10% and xylazine 5%. At least 4 mice in each group were sub-cutaneously injected with 50µg ICG in 50µl either in one, or in the two hind limbs. All the mice woke up (except the group analyzed 1h after injection) and moved normally between injections and euthanasia (by CO₂ asphyxia). Using our near-infrared imaging system (PhotoDynamic Eye = PDE – Hamamatsu), imagings were performed at these times: a) of the whole animals in dorsal decubitus when the mice were opened and the axillary and inguinal lymph nodes and the connecting lymphatic inguino axillary vessels were exposed and b) (ex vivo “fresh” and after their embedding in paraffin) of the axillary and inguinal dissected LN and of the (also dissected) skin flap containing the lymph vessel between these LN.

Results: From the simple visual analysis of the animal imagings, the lymphatic transport of the ICG in the LV between the inguinal LN and the axillary LN appeared to be transitory and no more detectable after 24 hours. On the other hand, the semi-quantitative evaluation of the fluorescence in these LN showed that nodal ICG fluorescence peaked during the first 24 hours after injection, plateau-ed between 24 and 72 hours and thereafter decreased with one mean half life estimated to 48 hours. The fluorescence also remained always higher in the inguinal (first-tier) LN than in the axillary (second tier) LN.

Conclusions: Although obtained in one animal model, our results seem in agreement with the scarce informations about what is observed in human patients: one transport of ICG in the LV limited in the time but a long lasting fluorescence in the LN.

June 4, 2015 - Auditoire A. Tissot

WORKSHOP 1 (English)

COMPRESSION IN LYMPHOEDEMA MANAGEMENT

DECISION MAKING IN COMPRESSION THERAPY

PARTSCH H.

Emeritus Professor of Dermatology, Medical University of Vienna, Austria

Compression is the most effective and indispensable measure to reduce lymphedema among the classical components of decongestive lymphatic therapy (DLT).

Important variables deciding the effectivity of compression using bandages and stockings are the exerted pressure and the elastic properties of the material. For intermittent pneumatic compression pumps the sequence and duration of inflating the chambers need to be considered in addition. There is still a lack of comparative clinical studies trying to optimize compression therapy in lymphedema.

Some facts based on experimental clinical work will be outlined:

Stiff, non-yielding bandages applied with sufficient pressure, are the treatment of choice in the initial treatment phase. These bandages stay day and night and work especially in combination with exercises.

Multicomponent bandages exerting a tolerable resting pressure and a high working pressure are preferred.

The application of good inelastic bandages resembles a sculptor's work and should be performed by well-trained staff. The use of pressure measuring probes may be helpful for training courses.

In ISL stage II lymphedema the resting pressure after application should not exceed 30 mmHg on the upper and 50-60 mmHg on the lower extremity. Inelastic material will lead to pressure peaks of up to 100 mmHg during walking corresponding to a "massaging effect".

There is an immediate pressure loss after application due to instant oedema reduction. This has important implications on the timing of bandage renewal.

The use of inelastic Velcro wraps which can be applied and readjusted by the patients are a valuable alternative, especially for self-management.

Maintenance phase of lymphedema treatment starts when no more volume reduction of the oedematous extremity can be achieved. Self-management with compression stockings, preferably using flat knitted made to measure hosiery, or with Velcro wraps are the methods of choice.

Positive patients' experience with compression in the therapy phase is the most convincing way to achieve good concordance with compression hosiery in the maintenance phase.

Intermittent pneumatic pressure pumps should only be used in addition to sustained compression and not as a single method. Hybrid systems combining sustained and intermittent compression could become an interesting alternative.

COMPRESSION GARMENT: CUSTOM VS OVER-THE-COUNTER

LESSERT C.

Division of Angiology, Lausanne University Hospital, CHUV, Switzerland

The most important characteristics of medical elastic compression stockings (MECS) are elasticity, hysteresis, and stiffness.

Each type of MECS has its own characteristics depending on material, type of knit (flat-knitted or round-knitted), and knitting method.

One should be familiar with all available garments in order to choose the right one for the right patient.

All garments are available either as ready-made or custom-made. A good balance between comfort and effectiveness makes MECS acceptable for patients.

In the future, we hope to obtain an international consensus for MECS labeling concerning pressure and stiffness.

PRESCRIBING AND FITTING GARMENTS FOR CHILDREN

VOLLMER A.

Germany

June 4, 2015 - Auditoire A. Yersin

WORKSHOP 1 (French)

ICG_FLUOROSCOPIE: ASPECTS PRATIQUES

ICG_FLUOROSCOPIE: ASPECTS PRATIQUES

BELGRADO J.-P.

Belgium

June 4, 2015 - Auditoire A. Tissot

WORKSHOP 2 (English)

HOW TO MEASURE LYMPHOEDEMA TREATMENT OUTCOME?

VOLUME ASSESSMENT

WAGNER S.
Switzerland

MEASURING TREATMENT OUTCOME AND FOLLOW-UP. HOW WE DO IT!

HÅKAN BRORSON¹, MD, PhD, KARIN OHLIN OT², BARBRO SVENSSON, PT, LT²

¹ Associate Professor (Lund University), Professor (EGAMA, Buenos Aires), Senior Consultant Plastic Surgeon Email: hakan.brorson@med.lu.se

² Lymphedema Center, Department of Clinical Sciences, Lund University, Plastic and Reconstructive Surgery, Skåne University Hospital, Malmö, Sweden

Introduction: Outcomes of lymphedema treatment very seldom present results as excess volume or excess volume reduction. Instead circumference measurements, taken at random sites along the extremity, are used making it very difficult to estimate the true outcome as well as to compare various studies. Also continuous follow-up of treatment outcome is important.

Material and Methods: Volume measurement, either using plethysmography or based on circumference measurements, is an easy and quick method to objectively assess treatment outcome and to increase the scientific impact when presenting results.

The most reliable way to measure the volume of an extremity is plethysmography according to Archimedes' principle, i.e., the limb is immersed in a volume meter and the drained water is weighed. The weight in grams equals the volume in milliliter and also includes the hand and foot volume. For both the arm and leg volume meter it is important that the draining pipe is placed high enough so that the entire limb can be measured. The diameter of the draining hose should be large so that the water can flow quickly. It is important that the limb is immersed into the volume meter at exactly the same depth each time.

Another method is circumference measurements on well-defined distances along the limb. The volume is calculated by the use of different formulas. Circumference measurements also provide information of the localization of the swelling. Hand and foot volumes cannot be calculated.

In order to follow the outcome of treatment Excel sheets have been constructed for easy use and data are directly linked to figures showing outcome.

Conclusion: To only make single circumference measurements (for example the middle of the upper arm, elbow, middle of the forearm) is not adequate either for clinical use or scientific study. Both plethysmography and circumference measurements are useful and show satisfactory validity and reliability. Plethysmography is recommended if only one method is used. Volume measurement of both extremities must be performed at the same time in order to get a reliable measure of the excess volume, which is the most important factor when evaluating outcome after any treatment. Long-term follow-up is made easy by the use of Excel sheets linked to figures.

TISSUE DIELECTRIC MEASUREMENT

LAHTINEN T.
Finland

June 4, 2015 - Auditoire A. Yersin

WORKSHOP 2 (French)

COMMENT MESURER L'EFFICACITÉ DU TRAITEMENT PAR PHYSIOTHÉRAPIE?

MESURES VOLUMÉTRIQUES. Comment évaluer les changements de volume avant et après traitement par physiothérapie

SCHUCHHARDT C.
Freiburg, Allemagne

Le développement des standards de qualité de thérapie et des directives basées sur l'évidence concernant la thérapie décongestionnante complexe du lymphoedème demande un principe volumétrique internationalement accepté. Des différentes manières d'objectivation du volume des extrémités sont utilisées: Circonférence en cm par décimètre à ruban, plétysmographie et le mesurage optométrique par rayons infrarouges (péromètre, legreader ou similaires). Les différents avantages ou sources de défauts seront discutés. Il faut se rendre compte, que toutes les différentes techniques de volumétrie ne permettent pas le dépistage précoce d'un lymphoedème, c'est à dire la phase où une imbibition tissulaire ou une fibrose a commencé, mais pas encore une augmentation de volume.

QUALITÉ DE VIE

FORNER-CORDERO I.
Spain

MESURE DE PRESSION SOUS BANDAGE

TOMSON D.

June 5, 2015 - Auditoire A. Yersin

WORKSHOP 3 *(French)***LA COMPRESSION DANS LE TRAITEMENT DU LYMPHOEDÈME****BAS SUR MESURE VS STANDARD**

LESSERT C.
Switzerland

COMMENT MESURER ET CONFECTIONNER DES BAS POUR LES ENFANTS?

VOLLMER A.
Germany

June 5, 2015 - Auditoire A. Tissot

WORKSHOP 4 *(English)***PATIENT SELF-CARE****TEACHING SELF-CARE**

FOELDI M.
Germany

WHICH PHYSICAL ACTIVITY FOR LYMPHOEDEMA PATIENTS?

SNEDDON M.
United Kingdom

WHICH PHYSICAL ACTIVITY FOLLOWING ARM LYMPHOEDEMA?

JOHANSSON K.
Sweden

June 5, 2015 - Auditoire A. Yersin

WORKSHOP 4 *(French)*

AUTOGESTION DU LYMPHOEDÈME ET ÉDUCATION DU PATIENT

EDUCATION THÉRAPEUTIQUE

VIGNES S.

France

QUELLE ACTIVITÉ PHYSIQUE?

WAGNER S.

Switzerland

L'AUTOBANDAGE

LUTHI I.

Switzerland

This image shows a single sheet of white paper with horizontal ruling lines. The lines are evenly spaced and run across the width of the page. There are no margins, text, or other markings on the paper.

NOTES

This image shows a single page of white paper with horizontal grey ruling lines. The lines are evenly spaced and run across the width of the page, leaving small gaps between them. There are no margins, text, or other markings on the paper.

This image shows a single sheet of white paper with horizontal ruling lines. The lines are evenly spaced and run across the width of the page. There are no margins, text, or other markings on the paper.

Compression stockings straight to the right solution

*VARISAN[®] Top
Fashion*

*VARISAN[®]
Lui & Lei*

VARISAN[®]

VARISAN[®] TOP

VARISAN[®] guanto

VARISAN[®] soft

VARISAN[®] A.T.E

VARISAN[®] bracciale

VIVA[®]

VARISPORT[®]

