OFFICIAL ORGAN
OF THE


EUROPEAN GROUP
OF LYMPHOLOGY
GROUPEMENT EUROPÉEN
DE LYMPHOLOGIE
LATINO-MEDITERRANEAN
CHAPTER OF LYMPHOLOGY

# THE EUROPEAN JOURNAL OF lymphology and related problems

VOLUME 5 • No. 17-18 • 1995

INDEXED IN *EXCERPTA MEDICA*.

## SUMMARY

**PAPERS PRESENTED DURING THE 1st MEETING
OF THE EUROPEAN FEDERATION OF MICROSURGICAL SOCIETIES
( President : G. BRUNELLI - Brescia - Italy )
Rome - Italy - September 26, 1992**



**PAPERS PRESENTED AT THE XVIIIth MEETING
OF THE EUROPEAN GROUP OF LYMPHOLOGY (G.E.L.)
Brussels, 6 - 7 may 1994**



**CALENDAR :**

XVth International Congress of Lymphology
25th, 26th September 1995 - Recife
27th, 28th, 29th, 30th September 1995 - Sao Paulo - Brasil

THE EUROPEAN JOURNAL
OF
lymphology
and related problems
VOLUME 5 • Nr. 17-18 • 1995

# 1st MEETING OF THE EUROPEAN FEDERATION OF MICROSURGICAL SOCIETIES

*President :*

G. BRUNELLI

Brescia - Italy

ROME, ITALY, EXCELSIOR HOTEL (via Veneto)

SEPTEMBER 26, 1992

SATELLITE MEETING :

## RECONSTRUCTIVE MICROSURGERY IN LYMPHATIC SURGERY

*Chairman :*

C. CAMPISI

Genoa - Italy

THE EUROPEAN JOURNAL
OF
lymphology
and related problems
VOLUME 5 • Nr. 17-18 • 1995

INTRODUCTORY LECTURE

# Reconstructive lymphatic microsurgery : state of art

C. CAMPISI

V.-President of the European Group of Lymphology
(GEL)
V.-President and Secretary General of the Italian Society of Lymphangiology
Secretary General of the Latin-Mediterranean Chapter of the International Society of Lymphology
(I.S.L.)
Associate Professor of Emergency Surgery and Microsurgery
University of Genoa, Italy

The Symposium is under the patronage of the Italian Society of Lymphangiology and the auspices of the Latin-Mediterranean Chapter of the International Society of Lymphology and the European Group of Lymphology, here represented by the high personalities belonging to the Executive Committees, auch as my Teacher, Prof. Mario CASACCIA, President of the Italian Society of Lymphangiology, Prof. J.A. COSSIO, President both of the Latin-Mediterranean Chapter of the ISL and the Spanish Group of Lymphology as well, and Prof. A. PISSAS, President of the European Group of Lymphology.

Our Meeting gathers a lot of heads of School of Italian Surgery, who accepted with pleasure to belong to the Honorary Committee and to be today present, such as Prof. S. ARMENIO from Siena, Prof. A. DI MATTEO from Rome, Prof. I. DONINI from Ferrara, Prof. S. NAVARRA from Messina, Prof. C. PRIOR from Genoa, Prof. RODOLICO from Catania, without forgetting Prof. M. BARTOLO from Rome and Prof. D. ZACCHEO, as Italian authorities and members of the Executive Committee of the Italian Society of Lymphangiology, and Prof. W. OLSZEWSKI, Past President of the ISL, from Warsaw, Prof. M. FOLDI, Director of Foldi Klinik für Lymphologie, from Hinterzarten-Freiburg, Germany, Prof. E.A. SAMANIEGO, President of the Spanish Society of Phlebology, from San Sebastian, as foreign authorities in this field, apart of all other Colleagues coming from the various parts (Countries) of Europe, to give here their precious contribute.

The subject-matter of this Symposium awakes our interest because it is a new and present one, rich of good prospects.

Nevertheless it is necessary to put this subject in order, beginning to fix both the anatomical bases, that Prof. CASTENHOLZ is going to explain, and the physiopathological ones as well, whose undiscussed teacher is Prof. OLSZEWSKI.

Then, Prof. J.A. COSSIO will deal with the clinical patterns of Lymphedema, susceptible of microsurgical treatment.

A particular space of this microsurgical and lymphological morning will be dedicated to the diagnosis, beginning with our School's experience on direct lymphography, with the following reports, on the behalf of a great expert of lymphological radiology, such as Prtof. J. BRUNA, from Praha, with a precise reference to the peculiarities of lymphography in paediatric age according to our experience as well. Which role has today the direct lymphography in the diagnostics of lymphedema ?

Well, these experts are going to explain us their opinion also to compare it with the criticisms that in these last years regarded this kind of diagnostic investigation.

Nevertheless, the lymphoscintigraphy has improved a lot and nowadays we consider it as one of the indispensable method of depistage and diagnostic information as well.

Prof. P. BOURGEOIS and Prof. E.A. SAMANIEGO are going to speak about it, trying to point out how the standardization of this method stand to succeed in obtaining an easier and more effective use of homogeneous data interpretation.

Then, we will deal with the specific reports on microsurgical field in Europe, referring to derivative lympho-venous microsurgery, which will be point out by Prof. G. INGIANNI, E. SAMANIEGO and KAUFMAN.

We will speak also aboiut our advance that belongs to the Genoese School, that's to say the Laser-Microsurgery coupling.

What are the advantages we can have ?

In which cases ?

In the second part of the morning, prof. R. BAUMEISTER, P. TREVIDIC, C. BECKER and we will examine the specific microsurgical reconstructive techniques.

A discussion will follow to compare the different experiences (figs. 1 - 2).

Which kind of reconstruction we can make ?

Autogenous lymph vessel transplantation, autogenous vein transplantation or free lymphatic flaps ?

What are the indications ?

Then, the medical and physical conservative treatment as alternative, that's to say in antithesis to microsurgery or better together to obtain improved and more lasting results, apart from the advantage of the much more rapidity to obtain a good and definitive result. What can derive from this association ?

As far as it is concerned we are going to listening to Prof. A. PISSAS, J.P. BRUN, A. LEDUC and R. CLUZAN's opinions.

Then, other methods such as thermotherapy can have an interesting role in the ambit of conservative treatment of lymphedema associated or not to the microsurgery.

On these subjects you can evaluate the experience we achieved so far.

---

THE EUROPEAN JOURNAL
OF
lymphology
and related problems
VOLUME 5 • Nr. 17-18 • 1995

# Bases anatomiques de la microchirurgie réparatrice du système lymphatique (*).

# Anatomical aspects for reconstructive microsurgery in lymphatic surgery (*).

A. CASTENHOLZ

*University of Kassel*
*Department of Human Biology.*

## INTRODUCTION

La lymphologie clinique est un domaine à multiples facettes comprenant de nombreuses méthodes de diagnostic et de traitement conservateur, ainsi que des techniques chirurgicales ou microchirurgicales. Signe d'alarme du dysfonctionnement du système lymphatique, l'œdème traduit la défaillance totale ou partielle du drainage tissulaire, normalement protégé par de nombreux volants de sécurité. Les connaissances récemment acquises en lymphologie fondamentale ont éclairé la physiopathologie des différents types d'œdèmes secondaires à une défaillance soit fonctionnelle, soit mécanique du système (1).

Pour préjuger de la réussite ou de l'échec du traitement clinique du lymphœdème, il est essentiel de connaître à la fois les bases structurelles du système, la dynamique du courant lymphatique et les processus histophysiologiques qui y participent. C'est pourquoi nous envisageons ici la micro-anatomie, les relations avec les tissus environnants et les propriétés circulatoires des vaisseaux lymphatiques des plus petits aux plus importants. Nous exposerons essentiellement les résultats expérimentaux recueillis au moyen de la microscopie électronique, de la microscopie *in vivo* et l'injection de nouveaux produits fluorescents chez le rat. La description détaillée de ces techniques a été rapportée antérieurement (2, 3, 4, 5, 6).

*Reprints request to :*
*Prof. Dr. med. A. CASTENHOLZ*
*University of Kassel*
*Department of Human Biology*
*Heinrich Plett Str. 40*
*D-3500 Kassel*
*Fed. Rep. of Germany*

(*) Travail réalisé grâce à une subvention de la Société Allemande de Recherche (DFG) et de la Société Allemande de Lymphologie (DGL).

This paper was supported by grant of the German Research Society (DFG) and the German Society of Lymphology (DGL).

## INTRODUCTION

The spectrum of topics essential for clinic lymphology comprises various methods of diagnosis as well as physical treatment and surgical or microsurgical operations. As a guide symptom of lymphatic dysfunction, the edema indicates a state in which tissue drainage mechanisms, normally well balanced by control of many safety factors, are overcharged and, at least, become insufficient. Today, considering new findings in basic lymphology, insights have been obtained even in the pathophysiology of different types of edema caused either by a dynamic or mechanical insufficiency (1).

To assess precisely success or failure of clinical application in edema treatment fundamental knowledge of both the structural organization as well as the dynamics of lymph flow and the histomechanics concerned seems to be of great importance. Thus, the fine structural features, the relations to the surrounding tissue, and the rheological properties of fine and larger lymphatics should be outlined here. Predominantly results of experimental studies based on electron microscopy as well as vital microscopy and new fluorescence techniques applied in rate will be reported. Further details of the studies have been published in previous papers (2, 3, 4, 5, 6).

## MORPHOLOGICAL FEATURES OF THE LYMPHATICS

The vascular lymphatic system is composed of vessels provided with different dimensions, morphological properties and functions. Thin-walled vessels are the initial lymphatics and precollectors, which only consist of an endothelium and a small basal lamina, whereas the collecting vessels as draining channels of organs and regions of the body represent thick-walled structures with three well-developed layers similar to that of blood veins.

In the skin and mucous membranes the initial lymphatics and precollectors form plexus-like systems. Their diameters strongly vary from a few micrometers up to 100 $\mu$m and more. The system of collectors is organized after the principle of converging ducts in the body. Lymph nodes serve as stations in

En ce qui concerne le système lymphatique initial, nous n'avons encore que peu de connaissances sur les mécanismes de formation et de circulation de la lymphe. Cependant, des études microscopiques *in vivo* ont permis récemment de mieux appréhender la dynamique des échanges liquidiens à ce niveau. Dans des conditions expérimentales bien définies et en utilisant de nouveaux produits fluorescents tels que le FITC dextran et des microcapsules fluorescentes, on a pu observer directement la formation et le cheminement de la lymphe néoformée dans les lymphatiques initiaux et dans les précollecteurs (9, 6, 11, 12). Le résultat de ces expériences peut être résumé ainsi qu'il suit :

1. Dans des conditions normales, les lymphatiques initiaux étant collabés, leur remplissage à partir du liquide interstitiel se fait par une lente filtration à travers les fins espaces interendothéliaux *(open junctions)*, seuls dispositifs expliquant la perméabilité de ces vaisseaux.
2. Lorsque augmente le volume liquidien intratissulaire, les orifices intercellulaires deviennent plus perméables et le liquide fait massivement irruption dans le lymphatique initial. Ce phénomène qui augmente drastiquement la quantité de lymphe formée dépend de la structure histologique des vaisseaux qui se dilatent par traction des filaments d'ancrage *(anchoring filaments)*. D'autres larges communications entre espace interstitiel et lumière vasculaire ont été mises en évidence dans le mésentère et dans d'autres tissus (13). Ce dispositif favorise l'écoulement du liquide interstitiel vers la lumière vasculaire.
3. La progression de la lymphe néoformée dans le lymphatique initial et les précollecteurs dépend de la vitesse de sa formation, à bas ou à haut régime. Dans de nombreuses expériences, on peut constater un écoulement rythmé. Ce rythme est souvent fonction des mouvements respiratoires de l'animal, mais, parfois, manifestement influencé par le mécanisme de succion exercé en aval par les collecteurs.
4. Un autre phénomène important est le fait que la lymphe néoformée, dès son passage dans les premiers vaisseaux, y est débarrassée des particules étrangères qu'elle renferme. Ainsi, des corpuscules en suspension sont captés par l'endothélium, adhérant aux irrégularités de la face endoluminale de ces vaisseaux, et restent de ce fait plus ou moins longtemps écartés du courant lymphatique. La plupart de ces éléments est finalement phagocytée par les cellules endothéliales. Ce qui conduit à penser que les lymphatiques initiaux sont doués de propriétés immunologiques, jusqu'à présent reconnues seulement aux nœuds lymphatiques et aux autres constituants du système de défense de l'organisme.

## EN CONCLUSION

Cet exposé ne concerne que l'anatomie générale des vaisseaux lymphatiques. Nous avons insisté sur la structure microscopique de ces conduits et leur aspect fonctionnel. Nous ne nous sommes pas proposé de décrire l'anatomie descriptive et topographique des lymphatiques des différentes parties du corps. (Pour de plus amples renseignements sur ce chapitre particulier de l'angéiologie lymphatique, voir 13).

A l'adresse des cliniciens microchirurgiens, il nous faut insister pour conclure sur un certain nombre de points. Le système lymphatique en général, haut lieu de confrontations immunologiques entre cellules isolées et tissus, représente un dispositif fondamental dans lequel toutes les structures vasculaires, vaisseaux sanguins comme lymphatiques, jouent un rôle de premier plan. Les techniques expérimentales modernes ont montré que les lymphatiques, des plus fins aux plus gros, sont des structures bien différenciées, omniprésentes à la fois dans les organes lymphoïdes et dans les autres tissus. Ainsi, le processus vital de formation de lymphe à partir de l'ensemble du milieu interstitiel ne peut-il se réaliser que grâce à un équilibre harmonieux entre

caused by the fact, that on the base of histomechanics, the vessels dilate by the stretching of the anchoring fibers. In mesentery and other tissue even broad preformed interconnections between the interstitial spaces and the vascular lumen have been evidenced (13). In such a case easy drainage of the tissue is possible by the vessels concerned.

3) The primary lymph is moved within the initial lymphatic and precollectors depending on the existing mode of lymph formation either at low or fast speed. In many experimental studies, rhythmic movement of the lymph could be recognized. The rhythm is often correlated with the breathing action of the animal and sometimes, obviously influenced by sucking forces, produced by the subsequent collector system.
4) As an important phenomenon it could be recognized that the primary lymph, while passing the lumen of the first vessels, is already cleared from foreign material. Thus, particulate matter is captured by the endothelium adhering at the irregular luminal profile of these vessels and so removed from the lymph for a short or longer time period. Most of that material is finally ingested by phagocytosis of the endothelial cells. The observation lets suggest that the initial lymphatics are already provided with significant immunobiological properties, which, hitherto, have been only ascribed to lymph nodes and other parts of the body defence system.

## FINAL REMARKS

This report concerns the anatomical basis of the lymphatic vessels. Thus, emphasis was laid on the fine structural features of these structures and on the functional aspect as well. No attempt was made to give a precise description of the topography and systemic anatomy of the lymphatics in different regions of the human body. (For further instructions of that particular field of lymph angiology, see 13).

For clinicians working in the field of microsurgery, some general concluding remarks should be pointed out here. The lymphatic system as a site of abundant immunobiological encounter between single cells and tissue exhibite a base on which all vascular structures, blood vessels as well as lymphatics, take an outstanding role. Modern techniques in experimental morphology have shown that fine and bigger lymphatics are well differentiated structures which form integrated elements within lymphoid organs and other tissue. Thus, a vital process like lymph formation happening everywhere in the connective tissue is only possible, if vascular functions and histomechanics interact in a well-balanced manner. On the other hand, precontrol of the primary lymph by the endothelium of initial lymphatics as evidenced by vital microscopy proves another significant immunobiological mechanisms, which is wellknown phenomenon of the living cells of sinuses in lymph nodes. Moreover, it has been demonstrated by rheological observations in experimental animals that there exists a close rheological interrelationship between the initial lymphatic system and the lymph collectors on the base of sucking forces, which, together with histodynamics, promote the primary lymph. Keeping these facts in mind the surgeon has to realize that every interference in the system of lymphatics either produced by operative or diagnostic procedures may affect not only a single structure or a limited tissue area, but, as a rule, also most remote parts of the lymphatic system in the body.

THE EUROPEAN JOURNAL
OF
lymphology
and related problems
VOLUME 5 • Nr 17-18 • 1995

# Lympho-venous-microsurgical anastomosis in the treatment of lymphedematous limbs.

G. INGIANNI
*Clinic for Plastic and Hand-Surgery*
*Director :* Priv. Doz. Dr. med. habil. G. Ingianni
*Ferdinand-Sauerbruch-Klinikum / Wuppertal*
*T. hosp. University of Düsseldorf.*

## SUMMARY

Microsurgical procedures in reducing lymphedema of the limbs may improve the patients condition but it is still a current unsolved problem. There are differences made in considering primary and secondary lymphedema, the upper and lower extremity and patient-history.

The clinical manifestation of lymphedema is partially reversible, being only able to improve and not heal the condition. The various microsurgical techniques show reasonable results yet their evaluation is not comparable.

According to our experience with 52 patients and a maximum follow up of ten years we concluded that :

1. Lympho-venous anastomosis were not effective in patients having a lower limb lymphedema.
2. Lympho-venous-anastomosis were not possible in patients with a primary lymphedema.
3. The natural progredience in secondary lymphedema of the upper limb can be decreased but not stopped.
4. A selection of suitable patients is mandatory to avoid bad results.

However microsurgical lympho-venous-anastomosis plays an important part in the therapy of secondary upper limb lymphedema and should be seen as a routine procedure in big microsurgical units.

## INTRODUCTION

The resective therapy of the lymphedema is limited to a few particularly cases (fig. 1). A microvascular lympho-venous-anastomosis as well as lympho-lymphatic transplantations or venous grafts represent a more physiological way of treatment. Microlymphatic surgery exists now for 25 years and yet all of the problems are not solved in treating the lymphedematous limbs despite of many optimistic articles.

There are many different reasons for this : being related to the pathology of the lymphedema itself, to the localisation and to the different patients.

For example, there are basic differences in primary and secondary lymphedema. In primary lymphedema, lymphcollectors are hypoplastic or non functioning leading to a breakdown of the centripetal lymph flow. In these cases lymphovenous or lympho-lymphatic connections cannot give satisfying results.

Due to the localisation there are also different hemo- and lymphodynamic conditions which can eventually harm the lympho-venous or lympho-lymphatic anastomosis.

The third factor, the patient itself is of outmost importance. The history of the lymphedema, the irreversibility of the interstitial changes like fibrosis and the chronic subacute infection of the lymphatic system advise us to carefully select adequate patients for the microlymphatic procedures.

Independantly from the kind of microlymphatic procedures two requirements have to be fullfilled :

1. Enhancing the natural but actually reduced lymphatic output and
2. bypass the lymphatic stop at the root of the extremity.

## METHODS

We only want to briefly discuss our microsurgical technique for performing the lympho-venous-anastomosis because it has already been discussed elsewhere (fig. 2, 3). The elementary conditions for performing this operation are :

1. suitable lymphcollectors in the involved extremity ;
2. no tissue fibrosis ;
3. no infection.

The pre- and postoperative circumference measurements are taken from differing levels on both extremities (fig. 4). Ten years ago with our first cases we calculated the volume by water displacement (fig. 5). To quantify the postoperative results isotopical investigations of the lymphatic clearance were used.

We stopped using this method because most of our patients were extremely bored by the procedures and refused it.

The simple measurements of the circumference are less precise yet deliver enough information for evaluation and are easier on both the patients and the surgeons.

*FIGURE 1*
*Elephantiasis of the left leg :*
*The young patient is virtually enable to walk.*
*No microsurgical procedure can be helpful.*
*Only a resective therapy can be performed.*

*FIGURE 2*
*Invagination anastomosis between a larger vein and a lymphvessel.*

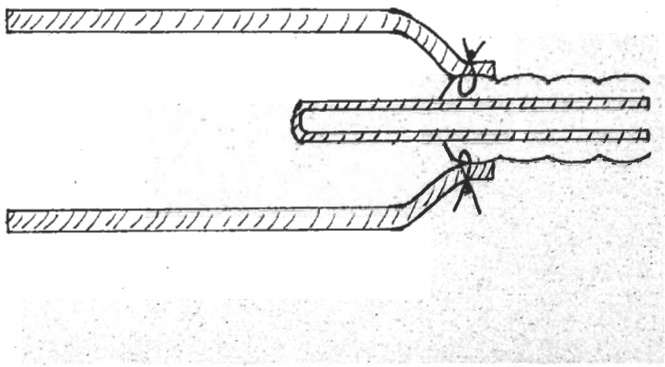

*FIGURE 3*
*Three month after the operation histological finding of a lymphovenous anastomosis.*
*The endothelial sheet is complete without any step.*

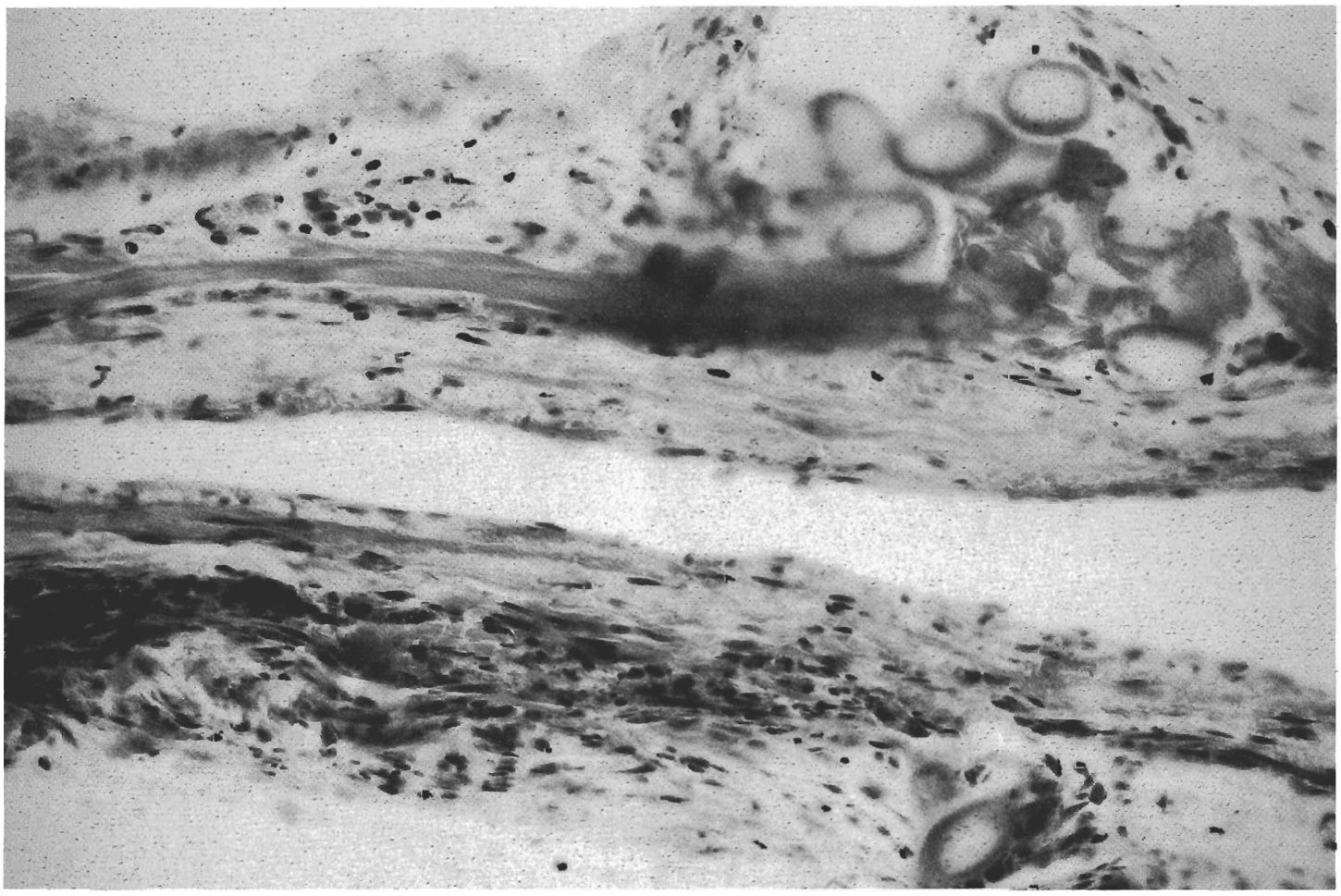

THE EUROPEAN JOURNAL
OF
lymphology
and related problems
VOLUME 5 • Nr 17-18 • 1995

# Lymphatic laser-microsurgery : experimental research and original clinical applications.

C. CAMPISI, M. CASACCIA Jr., E. MERETO, F. BOCCARDO,
P. PADULA, M. TACCHELLA

*University of Genoa*
*Department of Emergency Surgery*
*Microsurgery Center*
*Italy*

## SUMMARY

The authors report their experimental studies and clinical observations regarding the use of CO2 laser in lymphatic microsurgery.

The effects and advantages brought about by CO2 laser in their experimental studies on rats in performing lymphatic microanastomoses are particularly pointed out.

8 clinical observations of lympho-chyledema of lower limbs and genitalia, associated to chylous ascitis, are reported. Clinical outcome proved the remarkable advantages obtained by using laser ray welding power to cut and close insufficient and dilated lymphatic and chylous collectors.

In over 3 year clinical follow-up no relapse of the pathology occurred in any patient.

## INTRODUCTION

According to its different actions, CO2 laser can be used in surgery for cut, coagulation, carbonization, vaporization and welding.

Laser ray, used at low powers, carries out haemostasis of blood vessels, till 1 mm. in caliber, and seals lymphatic collectors, without determining any serious tissural damage.

The reason of this action lies in denaturation of proteins and architectural disorganization of tissues due to hyperthermia, due to a low power energy used on small surfaces. Some biochemical modifications occur as well : increase of protein synthesis, modulation of enzymatic activities, intra- and extracell pH variation, stimulation of mitochondrial activity with ATP increase.

These particular effects of laser ray proved very interesting and useful in lymphangiology, particularly if associated with microsurgical techniques.

## MATERIALS AND METHODS

Recent experimental studies of us on rats aimed at using CO2 laser welding effect for lymphatic microanastomoses, without putting any stitch, thus avoiding possible endothelial damage (Fig. 1).

" *Laser-made* " lymphatic anastomoses would find suitable clinical applications above all to prevent post-mastectomy and post-lymphadenectomy lymphedemas, especially in cases undergoing radiotherapy, and also to treat chronic lymphedemas of extremities. Further experimental verifications will maybe allow to use " *laser-made* " lymphatic microanastomoses for clinical observations.

Our clinical experience in using CO2 laser consist in managing lympho-chyledema of lower limbs and genitalia, due to gravitational back-flow, and chylous ascitis. We carried out " antigravitational ligatures " of insufficient and dilated lymphatic and chylous collectors, using CO2 laser ray welding power to cut and close vessels (Fig. 2).

Post-operative course was particularly favourable in all of the cases, proving the remarkable advantages deriving from the use of laser.

Out of 8 observations of lympho-chyledema of lower limbs and genitalia, associated to chylous ascitis, in 3 patients it was necessary to performed also the reductive plasty of genitalia (Fig. 3, a-b).

Microsurgical lymphatic angioplastic operations, moreover, were carried out at the groin, using derivative techniques either using lymph nodes or directly lymphatic collectors.

No relapse of the disease was observed at over 3 years from operation by now.

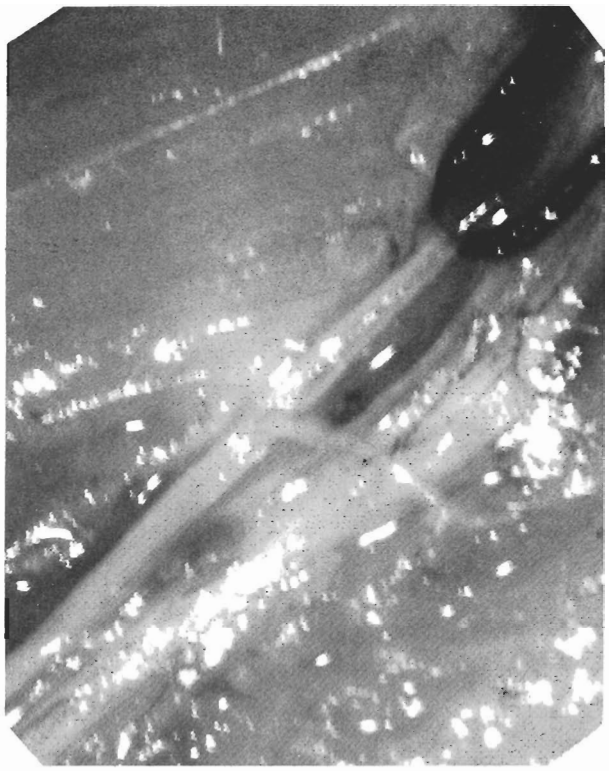

*FIGURE 1*

*" Laser-made " lymphatic-venous anastomosis on rat : note laser red guide-ray at the site of anastomosis.*

*FIGURE 2*

*" CO2 Laser-made " section-closure of a dilated lymphatic collector.*

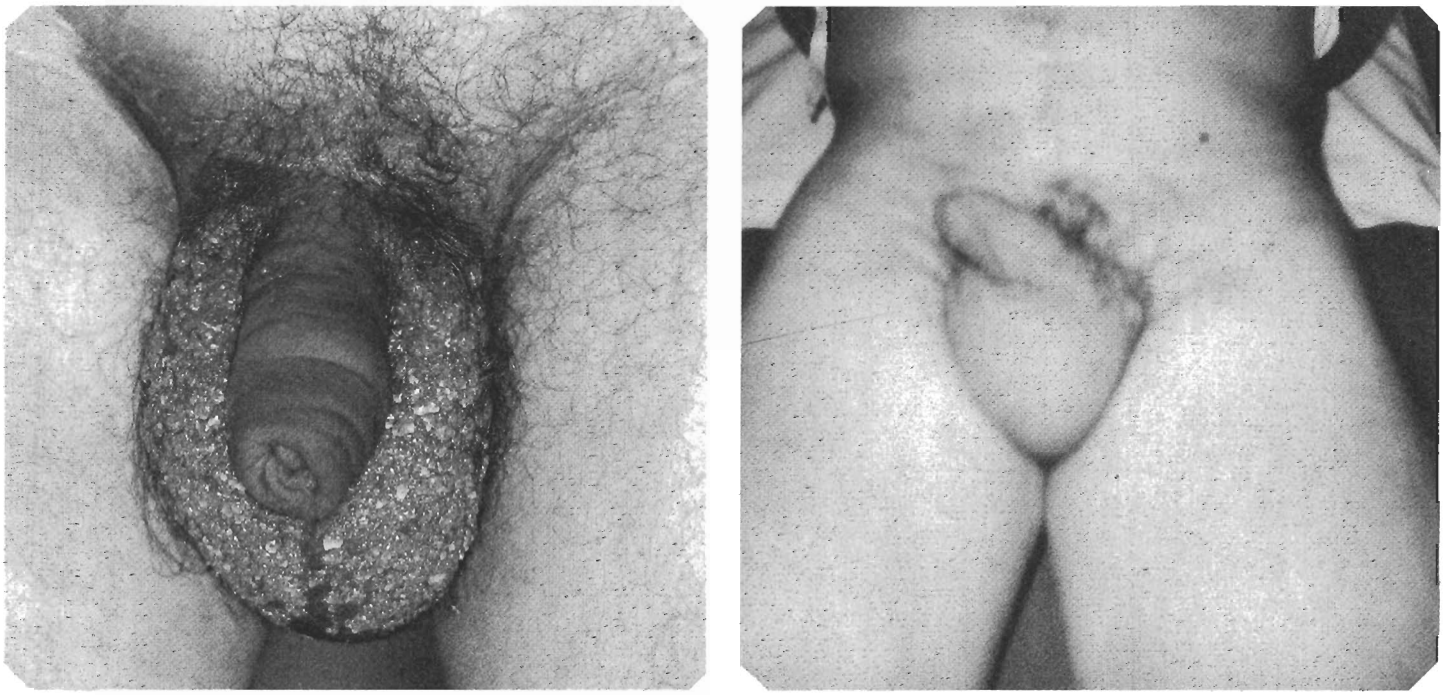

*FIGURE 3, a - b*

*Clinical observation of a lympho-chyledema of lower limbs and genitalia treated by laser antigravitational lymphatic closures, bilateral lympho-venous shunts at the groin and reductive plasty of genitalia, before a) and after b) 3 years from operation. Of note, lymphostatic verrucosis of the scrotum was treated by CO2 laser as well.*

THE EUROPEAN JOURNAL
OF
lymphology
and related problems
VOLUME 5 • Nr 17-18 • 1995

# Autogenous lymphvessel transplantation.

R.G.H. BAUMEISTER, A. FRICK

*Division of Micro-, Hand-, Reconstructive Surgery (Head : Prof Dr. R.G.H. Baumeister)*
*Department of Surgery (Director : Prof. Dr. F.W. Schildberg),*
*Klinikum Großhadern, University of Munich.*

The interposition of autogenous lymphatic grafts is the most natural way to reconstruct the lymphatic channels which are destructed within a limited area. In Europe, the postmastectomy oedema with lymphnode removal in the axilla is the most important example of the type of lymphatic destruction.

Lymphoedemas due to lymphnode removals at other localisations, e.g. the groin, – mostly combined with radiotherapy –, and lymphoedemas after trauma, – mostly with additional local infections –, are also caused by locally destructed lymphatic channels. In rare cases of primary lymphoedemas, these are caused by a local atresia of lymphatics and are therefore also suited for a direct reconstruction by autogenous lymphatic transplantation.

The use of other material than autogenous lymphatic vessels for reconstructive purposes, such as autogenous veins, allogenic lymphatics and PTFE prosthesis have been proved in experimental studies.

But none of these materials could reach the excellent results of autogenous lymphatic transplantations. Some of these are of no value.

In the following, a short description of the method and the last results will be given followed by a more detailed discussions on the use of different materials for lymphatic reconstruction.

## MATERIAL AND METHODS

From June 1980, the first lymphatic transplantation in man, through December 1991, 111 patients were treated by autogenous lymphvessel transplantation.

68 patients suffered from armoedemas. Out of these, 63 were femals and 5 man. 67 patients suffered from secondary and 1 of primary lymphoedema.

43 patients showed unilateral oedemas of the lower extremities. Out of these, 29 were men and 14 femals. 30 patients suffered from a secondary and 13 of a primary lymphoedema.

All patients were treated by conservative means for at least half a year prior to the microsurgical intervention. Also they were checked for a possible recurrency in the case of a history of a malignant desease and rejected in such a circumstance.

Also patients were excluded with extensive remnants of radiations such as ulcerations and also patients with a high anaesthetical risk.

For evaluation of the results the affected and the contralateral extremity were measured with respect of the circumferences. The volumes were calculated by a computerprogram according to KUHNKE (5). In the affected extremities and also at the donor side, lymphatic scintiscans were performed to estimate the lack of lymphatic outflow at the oedematous limbs and to ensure a normal lymphflow at the donor side.

Technetium precolloid was used for these purposes.

The scintigraphies were checked with respect to the lymphatic transporting kinetics (K), the distribution of the radiopharmacon (D), the time to the appearance of the lymphnodes (T), the appearance of the lymphnodes (N) and the appearance of the lymphvessels (V).

Out of these dates, a lymphatic transport-index was calculated by the formula

$$TI = K \times D \times 0{,}04 \times T \times N \times V.$$

In some cases, especially in primary cases, an additional indirect lymphography using Isovist ® was used to get some more informations about the peripheral lymphatic channels and the lymphatic influx into the main collectors.

The lymphatic grafts are harvested from the inner aspect of the thigh in between the groin and the knee-region with a length up to 30 cm. Mostly 2 to 3 collectors are taken out of the about 16 collectors which are available at the ventro-medial bundle (KUBIK, 4).

In the case of an armoedema ascending lymphatics are identified in the epifascial and often also in the deep compartment at the upper arm and also descending lymphatics at the neck next to the internal jugular vein.

The grafts are pulled through a plastic tube which is inserted in between the two incisions. After removal of this tube, the grafts run in the subcutaneous tissue ventral to the shoulder. Under the microscope using a 40 fold magnification, the lymphatics are anastomosed – end to end – using the socalled tension free anastomosing technique with absorbable suture material size 10-0 and 11-0.

After 6 months, he found all lymphatic autogenous graft patent, however all of the venous grafts were occluded.

Therefore together with the argument of the necessity of big calibers in the case of long venous segments, we suggest that lymphatic grafts are the material of choice for bridging lymphatic gaps.

## REFERENCES


1. BAUMEISTER R.G.H., A. FRICK, T. HOFMANN, K. TATSCH — 10 years of experience with autogenous microsurgical lymphvessel-transplantation. *European Journal of Lymphology*, 2, 6 (1961), p. 62.

2. DANESE C., R. BOWER, J. HOWARD — Experimental Anastomoses of Lymphatics. *Arch. Surg.*, 84, 24 (1962).

3. KLEINHANS E., R.G.H. BAUMEISTER, D. HAHN, S. SIUDA, U. BÜLL, E. MOSER — Evaluation of transport kinetics in lymphoscintigraphy. Follow-up studies in patients with transplanted lymphatic vessels. *European Journal Nucl. Med.*, 10, 349-352 (1985).

4. KUBIK S., M. MANESTAR — Zusammenhänge zwischen Lymphgefäßzahl und kompensiertem Lymphabfluß im Hinblick auf die autologe Lymphgefäßtransplantation. *In : Lymphologica,* Jahresband 1990, Hrsg. R.G.H. BAUMEISTER, *Medikon Verlag*, Münchan, 1990.

5. E. KUNHKE — Volumenbestimmungen aus Umfangsmessungen. *Folia Angiol.*, 24, 228-232 (1976).

6) SAUMWEBER D.M., R.G.H. BAUMEISTER, H.G. LIEBICH, C. HAMMER — Experiences in experimental reconstructive microsurgery of lymphatics. *In : Progress in Lymphology XI*, H. PARTSCH Ed., Elsevier Science Publisher, Amsterdam 1988, p. 415-418.

7) YUWONO H.S., P.J. KLOPPER — Comparison of lymphatic and venous interpositional autografts in experimental microsurgery of the canine lymphatics. *Plast. Reconstr. Surg.*, 86, 752-757, 1990.

THE EUROPEAN JOURNAL
OF
lymphology
and related problems
VOLUME 5 • Nr 17-18 • 1995

# Thermotherapy and microsurgery : new trends in the management of lymphedema.

C. CAMPISI, F. BOCCARDO, M. TACCHELLA
*University of Genoa*
*Department of Emergency Surgery*
*Microsurgery Center, Italy.*

## INTRODUCTION

Our technique of hyperthermia is an alternative to microwave therapy, particularly where lymphangitis coexists in the same limb. In those patients with longstanding obstructive lymphedema worsened by obliterative lymphangitis, before using a microsurgical procedure, if any hyperthermic therapy is indicated.

Preoperative diagnostic evaluation including lymphatic and venous isotopic scintigraphy, Doppler venous flow matrics and pressure manometry play an essential role in delineating the status of both the lymphatic and venous systems.

Arterial disease, tumors and pregnancy represent a genuine contraindication to thermotherapy. In this regard, it is essential firstly to assess together with the peripheral lymphatic and venous systems also the arterial circulation. In our registry, approximatively 5 % of patients with lymphedema have relapsing lymphangites precluding straight feasibility of lymphatic shunting operations.

Although microwave hyperthermia has been used successfully in these situations, this procedure is contraindicated in patients with pace-maker or cemented prosthesis and may be associated with little skin burns caused by the warming of droplets of sweat. Alternatively, this group is amenable to our hyperthermia procedure.

This report describes our preliminary clinical experience with this approach used before lymphatic-venous-lymphatic shunt operation, in patients with postlymphangitis obliterans lymphedema (either arm or leg), to prevent appearance of any other lymphangitis post-operatively.

## METHODS

Our apparatus for hyperthermic therapy consists of two parts joined by a tube covered with a nonconducting material in order to prevent the leakage of heat.

The control plant includes the device to atomize water and the electric air heater and blower. Hot water is then atomized through the insulated tube inside the cylindric chamber where the limb is placed and where a hygrometer and a thermometer measure humidity and temperature inside the chamber. Temperature of 41 C degrees and humidity of 80 % are used generally. A thermostat regulates temperature and automatically controls the heating unit setting of the sprinkler at a certain heat.

Hyperthermia was performed in 32 patients (Table I), with postlymphangitis chronic lymphedema, who underwent our operation of lymphatic-venous-lymphatic anastomosis, 3 months - 6 months after the end of thermotherapy. The reason for such an interval between the end of thermotherapy and operation lays in the fact that, based on our clinical experience, the predisposition for the recurrence of infection, following also a single episode of clinically manifest lymphangitis, can be left from the anatomo-pathological point of view as it occurs in most patients undergoing only medical therapy.

Two patients had primary arm lymphedema and 9 primary leg lymphedema, with recurrent lymphangitis. Three patients had secondary arm lymphedema and 18 secondary leg lymphedema, with recurrent lymphangitis.

The average age of these patients was 36 years (range 18 - 55 years) with females predominating (about 1.5 : 1) (Fig. 1, a - b).

Our treatment schedule for patients with postlymphangitis lymphedema undergo 10 - 12 daily applications, every month, for 6 months.

Clinical criteria to evaluate the patients included measuring limb circumference before hyperthermia treatment and after operation, volumetry measurements with a water volumeter, assessment of complete recovery from lymphangitis and any recurrency of the disease, functional change.

Lymphangioscintigraphy and echo-scan were used to assess reduction of limb edema and improvement of lymph flow, and particularly echo-scan proved remarkable reduction of thickness and fibrosis of subcutaneous tissue.

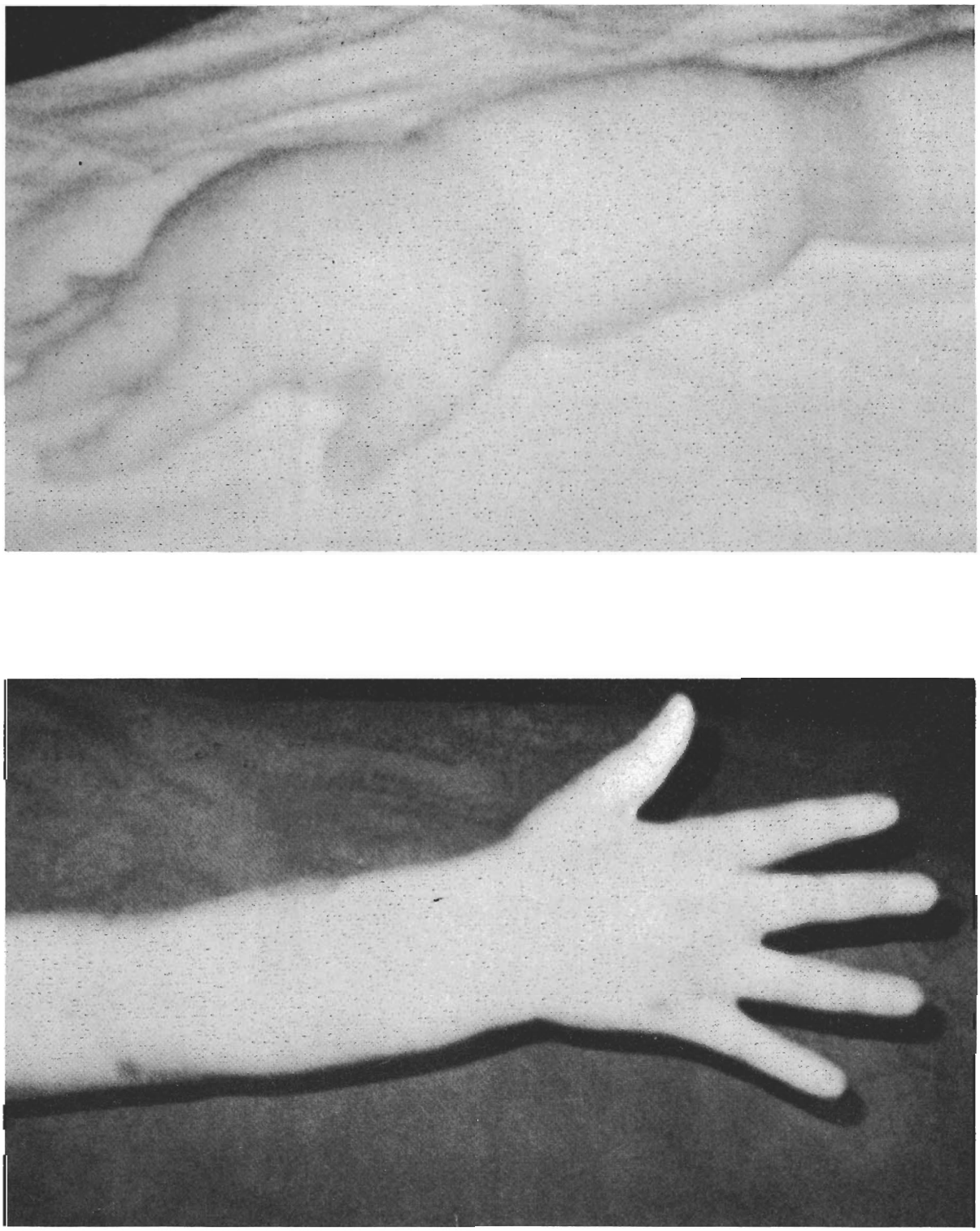

*FIGURE 1, a - b*

*Primary lymphedema of right arm at the 3rd stage treated by hyperthermia and LVL shunt operation, before (a) and after one year (b) from operation.*

THE EUROPEAN JOURNAL
OF
lymphology
and related problems
VOLUME 5 • Nr 17-18 • 1995

# La microchirurgie lymphatique en Roumanie.

# Lymphatic microsurgery in Romania.

A. KAUFMANN, G. CIUSE

*Societatea Română de Angiologie şi chirurgie vasculară*
*str. Clinicilor 4-6*
*3400 Cluj-Napoca - România*

**SUMMARY**

In Romania activities dealing with lymphatic pathology have a long tradition (GEROTA, 1896).

A second period is marked by the issue of the first lymphography (KAUFMANN, 1962).

Afterwards, methods, techniques and introduced in the clinical practice of the lymphopathies / phlebolymphography, lymphangioplasty with human hair, lymphangiectomy of the leg.

Between 1970-1980, in the lymphedematherapy, were privilaged exeresis techniques. The first experimental lab. of microsurgery dates from 1983, and in 1984 the first microsurgical lymphnode-vein anastomoses are performed in Cluj (KAUFMANN).

Experimental researches were carried out in terms of microsurgical lymphnode - vein and lympho-capsulo-venous anastomoses. The results showed the superiority of the lympho-capsulo-venous anastomosis.

In clinical practice were practical methode of microsurgical collector-vein drainage (DEGNI-FOX) and lymphnode-vein drainage.

The results were :

at the collector-vein / inguinal (Cluj)
— immediate = very good
— late = good
/ -leg (Timişoara)
— immediate = satisfactory
— late = unsatisfactory.

Techniques of lymphatic reconstruction are used only experimentally.

Les préoccupations pour la pathologie lymphatique en Roumanie ont de vieilles traditions. Il faut rappeler les études du Dr GEROTA (1896) qui, il y a 100 années, imaginait l'une des meilleures méthodes d'injection des lymphatiques au cadavre. Elle continue d'être utilisée aujourd'hui dans la recherche expérimentale.

La possibilité de l'exploration du système lymphatique par lymphographie directe et par lymphoscintigraphie a relancé dans tout le monde médical les préoccupations pour cette pathologie. Celles-ci ont été les conditions où, depuis 1962, on pratique, en Roumanie, la première lymphographie directe chez l'homme. En 1970 apparaît la première monographie, *La lymphographie* (Aurel KAUFMANN - *L'Edition Médicale*), en continuant avec la monographie, *La lymphographie dans la pratique clinique* (ROXIN-BUJAR, 1981 - *L'Edition de l'Académie*), *Le système lymphatique dans le Shock* (V. CÂNDEA).

On introduit des méthodes, des classifications, des techniques dans la pratique clinique des lymphopaties :

- la phlébolymphographie, méthode combinée pour l'exploration simultanée du système veineux et lymphatique périphérique ;
- la classification clinique des lymphœdèmes (KAUFMANN), utile pour le médecin praticien non-spécialiste ;
- la lymphangioplastie, avec des fils du cheveu humain, comme méthode du drainage dans les lymphœdèmes post-traumatiques (KAUFMANN) ;
- la lymphangiectomie totale du pied (KAUFMANN), comme complémentation de la technique de SERVELLE.

## *Comment la pratique et la recherche lymphologique ont-elles évolué en Roumanie ?*

En 1962, on a fait la première lymphographie (Cluj-Napoca).

En 1970, elle est introduite, en pratique, à Timişoara, Bucureşti, TG. Mureş, Iagi.

En 1957, on pratique les premières lymphangiectomies (Kondoléon).

THE EUROPEAN JOURNAL
OF
lymphology
and related problems
VOLUME 5 • Nr. 17-18 • 1995

# FINAL REMARKS

C. CAMPISI

*(Genoa, Italy)*

I had no doubt, considering the high qualities of speakers, as our Honorary President Prof. M. CASACCIA said at the beginning, that we could have arrived at the end of this Symposium so satisfied.

I believe that today we put another important little stone in the building that all together we are going to build, trying to succeed in giving to the patients, affected from lymphedema, a clear way to follow with a precise diagnostic and therapeutic programme.

Nevertheless there are yet a lot of different points of view between the experts of this particular field, but certainly we could say we have tried to take the right way.

First of all, the patients affected by lymphedema has to be studied in a complete way without neglecting the relationship between venous and arterial circulation.

We have to find the cause of lymphostatic pathology and in the case of an idiopathic etiology to establish preliminarly the existence or not of lymphatic vessels or lymphnodes anatomically and functionally utilisable for our therapeutical procedures.

The direct lymphography not always van be refused *a priori* to our patients.

The lymphoscintigraphy is very useful for the *depistage* of patients and for the follow-up, very useful too are the imaging diagnostic procedures and above all the ecotomography.

But direct lymphography if well done, can result reliable in a patient designed to surgical therapy. Microsurgery has almost overcome old demolitive and antiesthetic techniques, giving a defined space only for the reductive plastic operations for the serious and inveterate cases.

Microsurgery can be today considered an aesthetic, functional and conservative surgical therapy to use precociously in the selected lymphedema in IIo and IIIo stage.

What kind of techniques we can use ? The derivative techniques or the reconstructive ones ? And, among the derivative techniques which of these ? Certainly the end-to-side lymphatic-venous anastomoses have got over a lot of proves and the experience is great (Figs. 1 - 2 - 3, a - b - c - d).

Among the reconstructive techniques, which one we can adopt ?

Here, we believe that the problem is open yet. However, according to our experience we can deserve that the use of venous graft makes easier and shorter the operation, and, if a technique is simple like this, you can perform it more frequently and the success of this method is almost always obtained (Figs. 5 - 6, a - b - c - d - e).

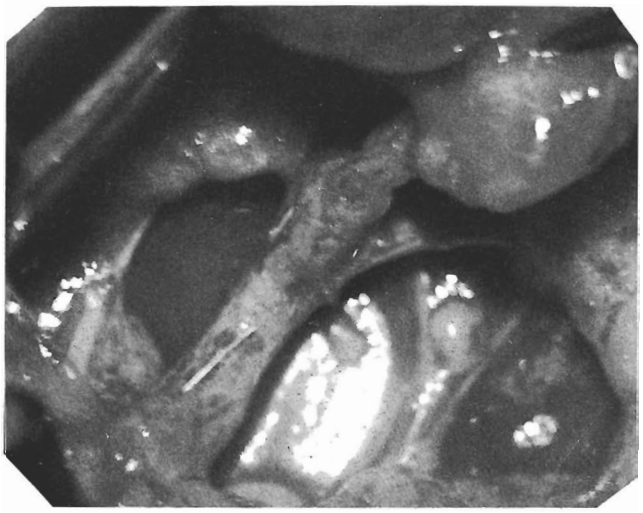

*FIGURE 1*

*End-to-side multiple lymphatic-venous anastomoses. Note blue dyed lymphatic collectors introduced end-to-side into the vein and the little stitch of anchorage of lymphatics to the venous wall.*

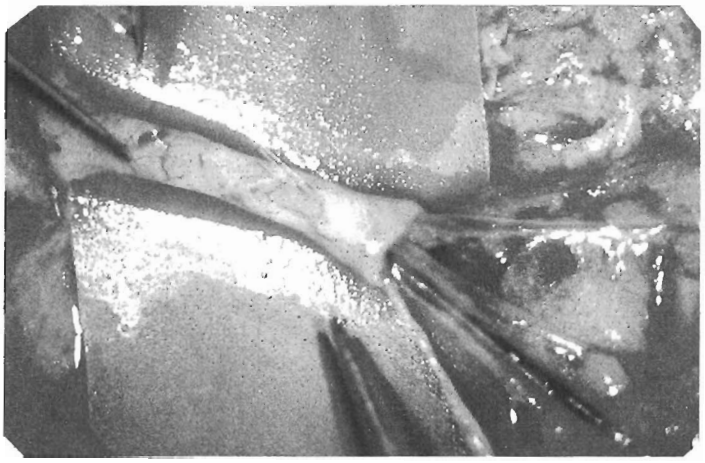

*FIGURE 2*

*End-to-end multiple lymphatic venous anastomoses. The blue dyed lymphatic collectors are introduced (with a simple U stitch) inside a valved secondary branch of the great saphenous vein, after having previously controlled that there is no blood back flow. This particular technical " trick " was personally conceived and performed because of the great distance between the " saphena magna " and lymphatic collectors.*

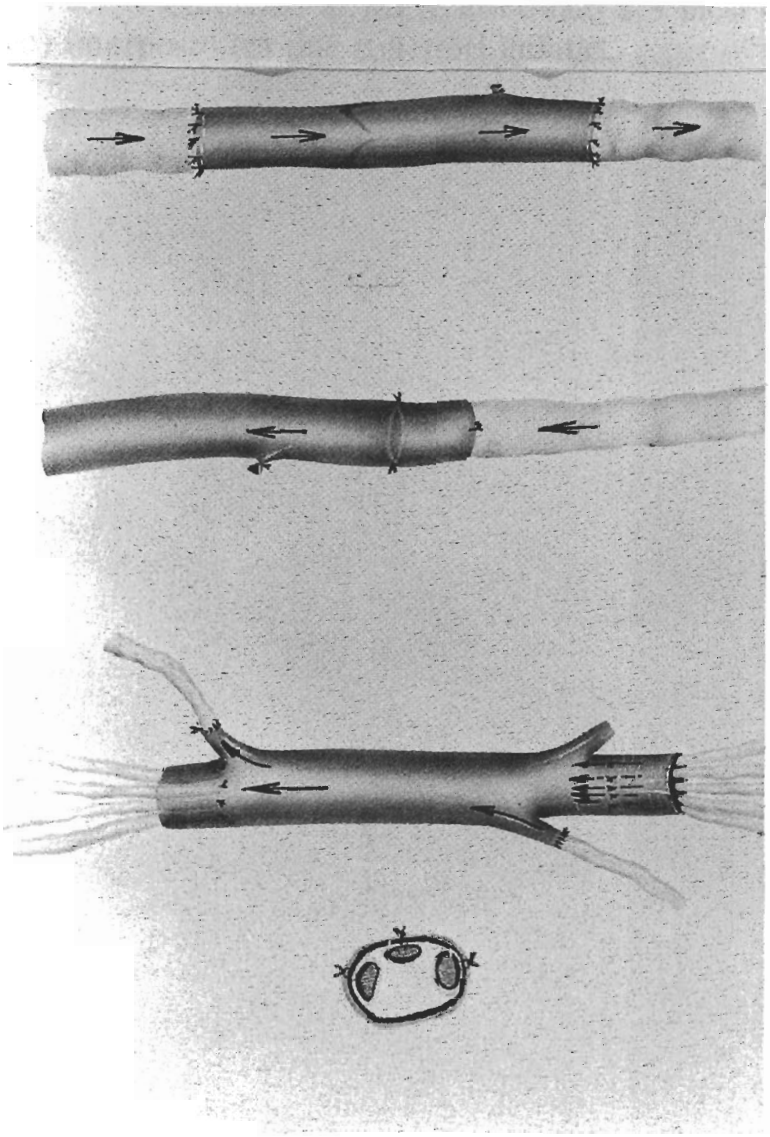

*FIGURE 4*

*Schematic drawing of the personal technique of lymphatic-venous-lymphatic anastomoses, used in those patients in whom there exists also a venous disorder at the same lymphedematous limb and where, therefore, lymphatic-venous shunts are contraindicated.*

*FIGURE 5 ( a - b - c - d - e)*

*Clinical observation of a patient (a) affected from secondary chronic left leg lymphedema, appeared after an operation of inguinal-iliac-lumbar-aortic lymphoadenectomy for a seminoma of left didymus and the association of radiotherapy. Since the veins at the tigh were completely sclerotic and no lympho-venous derivative shunt was, therefore, performable, the only possible microsurgical solution was that of creating a new lymphatic pathway, using an autologus venous graft, harvested from the volar surface of the right forearm (b), between lymphatic collectors found at the suprapublic site (c) and the lymphatics found at the upper third of the thigh (d). Note the remarkable decrease of edema just at only one week after operation (e).*

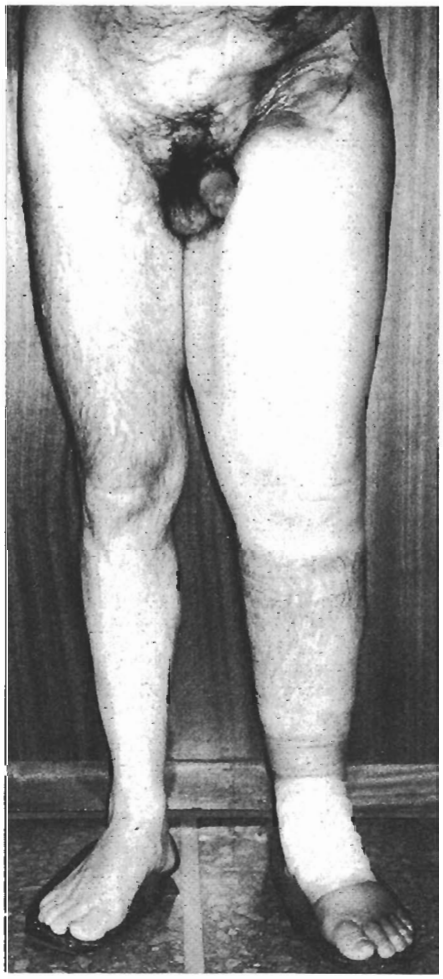

a



b

c

d

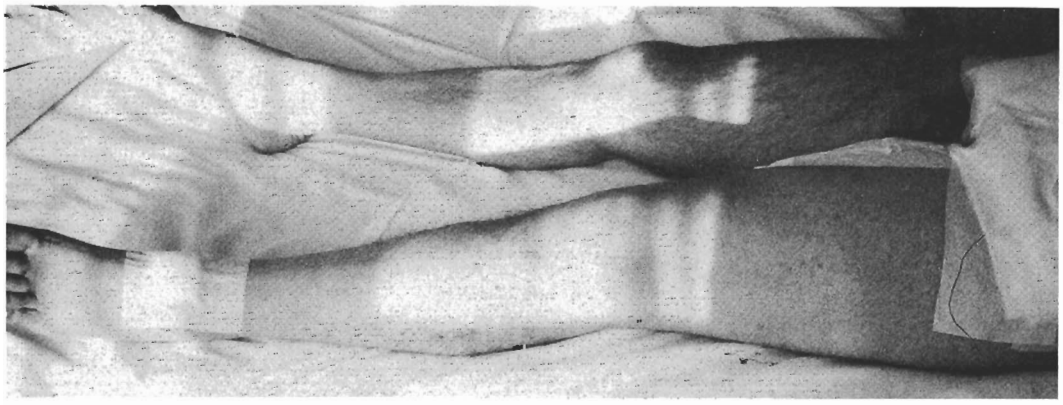

e

THE EUROPEAN JOURNAL
OF
lymphology
and related problems
VOLUME 5 • Nr 17-18 • 1995

# XVIIIth MEETING
## of the
# EUROPEAN GROUP OF LYMPHOLOGY
## (G.E.L.)

BRUSSELS 6 - 7 MAY 1994

# ABSTRACTS

## MORPHOLOGY

### STUDY OF THE LYMPH DRAINAGE OF THE THYROID GLAND
### ETUDE DU DRAINAGE LYMPHATIQUE DE LA THYROÏDE

Dr. M. SELLAM
Chirurgie carcinologique,
Centre Pierre et Marie Curie, Alger

Dr. G. HIDDEN
Faculté de Médecine des Saints Pères
Paris 6me

Do the infradigastric ganglions constitue the principal ganglionic relay of the thyroid gland ? If so, wouldn't it not be possible to do a systematic excision of a ganglion at this level for an anatomo-pathological extemporary study, of which the results would decide on a limited curage (N−) or an extended curage (N+). This had brought us to undertake an anatomical study on the lymph drainage of the thyroid gland that we will compare to the N+ topography (ganglionic metastasis) in not medullary thyroid cancers.

This anatomical work has permitted us to study the lymphatic anastomoses between the lobes and with contiguous organs (f.i. trachea).

Les ganglions sous-digastriques constituent-ils le principal relais ganglionnaire de la thyroïde ? Si oui, ne pourrait-on pas faire systématiquement un prélèvement ganglionnaire à ce niveau pour une étude extemporanée anatomo-pathologique dont les résultats décideront d'un curage limité (N−) ou d'un curage étendu (N+) ? Ceci nous a amenés à faire une étude anatomique sur le drainage lymphatique du corps thyroïde que nous comparerons à la topographie de N+ (métastases ganglionnaires) dans les cancers thyroïdiens en dehors des médullaires.

Ce travail anatomique nous a permis d'étudier sur les anastomoses lymphatiques entre les lobes et avec les organes contigus (trachée par exemple).

### EMBRYONIC APPEARANCE AND GROWTH OF THE HUMAN LUNG LYMPHATICS
### APPARITION ET CROISSANCE EMBRYONNAIRE DES LYMPHATIQUES DU POUMON CHEZ L'HOMME

RIQUET M. [1,2], HIDDEN G. [2]
1) Service de Chirurgie Thoracique (Pr. DEBESSE)
Hôpital Laennec, Paris
2) Laboratoire d'Anatomie (Pr. LASSAU)
Biomédicale des Saints-Pères, Paris

According to LIMBORGH, paratracheal lymphatic plexures appear in an embryo of 13 mm and a unique primordium under the tracheal bifurcation at 22 mm.

In order to study in more detail the development of the lung lymphatics, we studied histological sections of 71 human embryos and foetus from the collection of the Laboratory of Anatomy of the biomedical UER Saints Pères. Their size, calculated from the vertex to the sacrum, was between 16 and 92 mm ; 49 of them were cut transversally in series, 15 sagitally, 7 in frontal sections. We have observed lymphatic vessels from 21 mm, lymphoid tissue between 33 and 42 mm and lymph nodes from 69 mm. These elements appear at the same period whatever the observed anatomical region : intertracheo-broncheal, suprabroncheal left, pretracheal right and triangular ligaments. The lymph vessels established connections with the veines at the base of the neck and with the thoracic duct in the mediastinum just after the first lymphoid elements appear.

The lung lymphatics are therefore constituted and at their definitive position before the end of the embryonic growth as defined by PINEAU.

Selon LIMBORGH, des plexus lymphatiques paratrachéaux apparaissent chez l'embryon de 13 mm et un primordium unique sous la bifurcation trachéale à 22 mm.

De façon à étudier plus avant le développement des lymphatiques du poumon, nous avons revu des coupes histologiques de 71 embryons et foetus humains de la collection du Laboratoire d'Anatomie de l'UER Biomédicale des Saints Pères. Leur taille calculée du vertex au sacrum allait de 16 à 92 mm : 49 étaient coupés en série transversalement, 15 sagitalement, 7 frontalement. Nous avons observé des vaisseaux lymphatiques dès 21 mm, du tissu

# PHYSICAL TREATMENTS

## NEUROGENIC EDEMA IN PATIENTS WITH ARM HEMIPLEGIA

HUTZSCHENREUTER P., BRÜMMER H., WERNER G.T.
Department of Experimental Surgery II,
University Ulm (Germany) and
Hospital of Physical Medecine,
Munich-Bogenhausen (Germany)

Dermal electric resistance was registered in 21 patients with hand and finger edema caused by arm hemiplegia. This parameter was measured in 7 patients at rest (controls), and in 14 patients before, during and after manual lymph drainage (MLD). 7 patients treated had a motor arm hemiplegia and 7 patients treated had spastic arm hemiplegia. All patients were treated for 50 minutes per day and over a period of 7 days. Results : dermal electrical resistance remained unchanged, regardless of wether it was measured during MLD treatment or at rest over an observation time period of 9 days. But spontaneously, spastic fingers extended fully, although temporarily, in 5 of 7 patients during MLD sessions beginning with the 4th MLD treatment. This development was accompanied by a significant paralell increase in dermal electrical resistance ($p < 1$ %). According to G.T. WERNER et al. (1991), there is dynamic insufficiency of the lymph vessel system in patients with arm hemiplegia. Our paper will discuss why this kind of hand and finger edema may not causes by inactive muscle and joint pump. These hand and finger edemas are caused by neurogenic factors. Therefore, they should to be treated with physiotherapy, compression therapy, ergotherapy and with MLD, which are listed here in order of therapeutic importance.

## LYMPHOSCINTIGRAPHIC VALIDATION OF MANUAL LYMPH DRAINAGE IN A SECONDARY LYMPHOEDEMA OF THE UPPER LIMB (50 cases)

## VALIDATION LYMPHOSCINTIGRAPHIQUE DU DRAINAGE LYMPHATIQUE MANUEL DANS LE LYMPHŒDÈME SECONDAIRE DU MEMBRE SUPÉRIEUR (A propos de 50 cas)

J.C. FERRANDEZ *, D. SERIN **, J.M. VINOT ***
* Rue Velouterie 2bis, Avignon F 84000
** Clinique Sainte Catherine, Avignon F 84000
*** Médecine Nucléaire, CH Avignon F 84000

50 patients with an average age of 61.5 years (32 to 80 y) underwent a radiosurgical breast cancer treatment (16 tumorectomies, 34 mastectomies).

They all presented an oedema in the upper limb which was neither due to neoplastic relapse, nor to a diagnosted thrombophlebitis. Their oedema was manifest as a mean perimetrical increase of 6.1 cm for the forearm (1 to 33 cm) and 5.3 cm for the upperarm (1 to 18 cm), mean history of 3 years (0 to 21 years). The dominant limb was affected in 24 cases and 24 patients underwent a direct radiotherapy of the axilla.

They underwent a static lymphoscintigraphic exploration where we compared :

- cliché L1 obtained 30 min after injection of 99m-Tc labelled antimony sulfide colloids.
- cliché L2 obtained after a 30 min session of manual lymph drainage.

The comparison between cliché L2 and cliché L1 demonstrates the different action modalities of the manual lymph drainage in the lymphoedema of the upper limb.

Notably, the different heights of progression obtained (fore arm, upper arm, ganglions) and the pathways transporting the colloids (lymph collectors, interstitial space, perivascular and extravascular space) are analysed.

Finally, in 40 cases, the lymphoscintigraphic images were correlated with the results of perimetrical decrease of the oedema obtained by identical physiotherapy. We try to answer the next question : " Does the lymphoscintigraphic image give a prognosis of the lymphoedema reduction ? ".

50 patientes âgées en moyenne de 61.5 ans (bornes de 32 à 80 ans) ont bénéficié d'un traitement chirurgical d'un cancer du sein (16 tumorectomies, 34 mastectomies).

Elles présentent toutes un œdème du membre supérieur qui n'est ni le fait d'une récidive néoplasique, ni celui d'une trombophlébite diagnostiquée. Leur œdème se traduit par une augmentation périmétrique moyenne de 6,1 cm à l'avant-bras (1 cm à 33 cm) et 5,3 au bras (1 cm à 18 cm), d'ancienneté moyenne de 3 ans (0 à 21 ans), atteignant 24 fois le membre dominant ; 24 des patientes ont eu une radiothérapie directe du creux axillaire.

Elles bénéficient d'une exploration lymphoscintigraphique statique où l'on compare :

- le cliché L1 obtenu 30 min après injection d'une solution colloïdale de sulfure d'antimoine marquée au Technétium 99m.
- le cliché L2 obtenu après une séance de drainage lymphatique manuel de 30 min.

La comparaison des clichés L2 par rapport à L1 met en évidence les différentes modalités d'action du drainage lymphatique manuel dans le lymphœdème du membre supérieur.

Notamment, sont analysées les différentes hauteurs de progression obtenues (avant-bras, bras, ganglions), et les voies de cheminement du colloïde (collecteurs lymphatiques, espace interstitiel, espace péri- et extra-vasculaire).

Enfin, chez 40 d'entre elles, les images lymphoscintigraphiques sont corrélées aux résultats de diminution périmétrique de leur œdème obtenu par une physiothérapie identique. Nous essayons de répondre à la question suivante : " L'image lymphoscintigraphique donne-t-elle le pronostic de réduction du lymphœdème ? ".

## INTERRELATIONSHIP BETWEEN EPI- AND SUBFASCIAL PRESSURE CHANGES INDUCED BY MLD

DERDEYN A., ASSLAM M., PFLUG J.J.
Swollen Limb Clinic, Royal Postgraduate Medical School,
Hammersmith Hospital, London, Great Britain.

The mode of action of Manual Lymph Drainage (MLD) has not yet been fully elucidated.

The authors measured pressure changes induced by MLD epi- and subfascially (ant. tib. compartment) in 15 patients with unilateral chronic swelling of the leg. In 8 patients the swelling was of lymphatic, in 5 of venous origin and two presented with lipoedema of many years duration.

The tissue pressure changes were monitored by modified slit-catheter technique and correlated with venous flow alterations in the common femoral vein as displayed by colour coded duplex sonography.

MLD changed the resting continuous tissue pressure in an intermittent one, both epi- and subfascially and resulted after 30 min. of massage in its considerable decrease.

The drop of pretreatment pressure was more significant in the epifascial than in the subfascial tissue.

The results suggested that :

- the interstitial fluid is the main target organ of MLD ;
- the mode of action of this treatment modality is the normalisation of the pathologically encreased tissue pressure.

## MANUAL LYMPH MASSAGE PERFORMED BY HIGH PRESSURE MORPHOLOGY OF LYMPHATICS

ELISKA O, ELISKOVA M.
Dep. of Anatomy,
1st. Medical Faculty,
Prague, Czech Republic

For many years the manual lymph massage (drainage) has been

In 2 cases of LLE with residual inguinal lymph nodes pre-op the post-operative lymphoscintigraphy suggested a functional improvement with visualisation of additional lymph nodes in 1 case.

In 2 cases of ULE without residual axillary lymph nodes pre-op, a first axillary graft was characterized by the post-operative lymphoscintigraphy as a functional improvement without the visualisation of the grafted lymph nodes, but in once case, a with a better progression of the tracer and in the other an individualisation of lymphatic vascular pathways. The subsequently grafted brachial lymph nodes showed a " colloidopexic " activity.

In 1 case of ULE with residual axillary lymph nodes pre-op and with a brachial lymph nodes graft, the post-operative lymphoscintigraphy suggested a functional improvement with appearance-individualisation of lymphatic vascular pathways towards the graft site but without visualisation of lymph nodes at this level.

In the last ULE case without residual axillary lymph nodes pre-op, but where a lymph vessel ends in the armpit, the axillary graft resulted in the appearance of several axillary lymph nodes.

These observations suggested :

- a lymphoscintigraphic functional improvement in 7 cases of 10 ;
- a colloidal uptake in only 4 lymph nodes grafts of 12 ;
- a " lymphangiogenetic " effect of these grafts with appearance-individualisation of lymphatic vascular pathways towards the graft site (and this usually within a pre-existing network of superficial dermal collateralisation). These results and observations will be correlated with the clinical results of the operation. They should of course be confirmed on larger series, but they underline however the necessity of detailed protocols in investigative lymphoscintigraphy.

Les lambeaux libres ganglionnaires représentent une des approches chirurgicales du traitement des œdèmes des membres (OM). Dans ce travail, qui a porté sur 9 patientes et 1 patient (âge moyen : 61 ans, 6 OM supérieurs et 4 OM inférieurs d'origine iatrogène, 4 greffes inguinales – Ing., 5 axillaires, – Ax et 3 branchiales, – Br, greffes à deux niveaux du membre dans 2 cas), les modifications morphologiques et fonctionnelles post-opératoires du système lymphatique ont été évaluées comparant les résultats de lymphoscintigraphies - Lysc - des MS ou des MI réalisées avant opération et de 2 à 14 mois plus tard.

Dans 3 cas (1 OMI et 2 OMS), respectivement investigués 7,5 et 8 mois post-op) où aucune structure ganglionnaire résiduelle - rés - Ing ou Ax ne put être mise en évidence, aucune amélioration de la situation Lysc ne fut observée.

Dans 1 cas d'OMI sans GG Ing rés pré-op, (contrôlé 6 mois post-op), la Lysc suggérait une amélioration du drainage mais sans visualisation des GG greffés.

Dans 2 cas d'OMI avec GG Ing rés pré-op, la Lysc port-op suggérait une amélioration fonctionnelle avec visualisation de GG additionnels dans un cas.

Dans 2 cas d'OMS sans GG Ax rés pré-op, une première greffe GG Ax se traduisit à la Lysc post-op par une amélioration fonctionnelle sans visualisation de GG greffés mais avec dans un cas une meilleure progression du traceur et dans l'autre l'individualisation de trajets vasculaires lymphatiques. Les GG Br ultérieurement greffés quant à eux montrèrent une activité colloïdopexique.

Dans 1 cas d'OMS avec GG Ax rés pré-op et greffe GG Br, la Lysc post-op suggérait une amélioration fonctionnelle avec apparition-individualisation de trajets vasculaires lymphatiques vers le site de greffe mais sans GG visualisable à ce niveau.

Dans le dernier cas d'OMS enfin sans GG Ax rés pré-op mais où un vaisseau lymphatique aboutissait au creux Ax, une greffe Ax résultait en l'apparition de plusieurs structures GG Ax.

Ces observations suggèrent donc :

- une amélioration fonctionnelle Lysc dans 7 cas sur 10 ;
- une " prise de contraste " colloïdal dans 4 sites de greffes GG sur 12 seulement ;
- un effet " lymphangiogénésique " de ces greffes avec apparition-individualisation de trajets vasculaires lymphatiques vers le site de greffe (et ce d'ordinaire au sein d'un réseau pré-existant de collatéralisation dermique superficiel). Ces résultats et observations seront corrélés avec le résultat clinique de l'opération. Ils devraient naturellement être confirmés sur de plus grandes séries mais soulignent la nécessité de protocoles d'investigations Lysc détaillés.

## QUANTITATIVE LYMPHOSCINTIGRAPHY FOR THE EVALUATION OF LYMPHOTICO-VENOUS ANASTOMOSIS (LVA) IN TREATMENT OF UPPER LIMB EDEMA (ULE)

M. DE ROO *, H. VERLOOY *, J.P. BISCOMPTE **,
L. NIEUBORG **, L. MORTELMANS *, C. SCHIEPERS *
* Division of Nuclear Medicine,
University Hospital, Leuven, Belgium
** Division of Vascular Surgery,
H. Hartkliniek, Leuven, Belgium

Lymphoscintigraphy (LS) is a simple atraumatic technique to assess lymphatic function. The aim of present study was to evaluate the value of quantitative lymphoscintigraphy for the assessment of the effect of LVA on lymph flow and for the evaluation of LVA patency in patients with ULE.

Twenty patients with ULE post-mastectomy, axillary lymphadenectomy and radiation therapy underwent LS pre- and post-shunting. 55 Mbq of TC-99m sulfur colloid (Lymphoscint) was administered subcutaneously in the first interdigital space. Dynamic images of the arm were obtained with an LFOV camera for 45 minutes, followed by static images of the arm and the liver 5 hours after injection. Aforementioned parameters were correlated with the changes of the circumferential measurements of upper limb (Raines formula) after LVA.

The combined information from the uptake curves in the forearm and the upper arm, the visual evaluation of tracer migration during the first 45 minutes of the exploration and the early and late measurement of tracer uptake (in % of the dose) in the arm and axilla gives the possibility to evaluate the lymph migration in the upper limb. The tracer passage from the lymph vessels to the general circulation through the LVA can be estimated by measuring the liver tracer uptake, except in case of remaining axillary nodes.

The effect of microsurgical reconstructive surgey was considered as positive if arm circumferences decrease (Raines 40), this was the case in 11 out of 20 cases. In this patient group there was only liver uptake in 6 cases, the parameters of lymph migration in the arm were demonstrative of increased lymphatic flow 8 cases. In the patient group without benefit of reconstructive surgery the changes of the migration parameters are few and related to circumscriled lower arm uptake.

The changes of scintigraphic images pre-versus and post-surgery are in general not pronounced, only the quantitative parameters of lymph transport demonstrate adequately the effect of microsurgical reconstructive surgery. Contrary to our expectations, we found the measurement of limb uptake in combination with the scintigraphic images more useful for the evaluation of lymph transport than the liver uptake. The data of the lymph transport in the arm indicate besides the necessity for a second anastomosis also the level where the anastomosis has to be made.

## LYMPHATIC REGENERATION IN THE LIMB RECONSTRUCTIVE SURGERY

A. NASCIMENTO, M.F. PACHECO, M.F. BOTELHO,
A.C. SANTOS, N. CANHA, J.J. PEDROSO DE LIMA
Department of Biophysics
Medical School and Orthopedic Department
of University Hospital, Coimbra University, Portugal

Experimental data in the plastic reconstruction of the limbs, namely in reimplantations and free flaps, shows that oedema begins to disappear on the 15th day, complete resolution occuring in 3 to 4 weeks. Despite the non surgical reconstruction of the lymphatic vessels, the lymphatic function is shown to be partially recovered. To study this problem a dynamic model was developed and tested in mongrel dogs using radioactive and angiolymphographic techniques. Partial amputations were performed in one of the pelvic limbs of the dog to study the evolution of lymphatic regeneration during a period of 3 months. Rhenium sulphide colloid ($Re_2S_7$, with 10 mm mean diameter) labelled with $^{99m}Tc$ (111 MBq) was used as tracer. An interdigital injection, 0.2 to 0.25 ml solution, was performed in the lower limbs. The non operated limb was used as control. A gamma camera GE 400 AC/Starport plus a DecStation 5000/200 were used. From the activity/time curves in 11 ROIs drawn along the limb, the dynamics of the lymph was studied using home made software.

## POST-THERAPEUTIC OEDEMA AFTER BREAST CANCER SURGERY AND / OR RADIOTHERAPY (WHO IS RESPONSABLE ?) - LYMPHOSCINTIGRAPHIC DATA.

## LES ŒDÈMES POST-THÉRAPEUTIQUES APRÈS CANCER DU SEIN : CHIRURGIE ET / OU RADIOTHÉRAPIE (QUI EST " COUPABLE ?) - DONNÉES LYMPHOSCINTIGRAPHIQUES.

P. BOURGEOIS, A. DELCORDE ET J. FRÜHLING
Services de Médecine Nucléaire,
Hôpital Universitaire Saint-Pierre, Clinique de la Basilique
et Institut Jules Bordet,
Bruxelles, Belgique.

Upper limb oedema ULE remains a frequent complication after breast cancer surgery and / or radiotherapy. Amongst the incriminating factor in their pathogenesis, the surgical technique, its " quality " (axillary nodes resection) and its consequences on lymphatic drainage of the upper limb appears to be the most difficult to demonstrate objectively. 1073 patients who underwent a complete axillary curage between end of 1978 and 1989 for breast cancer, have systematically been investigated postoperatively by lymphoscintigraphy of the upper limb. After injection of the 99m-Tc labelled colloids in the first interdigital space of each hand, one or several residual axillary nodes were visualised in 769 patients (Id + cases) or 71.6 % of this population. The frequency of oedema of the upper limb subsequently arising (average follow up = 5 years) has appeared very significantly superior in patients where the lymphoscintigraphy had not showed any axillary nodes (KAPLAN - MEIER method, LOGRANK test). According to COX (multivariance analysis) in a modelisation where the radiotherapy (or no) of axillary and supra-clavicular regions is also introduced, this therapy (which in univariance analysis is prognostically responsable for upper limb oedema), does not appear to have any statistical significance, nor does it modify the impact on the lymphoscintigraphic results.

The conclusion is therefore :

- surgery remains the principal causal factor in the genesis of the upper limb oedema.
- post-operative lymphoscintigraphy permits to characterize a group of patients at risc and its systematic apply is therefore recommended.

L'œdème du membre supérieur (OMS) reste une complication fréquente après chirurgie et / ou radiothérapie du cancer du sein. Parmi les facteurs incriminés dans leur pathogénèse, la technique chirurgicale, sa " qualité " (du curage axillaire) et ses conséquences sur le drainage lymphatique du MS apparaissent comme les plus difficilement " objectivables ". 1073 patientes ayant bénéficié d'un curage axillaire (ax) dit " complet " entre fin 78 et fin 89 pour cancer du sein, ont été systématiquement investiguées post-opératoirement par la lymphoscintigraphie (LySc) des MS. Après injection de colloïdes technétiés dans le premier EID de chaque main et du côté opéré, un ou plusieurs ganglions (gg) ax " résiduels " ont été ainsi visualisés chez 769 patientes (cas Id+) ou 71.6 % de cette population. La fréquence d'OMS survenant ultérieurement (follow-up moyen = 5 ans) est apparue très significativement ($2p < 0.0001$) supérieure chez les patientes où la LySc n'avait pas démontré de ganglions ax (méthode actuarielle de KAPLAN MEIER, test de LOGRANK).

Dans une modélisation selon COX (analyse multivariée) où la radiothérapie (ou non) des régions axillaires et sus-claviculaires est également introduite, cette dernière (qui en analyse univariée est pronostique-responsable d'OMS) n'apparaît plus avoir de signification statistique, ni modifier l'impact du résultat de la LySc.

Il est donc conclu que :

- la chirurgie reste le facteur causal principal dans la genèse des OMS.
- la LySc des MS pratiquée post-op permet de caractériser un groupe de patientes à risque et sa réalisation systématique est donc recommandée.

## THE PATHOGENETICALLY MOST RELEVANT STRUCTURAL CHANGES IN LYMPHOEDEMA

PFLUGG J.J., ASSLAM M.
Swollen Limb Clinic,
Royal Postgraduate Medical School,
Hammersmith Hospital, London, Great Britain

So far lymphoedema was believed to affect exclusively the epifascial tissues. However, the preoperative findings have consistently shown that from alle layers of the soft tissue coat the fascia of the muscular compartments displayed the most severe pathological changes. A more detailed analysis of these findings suggested that

- the thickening and fibrosis of the fascia preceeded the fibrotic alterations of the skin and subcutaneous tissue and
- the degree of fascial thickening correlated very well with the severity of lymphoedema.

The validity of this observation was confirmed by subfascial tissue pressure measurements on the one hand, and by excellent therapeutic results after releasing fasciotomy on the other. The most important clinical implication of these structural changes should be an upgrading of surgical treatment in all forms of lymphoedema.

# FREE PAPERS

## TOWARDS A NEW MICROCIRCULATORY MODEL FOR THE PHYSIOLOGY OF MANUAL LYMPH DRAINAGE

## VERS UN NOUVEAU MODÈLE MICROCIRCULATOIRE POUR LA PHYSIOLOGIE DU DRAINAGE LYMPHATIQUE MANUEL

A. BEHAR, L. ROBERT, H. BOULAHDOUR,
A. MAUREL, G. LAGRUE
Service de biophysique et médecine nucléaire,
Hôtel Dieu, Paris
Polyclinique, Hôpital H. Mondor,
94000 Créteil France

Manual lymph drainage, according to the method LEDUC, appears clinically efficient in the orthostatic idiopathic oedema (OIO), although there is no basic affection of the lymphatic system in this condition.

We have studied with the capillary permeability test to 99m-Tc labelled albumin, the effect of manual lymph drainage of the upper limb in 10 patients suffering from verified OIO and this without any drug treatment.

The average retention of 99m-Tc labelled albumin prior to drainage is of 13.2 % ± 5 % (norm inferior to 8 %) and after drainage 2.45 % ± 2.4 %.The lymphatic oscillation average is, prior to drainage : 1.68 % ± 0.58 % (norm inferior to 1 %) and after drainage ; 0.66 % ± 0.41 %. The student test is significant at $p < 0.001$.

Furthermore, and in the same patients, the fluorescein uptake in microcapillaryscopy shows after drainage of the lower limbs a clear reduction of the stagnation of the product in the interstitial space and the acceleration of the clearance by the initial lymphatics.

All these results are in favour of a model where DLM, in case of normal lymphatics, acts directly on the desaturation of the lymphatic pomps, thanks to the back flow stimulation. This confirms the TAYLOR's hypothesis on the " peripheral lymph heart " : the hyperfiltration of albumin through little pores in the capillaries can temporary be compensated by the activation of the lymphatic resorption.

Le drainage lymphatique manuel selon la méthode de LEDUC apparaît cliniquement efficace dans l'œdème idiopathique orthostatique (OIO) bien qu'il n'y ait aucune atteinte tronculaire du système lymphatique dans cette affection.

Nous avons étudié à l'aide du test de perméabilité capillaire à l'albumine technétiée, l'effet du drainage lymphatique manuel (DLM)

appreciate their practical interest for treatment orientation.

Twenty-two children (12 boys, 10 girls, average age of 10 years, extremes = 0.5 and 16 years) presenting lymphoedema of the limbs (lower limbs = 17 ; lower and upper limbs : 4, upper limbs : 1) were explored.

20 to 11 MBq of 99m-Tc labelled Rhenium sulfide colloids were subcutaneously injected in the first interdigital space of the extremities. After a dynamic recording of the limb activities (40 × 1 min) immediately after the injection, static images were obtained at 40 min and at 4 h.

In considering the anamnesis, veinous doppler exploration and scintigraphic data, the physiopathological models observed were as follows :

a) hypoplasia or pure aplasia (N = 12) : vessels and / or lymphatic ganglions hypoactive or absent ;
b) lymphoveinous oedema or hypoplasia revealed by an infection or traumatic minor factor (N = 7) : same abnormalities as mentioned above, but with visualisation of greater dermic hyperactivity and of popliteal nodes ;
c) amniotic bridal disease (N = 1) : intense interstitial hyperactivity above the striction.
d) lymphangiectasia : tortuous and dilated lymph vessels.

The visualisation of lymph vessels has constituted a decisive factor for lymphovenous anastomosis (3 cases), and the interstial hyperactivity has provided guidance to manual lymph drainage (7 cases). A malformation of the thoracic canal was suspected by the lymphoscintigraphy and confirmed by the radiological lymphography (1 case).

Finally, a contralateral latent lymphoedema was detected in 9 children. The lymphoscintigraphy can therefore contribute to lymphoedema classification in children and to therapeutic strategy.

Le but de ce travail est d'étudier les anomalies scintigraphiques dans les différents types de lymphœdème primaire de l'enfant et d'en apprécier l'intérêt pratique pour l'orientation du traitement.

Vingt-deux enfants (12 garçons, 10 filles, âges moyen = 10 ans, extrême = 0,5 et 16 ans), présentant un lymphœdème des membres (membres inférieurs : 17, inférieurs et supérieurs : 4, supérieurs : 1) ont été explorés. Le Tc-99m sulfure de rhénium, 20 à 110 MBq, a été injecté par voie sous-cutanée dans le premier espace interdigital des extrémités. Après un enregistrement dynamique de l'activité des membres (40 × 1 min.) aussitôt après l'injection, des images statiques ont été obtenues à 40 min. et à 4 h.

En tenant compte de l'anamnèse, de l'exploration veineuse Doppler et des données scintigraphiques, les modèles physiopathologiques observés étaient les suivants :

a) hypoplasie ou aplasie pure (n = 12) ; vaisseaux et / ou ganglions lymphatiques hypoactifs ou absents ;
b) œdème lymphatico-veineux ou hypoplasie révélée par un facteur mineur traumatique ou infectieux (n = 7) : mêmes anomalies que celles mentionnées ci-dessus avec de plus une hyperactivité dermique et des ganglions poplités ;
c) maladie des brides amniotiques (n = 1) : hyperactivité interstitielle intense en amont de la striction ;
d) lymphangiectasie (n= 2) : vaisseaux lymphatiques tortueux et dilatés.

La visualisation des vaisseaux lymphatiques a constitué un facteur décisif pour l'anastomose lympho-veineuse (3 cas), et l'hyperactivité interstielle a guidé le drainage lymphatique manuel (7 cas). Une malformation du canal thoracique a été suspectée par la lymphoscintigraphie et confirmée par la lymphographie radiologique (1 cas). Enfin, un lymphœdème latent controlatéral a été détecté chez 9 enfants.

La lymphoscintigraphie peut donc contribuer à la classification du lymphœdème de l'enfant et à sa prise en charge thérapeutique.

## LYMPHOSCINTIGRAPHIC EVALUATION OF THE UPPER LIMBS IN VOLLEY-BALL PLAYERS : PRELIMINARY RESULTS ON 8 SUBJECTS

## EVALUATION LYMPHOSCINTIGRAPHIQUE DES MEMBRES SUPÉRIEURS DE JOUEURS DE VOLLEY-BALL : RÉSULTATS PRÉLIMINAIRES SUR 8 SUJETS

R. VOS **, P. BOURGEOIS *, O. LEDUC et A. LEDUC **
* Service de Médecine Nucléaire,
Hôpital Universitaire Saint-Pierre
** Service de Kinésithérapie et de Réadaptation,
Université Libre de Bruxelles,
Bruxelles, Belgique

Functional abnormalities of the lymphatic system have been demonstrated using lymphoscintigraphic techniques in the lower limbs of football players. One of the causes put foreward to explain these abnormalities and their lateralisation was that of repeated shocks. In the same way, this present study was undertaken in order to try to demonstrate that these abnormalities could exist in the upper limbs of volley-ball players too.

Eight male volunteers (average age of 22 years, ranging from 19 to 33) were included in this study. Their practise (P) varied from 2 to 14 years (resp. 2, 3, 4, 5, 7, 8, 9 and 14 years) and their training rythm of 3 to 5 sessions per week. All were right handed except one and also hit with the right hand except one.

Three subjects (P = 7, 8 and 14) had presented different traumatic osteoarticular events in both of the upper limbs (group A). The axillary nodes activity has been measured by scintigraphic techniques (expressed with reference to the injected activity) after a standardized exercice protocol and subcutaneous injection of 0.2 ng × 0.2 ml × 0.5-1.0 mCi of 99m-Tc labelled nanocolloids in the first interdigital space of each hand.

The 3 subjects of group A presented a superior axillary nodes activity (ANA) in both upper limbs compared to that of the other volley-ball players (and to that of a control group of subjects of the same age not practising any sport traumatising the upper limbs).

The other subjects, if they had normal ANA values of their non-hitting arm, also showed an inversion in the ratio of right to left which was even more pronounced in accordance with the number of years of practice.

These results, even though preliminary and based upon a limited number of cases, also suggest the possibility of lymph abnormalities in upper limb as consequence of sport practice.

Des anomalies fonctionnelles du système lymphatique ont été démontrées à l'aide de techniques lymphoscintigraphiques au niveau des membres inférieurs de joueurs de football. Une des causes avancées pour expliquer celles-ci et leur latéralisation reposait dans les chocs répétés. De la même manière, la présente étude fut entreprise pour essayer de démontrer si, au niveau des membres supérieurs (MS), de telles anomalies pouvaient être trouvées comme suite à la pratique du volley-ball.

Huit volontaires de sexe masculin (âge moyen 22 ans, range : 19-33) ont été jusqu'à présent inclus dans cette étude. Leur ancienneté de pratique (AP) variait de 2 à 14 ans (2, 3, 4, 5, 7, 8, 9 et 14 respectivement) et leur rythme d'entraînements (RE) de 3 à 5 séances / semaine. Tous étaient droitiers sauf un et frappaient également de la main droite sauf un. Trois sujets (AP = 7, 8 et 14) avaient présenté différents incidents ostéoarticulaires traumatiques au niveau des deux MS (Groupe A). L'activité ganglionnaire axillaire (AGA) a été mesurée par techniques scintigraphiques (et rapportée à l'activité injectée) après un protocole d'exercices standardisés et injection Sc de 0,2 mg × 0,2 ml × 0,5-1.0mCie de nanocolloïdes technétiés dans le 1er espace interdigital de chaque main.

Les trois sujets du Groupe A présentaient des AGA au niveau des deux MS supérieures à celles des autres joueurs (et à celles d'un groupe témoin de même âge ne pratiquant pas de sport " traumatisant " les MS). Les autres sujets, s'ils avaient au niveau du membre non frappeur des valeurs d'AGA normales, montraient également une inversion du rapport D / G d'autant plus marquée que leur pratique (AP × RE) était plus grande.

Ces résultats, bien que préliminaires et portant sur un nombre limité de cas, suggèrent donc également au niveau des MS la possibilité d'anomalies lymphatiques comme suite à la pratique d'un sport.

the direction of the massage, nearly 80 % of volumetric reduction is obtained when the massage is carried out on the calf rather than at distance.

Lors de la réalisation du drainage lymphatique manuel, il est souvent recommandé d'exercer une légère traction de la peau dans le sens centripète.

Que se produit-il si cette traction très superficielle est réalisée dans le sens inverse ?

A l'aide de la pléthysmographie à jeuge de mercure (JSISU 4), l'effet d'une séance de 16 min est étudié. Une fois, le massage exerce une traction superficielle centripète ; une autre fois, une traction centrifuge. Ces massages sont espacés par un quart d'heure de repos. L'ordre d'exécution est permuté après chaque cas.

Actuellement, cette expérimentation porte sur 9 patients présentant un œdème post-trombotique du membre inférieur. Lors du mode classique, le volume de l'œdème du mollet diminue de 0,86 % ± 0,56. Le résultat est supérieur lorsque la légère traction tissulaire est centrifuge (2,16 % ± 0,94). La différence est significative ($p < 0,05$). L'effet du massage est plus que doublé lors d'une traction centrifuge. Enfin, quel que soit le sens de la manœuvre, près de 80 % de la réduction volumétrique est obtenue lorsque le massage est réalisé au niveau du mollet et non à distance.

## SEMI-RIGID BANDAGES : LYMPHOSCINTIGRAPHIC APPROACH TO THEIR ACTION ON SECONDARY LYMPHOEDEMA OF THE UPPER LIMB

## BANDAGES SEMI-RIGIDES : APPROCHE LYMPHOSCINTIGRAPHIQUE DE LEUR ACTION SUR LE LYMPHŒDÈME SECONDAIRE DU MEMBRE SUPÉRIEUR

J. FERRANDEZ *, D. SERIN **, J.M. VINOT ***
* 2bis, Rue Velouterie, F-84000 Avignon
** Clinique Sainte Catherine, F-84000 Avignon
*** Médecine Nucléaire, CH, F-84000 Avignon

Contention application after manual lymph drainage is recognised as necessary to obtain the best result in lymphoedema reduction.

18 patients treated for a breast cancer by radiosurgical treatment were explored : they all presented a secondary lymphoedema in the upper limb, which was neither due to the disease relapse nor was it linked to a phlebitis of the upper limb.

Their average age is 50.8 years (30 to 80 years).

The surgical types were : 6 tumorectomies, 12 mastectomies. At least 7 axillary lymph nodes were curaged. X-ray treatment was of 45 grays in post-operative.

They underwent a static lymphoscintigraphy realised in 3 clichés :

Cliché L1 : performed 30 min after the injection ;

Cliché L2 : performed after 30 min of manual lymph drainage (MLD) ;

Cliché L3 : performed after 30 min of physical activity under contention consisting of a multiple semi-rigid bandage (Mousse Thuasne N/N* and Flexideal * bandage).

The comparison between cliché L3 and L2 allows to demonstrate the effect of the contentions on the return of lymph previously stimulated by the MLD. This sequence corresponds to the physiotherapy chronology.

Notably, the different progression heights obtained (forearm, arm, ganglions) and the pathways of the colloids (lymph collectors, interstitial space, peri- and extra-vascular space) are analysed.

In definite, the action of physical activity under contention proves to be particularly efficient on the lymph return by the interstitial sector.

La mise en place d'une contention après drainage lymphatique manuel (DLM) est reconnue comme nécessaire pour l'obtention de la meilleure réduction d'un lymphœdème.

18 patientes traitées pour un cancer du sein par un traitement radiochirurgical sont explorées. Elles présentent toutes un lymphœdème secondaire du membre supérieur qui n'est ni le fait d'une récidive de la maladie, ni lié à une phlébite du membre supérieur.

Leur âge moyen est de 50,8 ans (30 à 80 ans). Les types chirurgicaux sont 6 tumorectomies pour 12 mastectomies. Le curage a toujours amené au moins 7 ganglions. La radiothérapie a été de 45 grays en post-opératoire.

Elles bénéficient d'une lymphoscintigraphie statique réalisée en 3 clichés :

Cliché L1 : réalisé 30 min après l'injection ;

Cliché L2 : réalisé après 30 min de DLM ;

Cliché L3 : réalisé après 30 min d'activité physique sous contention par mise en place d'un bandage multicouches semi-rigide (Mousse Thuasne N/N* et bandes Flexidéal *).

La comparaison des clichés L3 par rapport à L2 permet de mettre en évidence l'action des contentions sur le retour lymphatique préalablement stimulé par le DLM. Cette séquence correspond à la chronologie de la physiothérapie.

Notamment, sont analysées les différentes hauteurs de progression obtenues (avant-bras, bras, ganglions), et les voies de cheminement du colloïde (collecteurs lymphatiques, espace interstitiel, espace péri- et extra-vasculaire).

En définitive, l'action de l'activité physique sous contention s'avère particulièrement efficace sur le retour lymphatique par le secteur intersticiel.

## PRIMARY LEG LYMPHEDEMA IN ADULTS TREATED WITH MANUAL LYMPH DRAINAGE AND COMPRESSION THERAPY

HUTZSCHENREUTER P. *, KURZ L. **, ZIMMERMAN G. **
* Research Institute of Lymphology, Ulm (Germany)
** Privat Hospital of Dr. Vodder School, Walchsee (Austria)

In a retrospective study, leg volume reductions (LVR) were analysed in 35 patients with bilateral primary lymphedema and in 17 patients with unilateral primary lymphedema. All patients had 2nd and 3rd degree leg lymphedemas and were treated twice per day for one hour with manual lymph drainage (MLD), 5 days per week, for a 3 weeks period. Bandage compressions (BC) were used between each MLD sessions. Before MLD and BC treatments began, and at the end of every week, leg volume were calculated by KUHNKE's method (1976). Results : the leg volume decreased from 11 665 ml + 2 888 ml to 10 351 ml + 2 845 ml in affected legs, and from 8 412 ml ± 1 637 ml to 8 088 ml ± 1 507 ml in healthy legs in patients with unilateral primary lymphedema during the 3 week treatment period. Leg volume decreased from 10 762 ml ± 2 886 ml to 9 757 ml ± 2 339 ml in the right affected leg, and decreased from 10 116 ml ± 3 280 ml to 9 298 ml ± 2 937 ml in the left afflicted leg in patients with bilateral lymphedema. All these LVR's were in both groups high significant with a probability of < 1 % as shown by the WILCOXON matched pairs test. LVR's caused by MLD and by BC effects and will be discussed in this paper.

## RELIABILITY OF A VOLUME MEASURING DEVICE (Volometer ®) FOR HUMAN LIMBS

O. LEDUC, P. KLEIN, P. DEMARET and C. RASQUIN
Department of physical Therapy and Rehabilitation
(Prof. A. Leduc), Université Libre de Bruxelles

EXPERIMENTAL DESIGN

1. Comparison with a well-defined volume.
2. Comparison with the volume of a human autopsy specimen (forearm).
3. Influence of the rotation on the measurement of the autopsy specimen.
4. Influence of the rotation on the measurements in vivo.
5. Influence of the elbow flexion on the measurements in vivo.

RESULTS

1. A well defined homogeneous cylinder (2011 ml) was used. The measured volume with the " Volometer ®" was 1987 ml ± 4.3 ml. The error was thus 1.2 %.

thermia represents an alternative to microwave therapy. Whereas microwave hyperthermia has been used successfully in these situations, certain limitations exist. Our method of treatment consists of producing hot and humid ambient inside the chamber where the limb is situated. Hyperthermia was performed in 64 patients, with postlymphangitis chronic lymphedema, who underwent microsurgical lympho-venous or lymphatic-venous-lymphatic shunt operations, 3 - 6 months after the end of hyperthermic treatment. All patients were followed up to 3 years. A remarkable improvement of lymph flow was assessed using isotope lymphography and edema improved in all patients.

## LYMPHATIC TRANSPLANT
## TRANSFERTS LYMPHATIQUES

BECKER C., HIDDEN G., BOURGEOIS P.

The authors have performed 120 lymphatic transfers for lymphoedema resisting to physical treatment. The intervention consists of a free transfer of a couple of lymph nodes contained in fat with arterial and venous anastomosis. A lymphatic neovascularisation appears within 24 hours and the arterio-venous anastomosis allows the vascularisation of the lymphatics and plexial circulation of the lymph nodes. We shall show you a few different cases of lymphoedema resisting to all physical treatment in the upper and lower limbs, the obtained results, the complementary results of physical treatment applied post-operatively and the reasons of failed cases.

The discussion concentrates on the eventuality of using complementary treatments, either surgical or physical, in order to improve the state of these patients.

Les auteurs ont décrit 120 transferts lymphatiques pour lymphœdèmes résistant au traitement physique.

L'intervention consiste en un transfert libre de quelques ganglions contenus dans la graisse avec anastomose artérielle et veineuse. Une néovascularisation lymphatique se fait dans les 24 heures et les anastomoses artério-veineuses permettent la vascularisation des lymphatiques et la circulation plexielle au niveau des nodules lymphatiques. Nous vous montrons quelques cas différents de lymphœdèmes résistant à tout traitement physique au niveau du membre supérieur et membre inférieur, les résultats que nous avons obtenus, les compléments des résultats physiques qui fonctionnent en post-opératoire, et les raisons des cas d'échecs.

La discussion s'ouvre sur l'éventualité de traitements complémentaires, soit chirurgicaux, soit physiques, de manière à améliorer ces patients.

## PRESENT ROLE OF MICROSURGERY IN LYMPHEDEMA TREATMENT

C. CAMPISI, F. BOCCARDO, M. TACCHELLA,C.M. CAMPISI

The authors report their experience in managing 709 patients with chronic peripheral lymphedema undergoing microsurgical operative techniques. An accurate preoperative diagnostic evaluation is indispensable to select the patients according to indications of the various microsurgical methods. The operation was commonly performed under general anesthesia. Operative microscope was always used both to isolate lymphatic collectors and to perform anastomoses. The authors point out indications to derivative operations of lymphovenous shunts and those to reconstructive techniques with particular reference to the personal method of lymphatic-venous-lymphatic interpositioned shunt (LVLA). The follow-up at over 5 years after operation showed positive results in over 80 % of patients.

## RATIONAL APPROACH OF PERIPHERAL LYMPHOSTATIC DISEASES : 20 YEAR CLINICAL EXPERIENCE

C. CAMPISI, F. BOCCARDO, M. TACCHELLA,
C.M. CAMPISI
University of Genoa - Dep. of General and Emergency Surgery
Microsurgical Center - Osp. San Martino - Italy

The authors report their clinical experience (1973-1993) in the diagnostic evaluation and management plan of patients with peripheral lymphostatic disorders, underlining the complexity and variable clinical presentations of these diseases.

Based on their lengthy experience with an ongoing registry they have tried to outline a protocol for studying, " staging " and managing lymphedema, including the role of microsurgical lymphatic angioplastic shunts.

The precociousness of microsurgical operation, if indicated, is indispensable to obtain permanent remarkable edema regression.

## A PROTOCOL FOR STUDYING AND MANAGING LYMPHEDEMA

C. CAMPISI, F. BOCCARDO, M. TACCHELLA,
C.M. CAMPISI
University of Genoa
Department of General and Emergency Surgery
Microsurgical Center
Ospedal San-Martino - Italy

The authors report their experience in managing patients with chronic arm or leg persistent lymphedema. The initial approach to these patients includes appropriate drugs, manual lymph drainage, pneumatic compression, external compression stockinettes. In patients, however, with longstanding obstructive lymphedema unresponsive to " conservative " methods and in whom there are demonstrable patent regional lymphatics and suitable lymph nodes, microsurgical shunts and plastic reconstruction in the management of peripheral lymphedema are feasible. These operations, however, can yield successful results only thanks to a careful diagnostic preoperative evaluation, which is indispensable, as the authors point out, to establish the precise indications to the various microsurgical operations used in different clinical situations.

## VARIATIONS OF MICROSURGICAL LYMPHVESSEL TRANSPLANTATION

R.G.H. BAUMEISTER
Micro-, Hand-, Reconstructive Surgery,
Department of Surgery, Klinikum Grobhadern
University of Munich

Lymphvessel transplantation originally was designed to bridge blocked lymphatic pathways at the roots of the extremities.

In the meantime there have been performed several variations with the aid of lymphatic grafts or with transposed lymphatic vessels in order to treat localised lymphoedemas.

Local peripheral blockade :
they are bridged by short lymphatic grafts.

Selected blockade of the superficial inguinal lymphnodes :
transposition of the superficial lymphatics to the deep system with lympholymphatic anastomoses.

Œdemas of penis and scrotum :
Transposition of lymphatics of the thigh to the scrotal area with lympholymphatic anastomoses.

The technical variations are presented in detail.

## WOBENZYM THERAPY OF ONCOLOGICAL PATIENTS WITH LYMPHEDEMAS

M. BECHYNE *, J. TOMANOVA *, R. BECHYNOVA **
* Dermatologic Clinic IMF and MF UK, Praha
** Dermatoverenologic Clinic, Plzen
Lymfocentrum Praha 6

After surgical treatment of the cancer patients no - and chemotherapy frequency of secondary lymphedema very uncertain. The patient's claims cannot be ignored if changes are not clinically detectable by measurement. Post-mastectomy patients, without apparent lymphedema decreased lymphatic and transport capacity in lymph and transport capacity in lymphoscintigraphic study. The patients