

THORACIC DUCT LYMPH TRIBUTARIES FROM RENAL ORIGIN

RIQUET M., ASSOUAD J., MORDANT P., HIDDEN G., DELMAS V.

Service de Chirurgie Thoracique, Hôpital Européen Georges Pompidou, Paris – France.
Institut d'Anatomie – Biomédicale des Saints-Pères, Paris – France

Corresponding author: Professeur Marc RIQUET, Service de Chirurgie Thoracique,
Hôpital Européen Georges Pompidou, 20 rue Leblanc 75015 Paris, France
Tel.: 33 1 56 09 34 50
Fax: 33 1 56 09 33 80
e-mail : marc.riquet@egp.aphp.fr

ABSTRACT

The thoracic duct originates from one intestinal and two lumbar trunks. The latter are deemed to carry lymph from the kidneys. The anatomical studies on the renal lymph drainage generally describe lymph nodes and lymph centres, but are not indicative on the lymph flow ultimate destination. Our purpose was to focus on the course of the lymph vessels from renal origin until their end. The study was performed on adult cadavers. Both kidneys were injected with a blue modified Gerota mass, resulting in 26 successful preparations. The injected lymph vessels were dissected until their termination to reach the blood circulation.

The injection failed in 3 right kidneys and was complete in 13, from which posterior lymph vessels connecting to the thoracic duct were always demonstrated, after crossing lymph nodes in 8 cases and directly in the other cases. The injection also failed in 3 left kidneys and was incomplete in 4; from the completely injected left kidneys, lymphatics connecting to the thoracic duct were demonstrated in the same manner, 3 of them directly joining the duct without crossing any lymph node.

To conclude, the renal lymph vessels reach more or less distant retrocaval and paraaortic lymph nodes as classically described, but also constantly and massively the thoracic duct at its origin. They apparently play a preponderant role in contributing to its formation.

Key words: Thoracic duct, kidney, lymphatics, lymph node.

INTRODUCTION

The thoracic duct (TD) originates from one intestinal and two lumbar trunks^[1-3]. The latter are deemed to carry the lymph from the kidneys, but the anatomical studies on the lymph vessels (LV) of the kidneys generally focus on the lymph nodes (LN) located in the retrocaval and paraaortic areas with whom they connect^[4,5], and are not indicative on their further termination. Our purpose was to revisit the renal lymph drainage and to more particularly investigate the course of the lymph tributaries from renal origin.

MATERIAL AND METHODS

The study was conducted in the Laboratory of Anatomy of the Paris Descartes University, in Paris. We selected fresh adult cadavers free from chest and intra-abdominal pathology and not yet embalmed. We performed a sternolaparotomy on the subject placed in supine position, and removed the heart, liver, stomach, spleen, and intestine from the first jejunal loop to the sigmoid. The corpse being cold preserved, we re-warmed the remaining organs with water at 50°C before continuing the procedure. Both kidneys were then injected by means of pedal lymphography needle and catheter, with a 1 to 2 ml aliquot of a blue modified Gerota mass, one injection at the upper and one at the lower part of the kidney on each side. We obtained 26 successful preparations. The injected LVs were dissected from the kidneys their course was followed until their termination.

RESULTS

From the injected right kidneys, the preparation proved successful and complete in 13. Anterior LVs reaching interaortocaval right sided and also more distant located LN (aorta bifurcation and left lateroaortic aspect) were observed as commonly described. Posterior LVs were also demonstrated in all cases: they always connected to the TD at his origin, after some of them crossing lymph nodes on their course in 8 cases and directly without LN interposition in 5. From the left kidneys, the preparation proved successful in 13 and complete in 9. Anterior LVs reaching left lateroaortic LNs but also celiac and iliac LNs were observed in incompletely and completely injected cases. Posterior LVs connecting to the TD, 3 of them directly without crossing any LN, were also demonstrated when the preparation was completely injected. When considering each cadaver, the injection was complete and bilateral in 7. In these cases the right and left renal LVs joined to apparently form the origin of the thoracic duct (figure 1, 2 and 3). The LVs were generally running upwards

along the posterior aspect of the thoracic aorta between both diaphragmatic crura before fusing into the TD at a various level of the lowest part of the posterior mediastinum.

COMMENTS

There is no anatomical study dealing with the renal lymph drainage pattern demonstrating the issue of the LVs and their way to reach the blood circulation. We observed that this way was obviously represented by the TD. Other studies reporting LVs connecting to the TD are very rare: Cunéo^[6] mentioned without describing them that LVs connected to the TD from paraaortic LNs after crossing behind the diaphragmatic crura along the sympathetic nerve, which Delmas et al.^[5] also observed once after a left kidney injection. As these authors, we also occasionally observed some retrocrual pathways, but there were inconsistent, occurred at any level, and were not associated with the sympathetic nerves; however, this may indicate that several auxiliary lymph drainages may connect to the TD. Kuznetsov^[7] has observed in a dog an enlarged LV getting lymph from the left kidney and running into the initial part of the TD without encountering any LN. We also observed LVs directly joining the TD without traversing any LN, but this was the case with a surprisingly very high frequency in human and gave the impression that the LVs issuing from the kidneys were forming the TD itself (figure 1-3).

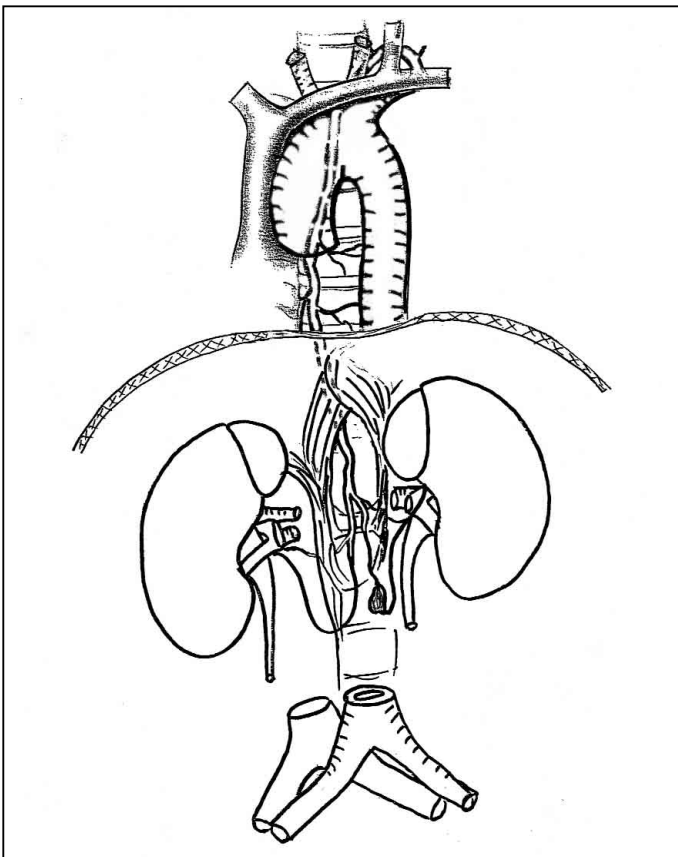


Fig. 1 - Schema of the lymph vessels running out of the kidneys and joining together into the beginning of the thoracic duct.

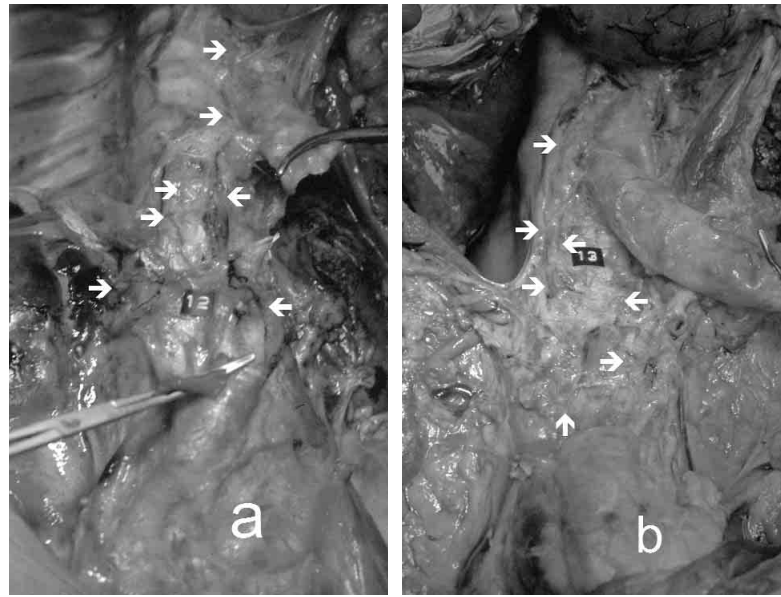


Fig. 2 a & b- Two preparations demonstrating renal lymph vessels running into the origin of the thoracic duct (indicated by arrows).

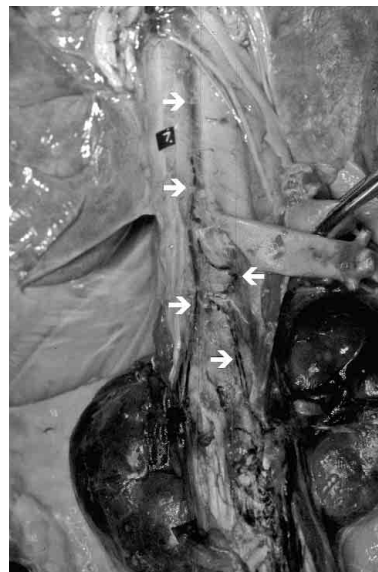


Fig. 3 - Preparation in which the renal lymph vessel origin of the thoracic duct is still appearing more obviously.

When revisiting physiology, this possibility that the TD originates from the renal lymph draining vessels is worth consideration. Although the kidneys are small organs, they receive 20% of the cardiac output^[8]. Most of this blood flow is concerned with the filtration of the plasma and the subsequent concentration of the filtrate to form urine, but plasma is also filtrating into the renal parenchyma, as may be observed in any other organ, and gives birth to the renal lymph. This lymph drainage may play an important role in renal function: this is illustrated by ligating the renal LVs in dogs, which results in decreasing the clearances of urea and creatinine while increasing the urinary volume and protein excretion^[9]. Also, when the renal LVs are not or incompletely ligated as it may be the case when harvesting a renal graft, the lymph flow escaping from the graft may play a major

role in the occurrence of post renal transplantation lymphoceles^[10], and the lymphatic neoangiogenesis that follows the LVs interruption may favour the maintenance of a potentially detrimental alloreactive immune response in renal transplants^[11]. In fact, the role and importance of the renal lymph drainage is underrated, the research not very developed, and our knowledge still dismal on this topic. This appears obviously when simply researching data concerning the amount of this lymph drainage: the renal lymph output volume is overlooked and generally not mentioned in currently available nephrology literature. However, by using standard intra-organ lymph production calculation (Starling's law)^[3], it may be estimated to amount from about 0.6 to 9 litres each day. This represents an important volume to be returned to the blood circulation that requires efficient lymph draining vessels, also supporting that the renal LVs may form the TD origin.

CONCLUSION

Renal lymph drainage reaches para-aortic and distant LNs, which it is classically described, but also constantly and massively the TD, which is frequently occurring without LVs crossing any LN. The kidney being a highly important centre of blood flow, this lymph drainage pattern suggests that renal LVs may play an important role in TD formation and origin.

REFERENCES

1. Rouvière H.: *Anatomie des lymphatiques de l'homme*. Masson Ed, Paris, 1932; (486 pages).
2. *Gray's Anatomy*. Editor in chief Standring S. 39th Ed. Elsevier Churchill Livingstone, Edinburgh, 2005; (1627 pages).
3. Földi M., Földi E.: *Földi's Textbook of Lymphology*. Elsevier GmbH, Munich, 2nd Ed. 2006; (735 pages).
4. Nicolesco J.: *Sur les lymphatiques du rein*. Ann. Anat. Pathol., 1930; 7: 503-508.
5. Delmas V., Hidden G., Dauge M.C.: *Remarques sur les lymphatiques du rein: le premier relai nodal*. Bull. Soc. Anat., Paris 1989; 13: 105-109.
6. Cunéo B.: *Note sur les ganglions lymphatiques régionaux du rein*. Bull. Mem. Soc. Anat., Paris 1902; 75: 235-236.
7. Kuznetsov A.: *Extraorganic lymphatic vessels and regional lymph nodes in the dog kidney*. J. Arch. Anat. Histol. Embryol., 1987; 93: 37-39.
8. Vogel S.: *Vital circuits - on pumps, pipes, and the workings of circulatory systems*. Oxford University Press, New York-Oxford, 1992.
9. Threefoot S.A.: *Influence of obstructed renal lymph flow on effects of a nephrotoxin on renal function*. Lymphology, 1993; 26: 186-194.
10. Sansalone C.V., Aseni P., Minetti E., Di Benedetto F., Rossetti O., Manoochchri F., Vertemati M., Giacomoni A., Civati G., Forti D.: *Is lymphocele in renal transplantation an avoidable complication?* Am. J. Surg., 2000; 179: 182-185.
11. Kerjaschki D., Regele H.M., Moosberger I., Nagy-Bojarski K., Watschinger B., Soleiman A., Birner P., Krieger S., Hovorka A., Silberhumer G., Laakkonen P., Petrova T., Langer B., Raab I.: *Lymphatic neoangiogenesis in human kidney transplants is associated with immunologically active lymphocytic infiltrates*. J. Am. Soc. Nephrol., 2004; 15: 603-612.